

An uncommon localization of a giant hydatid cyst presenting with cardiac tamponade

Kalp tamponadı ile ortaya çıkan nadir yerleşimli dev kist hidatik

İrfan Şahin, M.D., Berk Özkaynak, M.D.,# Burak Ayça, M.D., Ertuğrul Okuyan, M.D.

Department of Cardiology, Bağcılar Training and Research Hospital, Istanbul;

#Department of Cardiovascular Surgery, Bağcılar Training and Research Hospital, Istanbul

Summary– Cardiac involvement in hydatid cyst disease is a rare manifestation and may remain asymptomatic for years. The location of the cyst determines the presentation. In this report, we present a case of hydatid cyst presenting with massive pericardial effusion, right ventricle compression leading to cardiac tamponade. The diagnosis was established with transthoracic, transesophageal echocardiography and computed tomography.

Özet– Kist hidatiğin kalp tutulumu nadir görülmektedir ve uzun yıllar semptomsuz kalmaktadır. Bulunduğu bölgeye bağlı olarak şikayete neden olur. Bu yazıda, yoğun perikart sıvısı ile birlikte sağ ventriküle bası yaparak tamponada neden olan dev kist hidatikli bir olguyu sunduk. Tanı transtoraksik-transözofajiyal ekokardiyografi ve bilgisayarlı tomografi ile konuldu.

Infection of the heart with *Echinococcus granulosus* is a rare disease, but may cause mortality especially if going undiagnosed and becoming complicated. The most frequent location of a hydatid cyst is the interventricular septum (IVS) and left ventricular free wall. Pericardial and paracardial sites of implantation are less common. The location of the cyst may result in different clinical scenarios varying from arrhythmias and left ventricular outflow tract obstruction to pericardial effusion/cardiac tamponade.

Here, we report a case of hydatid cyst with an atypical location and presenting with cardiac tamponade.

CASE REPORT

A 31-year-old female was referred to our clinic with complaints of dyspnea, peripheral limb edema, dull chest pain and palpitations. On initial physical examination, the patient was subfebrile (body temperature 37.1°C). Blood pressure was 90/55 mmHg and pulse was 115 beats/min and regular. Cardiac auscultation revealed a 2/6 systolic murmur maximally heard at

the base of the heart. Auscultation of the chest revealed no abnormalities. Abdominal examination revealed mild hepatomegaly without splenic enlargement. An electrocardiogram revealed sinus rhythm and low voltage. A chest radiogram showed increased cardiothoracic ratio and the lung fields were normal. The patient's white blood count was increased ($13.3 \times 10^9 /L$, 3% eosinophils). Transthoracic echocardiography revealed a large mass compressing the right ventricle with massive pericardial effusion (Figure 1a; Video 1*, and Figure 1b; Video 2*). Thoraco-abdominal computed tomography (CT) imaging revealed a cyst (5.5 cm x 4.9 cm) with apparent septa in the lower border of the right ventricle, and massive pericardial effusion measuring 6.5 cm on the anterior surface of the right ventricle (Figures 1c, d). Lungs and liver were unaffected by the disease. A hemagglutination immunoreaction test for echinococcosis was positive.

Open heart surgery was performed with standard cardiopulmonary bypass and mild hypothermia. The

Abbreviation:

IVS Interventricular septum

Received: October 15, 2014 Accepted: November 21, 2014

Correspondence: Dr. İrfan Şahin, Bağcılar Eğitim ve Araştırma Hastanesi, Kardiyoloji Kliniği, İstanbul, Turkey.

Tel: +90 212 - 440 40 00 e-mail: medirfansahin@gmail.com

© 2015 Turkish Society of Cardiology



cyst was sterilized by injection of 20% hypertonic saline solution, and the cystic material was aspirated and then removed. Histopathologic examination confirmed the clinical and surgical diagnosis of a hydatid cyst. The early postoperative period was uneventful. The patient was put on albendazole treatment and discharged uneventfully. No recurrence of the disease was detected at a one-year follow-up.

DISCUSSION

Cystic echinococcosis is caused by the larva of tapeworm *Echinococcus granulosus*. Cardiac involvement is infrequent; it occurs in 0.2 to 2% of patients with echinococcal disease, is caused by invasion of the myocardium via the coronary arteries.^[1] When cardiac involvement is present in echinococcal disease, the cysts are usually located in the left ventricle

(20-52%), the IVS (10-42%), and the right ventricle (10-31%) and less frequently in the atria, the pericardium, and the pulmonary artery.^[2]

Echinococcosis of the human cardiovascular system may result in a wide variety of clinical and pathological manifestations, although the majority of patients with cardiac echinococcosis are initially asymptomatic. The most dangerous and potentially lethal complication of the cysts is their intracardiac or intrapericardial rupture, which may result in anaphylactic shock, embolization, or cardiac tamponade, acute pericarditis, and chronic constrictive pericarditis.^[3] Early recognition and treatment of cardiac echinococcosis is important, as the risk of cyst rupture is high.^[4]

Echocardiography is often the first, and frequently the only required imaging modality to establish diag-

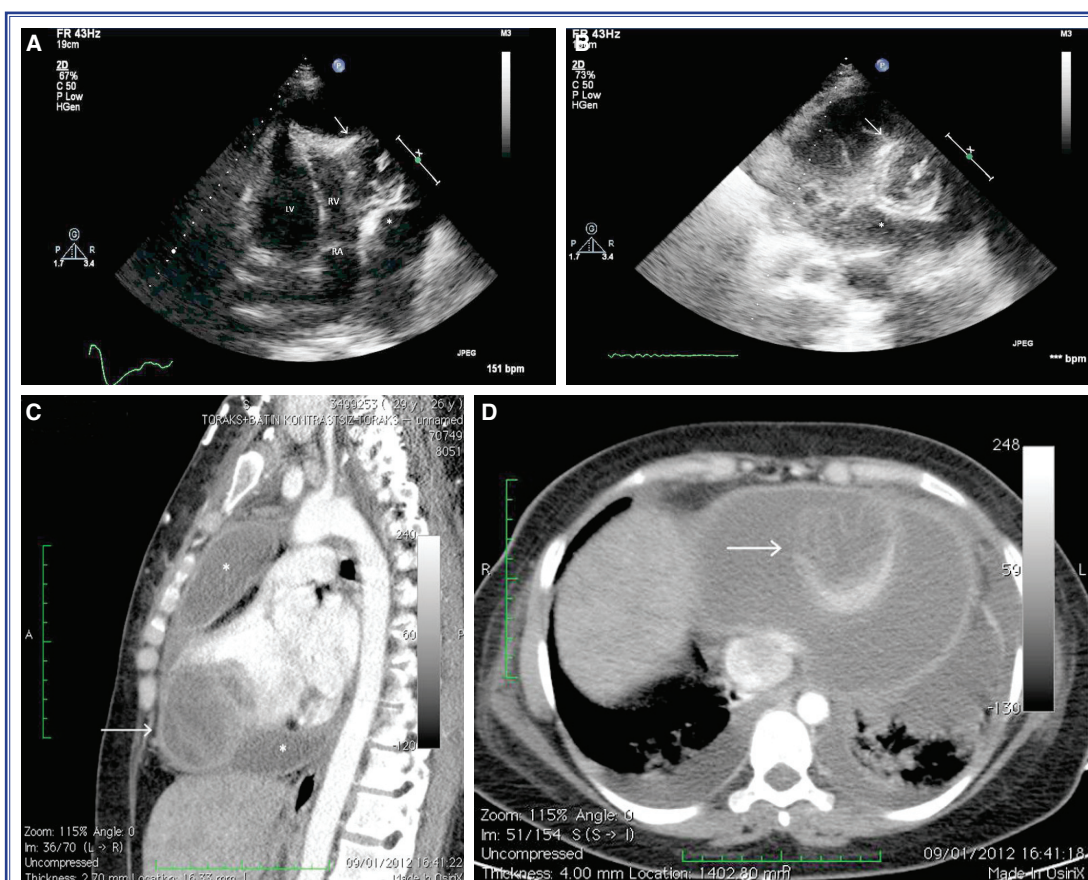


Figure 1. (A) Apical 4 chamber echocardiographic view of the patient. Arrow points to the hydatid cyst neighboring the right ventricle. * shows massive pericardial effusion. LA: Left atrium; LV: Left ventricle; RA: Right atrium; RV: Right ventricle. (B) Parasternal short-axis basal view shows hydatid cyst with germinative membrane (arrow) and pericardial effusion (*). (C) Sagittal CT view showing presentation of hydatid cyst (arrow) in relation to lower right ventricular border and pericardial effusion (*). (D) Hydatid cyst with germinative membrane (arrow) in axial CT section.

nosis. Cases described outline the common pattern of echocardiographic appearance of hydatid cysts. Thus, the cysts are usually single, they range from 3-5 cm in diameter, they are spheroidal in shape and have well-defined edges; they are echolucent and often contain internal septa corresponding to daughter cysts; and finally, they are usually located intramyocardially and protrude into one or both ventricular chambers.^[5] In our case, the symptoms resulted from compression of the cyst and the accompanying pericardial effusion.

Surgical intervention is the only definitive treatment and the results are satisfactory. Post-operative albendazole or mebendazole should be prescribed as an adjuvant therapy to prevent recurrence of the disease.

Although hydatid cardiac cysts are rare in clinical practice, they may go unrecognised for a long period. Combined surgery and albendazole is satisfactory therapy.

Conflict-of-interest issues regarding the authorship or article: None declared.

***Supplementary video files associated with this article can be found in the online version of the journal.**

REFERENCES

1. McManus DP, Zhang W, Li J, Bartley PB. Echinococcosis. Lancet 2003;362:1295-304. [CrossRef](#)
2. Bashour TT, Alali AR, Mason DT, Saalouke M. Echinococcosis of the heart: clinical and echocardiographic features in 19 patients. Am Heart J 1996;132:1028-30. [CrossRef](#)
3. Di Bello R, Menendez H. Intracardiac rupture of hydatid cysts of the heart. A study based on three personal observations and 101 cases in the world literature. Circulation 1963;27:366-74.
4. Maffei GR, Petrucci O, Carandina R, Leme CA Jr, Truffa M, Vieira R, et al. Cardiac echinococcosis. Circulation 2000;101:1352-4. [CrossRef](#)
5. Rey M, Alfonso F, Torrecilla EG, McKenna WJ, Balaguer J, Alvarez L, et al. Diagnostic value of two-dimensional echocardiography in cardiac hydatid disease. Eur Heart J 1991;12:1300-7. [CrossRef](#)

Key words: Echinococcosis/diagnosis; echocardiography; cardiac tamponade; pericardial effusion.

Anahtar sözcükler: Ekinokok/tanı; ekokardiyografi; kalp tamponadı; perikart efüzyonu.