

Management of an iatrogenic radial artery perforation: a case report

İyatrojenik radyal arter perforasyonu tedavisi: Olgu sunumu

Ali Buturak, M.D., Yasemin Demirci, M.D., Sinan Dağdelen, M.D.

Department of Cardiology, Acıbadem University Faculty of Medicine, Istanbul

Summary—A 73-year-old female patient underwent transradial coronary angiography with stable angina and signs of significant myocardial ischemia revealed by exercise stress test. After insertion of a 6F radial sheath into the right radial artery and intra-arterial administration of heparin plus verapamil, the hydrophilic guidewire could not be advanced under fluoroscopic guidance. Immediately afterwards, radial angiography was performed, which displayed a radial artery perforation with significant contrast extravasation. The perforated segment was crossed meticulously with the same guidewire after additional vasodilator drug administration. Afterwards, a 5F TIG catheter was advanced to the axillary artery and held in place for 20 minutes with application of external compression with a sphygmomanometer cuff at the level of systolic blood pressure. The same maneuver was again performed following cuff deflation and completion of coronary angiography with the 5F catheter. Final angiography displayed complete sealing of the perforation without a need for neutralization of heparin. External compression was continued for two hours, and after documentation of normal triphasic radial artery flow by Doppler ultrasound (DUS), the radial sheath was removed. The patient was discharged the following day with no evidence of hand ischemia and well-palpable radial artery pulse. DUS demonstrated normal radial artery flow one month later. This unusual complication was managed successfully with a simple and easily applicable technique that can be performed in such cases.

Since its introduction by Kiminji in 1989, the transradial approach has gained widespread acceptance as an alternative to femoral access for coronary diagnostic and interventional procedures because of decreased vascular complications.^[1-3] Radial artery perforation is a rare complication of radial interventions, which

Abbreviations:

RRA Right radial artery
LAD Left anterior descending

Özet— Kararlı anjina pektoris ve egzersiz stres testi ile ortaya çıkarılan ciddi miyokart iskemisi bulguları olan 73 yaşındaki kadın hastaya radyal arter yoluyla koroner anjiyografi yapıldı. Sağ radyal artere, 6F radyal kılıf yerleştirilip heparin+verapamil intraarteriyel olarak verildikten sonra, hidrofilik kılavuz tel floroskopi altında ilerletilemedi. Hemen sonra yapılan radyal anjiyografi ile damar dışına ciddi kontrast sızıntısı gösteren radyal arter perforasyonu saptandı. İlave damar genişletici (vazodilatör) ilaç verilmesinin ardından aynı hidrofilik kılavuz tel özenle kullanılarak delinmiş segment geçildi. Ardından, 5F TIG kateter, aksiller artere kadar ilerletildi ve 20 dakika süreyle sistolik kan basıncı düzeyinde basıncı sabitlenmiş sfigmomanometre manşonu ile ön kola dış bası uygulandı. Manşon söndürülüp, 5F TIG kateter ile koroner anjiyografi tamamlandıktan sonra aynı manevra tekrar uygulandı. Son anjiyografi ile heparin nötralizasyonuna gerek kalmaksızın perforasyonun tamamen kapanmış olduğu görüldü. Dış kompresyona iki saat daha devam edildi, Doppler ultrasonografi (DUS) ile normal trifazik radyal arter akımı gösterildikten sonra radyal kılıf çıkarıldı. Hasta, ertesi gün elinde iskemi bulgusu olmadan ve elle muayenede çok iyi hissedilen radyal arter nabızı ile taburcu edildi. Birinci ay kontrolünde yapılan DUS ile normal radyal arter akımı izlendi. Bu nadir görülen komplikasyon, benzer olgularda da kolay uygulanabilecek basit bir teknik ile başarılı olarak tedavi edildi.

may cause acute hand ischemia and compartment syndrome if left untreated.^[4]

CASE REPORT

A 73-year-old Turkish female patient with known history of hypertension and hyperlipidemia presented with fatigue and effort induced chest pain for six

Received: June 16, 2012 Accepted: August 31, 2012

Correspondence: Dr. Ali Buturak, Acıbadem Kadıköy Hastanesi, Tekin Sokak, No: 8, Kadıköy, 34720 İstanbul, Turkey.

Tel: +90 216 - 544 43 20 e-mail: alibuturak@yahoo.com

© 2013 Turkish Society of Cardiology



months. She was an ex-smoker with a history of 80 packs year. Echocardiography showed left ventricular concentric hypertrophy with grade 1 left ventricular diastolic dysfunction. Treadmill stress testing revealed significant myocardial ischemia with 2 mm downslope ST depressions in the inferolateral leads. Elective coronary angiography was performed through a right radial artery (RRA) approach. A 6F radial sheath (Radifocus introducer II, Terumo) was inserted in the RRA and 5000 Units of unfractionated heparin along with 2.5 mg verapamil were given through the sheath. Then, the standard (0.035 inch) 260-cm guidewire (Radifocus Guidewire M) could not be advanced under fluoroscopic guidance due to a significant resistance felt in the forearm. After removal of the guidewire, a RRA angiography was done which displayed a radial artery perforation with significant contrast extravasation (Figure 1a). Immediately afterwards, the patient complained of right forearm pain and moderate forearm swelling was observed. We meticulously crossed the perforated segment with the same guidewire after intra-arterial administration of 100 µg of nitroglycerine and 2.5 mg verapamil. Then, a 5F TIG catheter (Terumo Optitorque Radial TIG II 4.0) was advanced up to the axillary artery over the wire. The catheter was held in place for 20 minutes with external compression applied by a sphygmoma-

nometer cuff at the level of systolic blood pressure (150 mmHg). No protamine sulfate was administered to neutralize heparin. Diagnostic coronary angiography was completed by advancing the 5F TIG catheter which revealed a critical, hazy, and eccentric 98% stenosis in the mid-portion of the well-developed left anterior descending artery (LAD). Then, the TIG catheter was pulled back at the level of the axillary artery and held in place for 20 minutes more with external compression by a sphygmomanometer located slightly above the bleeding site. Subsequently, the catheter was removed and the RRA angiography was performed providing evidence of a complete sealing of the perforation (Figure 1b). Afterwards, we decided to revascularize the LAD lesion because of the angiographic high risk characteristics. Following oral administration of 600 mg clopidogrel and 300 mg aspirin, the left main coronary artery was engaged with a 6F JL 3.5 guiding catheter advanced by right femoral access. The lesion was stented successfully with a 3.0 /18 mm Xience V stent (Abbott Vascular) at 16 atmospheres (atm) after predilatation by a 2.5 /15 mm semi-compliant Sprinter balloon (Medtronic) at 8 atm. During the transfemoral procedure, the radial sheath was kept in place while the external compression with the sphygmomanometer cuff at 75 mmHg was applied to the forearm. A final RRA angiography was

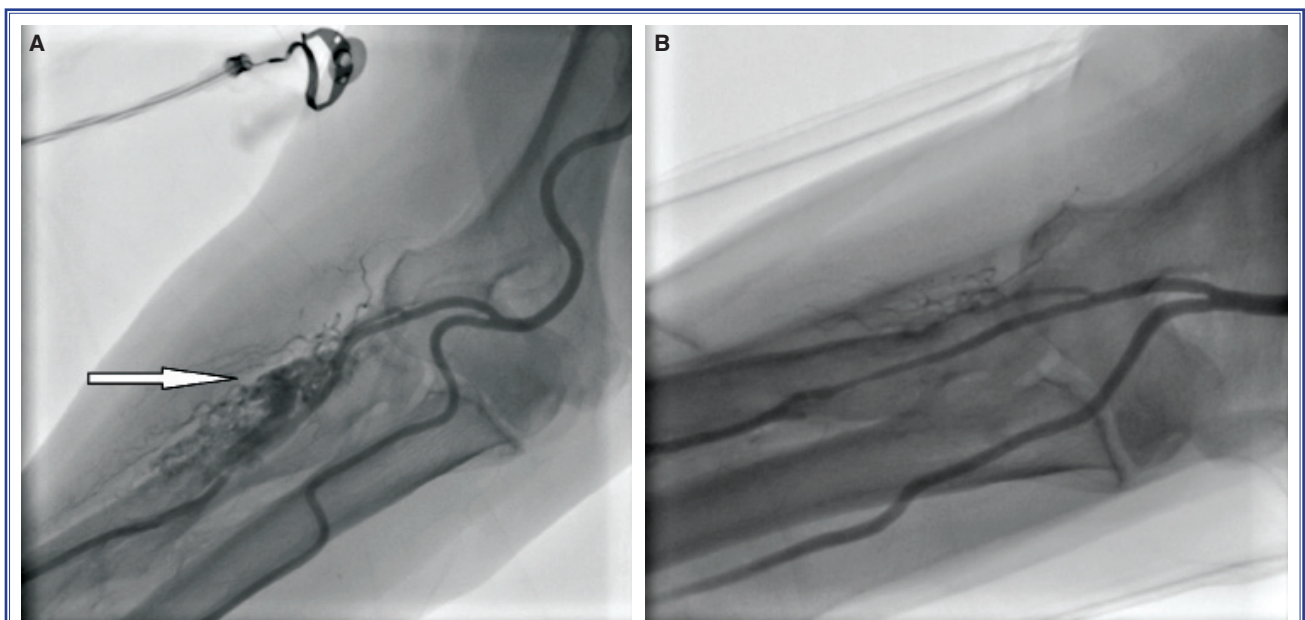


Figure 1. (A) Iatrogenic radial artery perforation complicating diagnostic coronary angiography: White arrow indicating guidewire induced right radial artery perforation with massive contrast extravasation. (B) Final radial angiography displaying complete sealing of the perforation.

performed and complete sealing of the perforation was displayed once more. External compression was continued for two hours without interruption. After documentation of normal RRA flow by urgent Doppler ultrasound, the radial sheath was removed. The next day, the patient was discharged with no evidence of hand ischemia and a well palpable RRA pulse. One month later, a clinical assessment and Doppler ultrasound study indicated normal flow in RRA.

DISCUSSION

Periprocedural radial artery perforation has been reported in 0.1 -1.0% of patients undergoing transradial interventions. However, there are recently published reports that indicate substantially lower incidences.^[5] Perforation often occurs in small, tortuous, atherosclerotic arteries. Advanced age, hypertension and anatomic variations, like radial loops and high radial-ulnar bifurcation, are predisposing factors for this rarely seen entity. Forceful manipulation of the guidewire and catheters may also result in iatrogenic radial artery perforations.^[6,7] In our case, perforation occurred during the advancement of the guidewire although there was no forceful manipulation.

The presence of radial artery perforation should be suspected when there is resistance to wire or catheter advancement especially when the patient has a new developed pain on the access site in the presence or absence of swelling. Early recognition of the perforation and immediate treatment are absolutely of great importance to prevent major hematoma, compartment syndrome and subsequent acute hand ischemia. After the diagnosis, the perforated segment should be crossed by meticulous manipulation of 0.032 inch hydrophilic or 0.014 inch PTCA guidewires. We have crossed the perforation gently with the same 0.035 inch hydrophilic guidewire after intra-arterial administration of nitroglycerin and additional 2.5 mg verapamil. Concomitant spasm contributes to lumen obstruction impeding the advancement of the wires across the perforated segment. Anti-spasmodic agents may be tried as an adjunct to mechanical crossing with hydrophilic wires.

After crossing, diagnostic or guiding catheters are placed proximal to the perforation and act as a sealing agent with external compression by a sphygmomanometer cuff at the level of systolic blood pressure. This treatment is simple and permits the operator to

continue the procedure. We have treated the complication of our case with this technique, but we were not able to complete the interventional procedure via radial access because of the small radial artery size and intense vasospasm. In order to overcome this problem, a long sheath (25 cm) emplacement covering the area of perforation and reaching the proximal unaffected segment may be used. Some recent case reports suggest that the use of a long sheath not only seals the perforation but also enables the operator to proceed and complete the procedure without a requirement for a second artery access.^[8]

Dual antiplatelet therapy plus routine use of unfractionated heparin administration during transradial interventions obviously aggravate the extravasation if perforation occurs. For this reason, the use of protamine sulfate to neutralize heparin as an initial attempt to impede bleeding is recommended by some operators.^[5] We did not administrate protamine sulfate for neutralization, because the diagnostic catheter placed over the perforated segment in the lumen and sphygmomanometer cuff covering the forearm acted as a sealing agent together and stopped the extravasation even if the patient was fully anticoagulated. Blood flow into the perforated segment was evidently diminished via external pressure by sphygmomanometer and internal obstruction by the catheter. But, it is important to denote that neutralization of heparin is mandatory when RRA angiography discloses continuation of extravasation despite these maneuvers.

When these simple strategies fail, prolonged balloon inflation across the perforated segment may be utilized together with administration of the protamine sulfate. If bleeding continues, PTFE covered stents may be used to seal the perforation as the last solution.^[9] Clinical assessment of the patient's palmar arch flow by vascular Doppler ultrasound should be performed immediately after the procedure and at a one month follow-up to document healing of the perforated segment.

Conflict-of-interest issues regarding the authorship or article: None declared.

REFERENCES

1. Campeau L. Percutaneous radial artery approach for coronary angiography. *Cathet Cardiovasc Diagn* 1989;16:3-7. [\[CrossRef\]](#)
2. Brueck M, Bandorski D, Kramer W, Wiczorek M, Hölting R, Tillmanns H. A randomized comparison of transradial ver-

- sus transfemoral approach for coronary angiography and angioplasty. *JACC Cardiovasc Interv* 2009;2:1047-54. [[CrossRef](#)]
3. Rao SV, Cohen MG, Kandzari DE, Bertrand OF, Gilchrist IC. The transradial approach to percutaneous coronary intervention: historical perspective, current concepts, and future directions. *J Am Coll Cardiol* 2010;55:2187-95. [[CrossRef](#)]
 4. Patel T, Shah S, Sanghavi K, Pancholy S. Management of radial and brachial artery perforations during transradial procedures-a practical approach. *J Invasive Cardiol* 2009;21:544-7.
 5. Al-Sekaiti R, Ali M, Sallam M. Radial artery perforation after coronary intervention: is there a role for covered coronary stent? *Catheter Cardiovasc Interv* 2011;78:632-5. [[CrossRef](#)]
 6. Wang PJ, Tian X, Zhang Q. Acute compartment syndrome in a patient after transradial access for percutaneous cardiac intervention. [Article in Chinese] *Zhonghua Xin Xue Guan Bing Za Zhi* 2007;35:496. [Abstract]
 7. Dandekar VK, Vidovich MI, Shroff AR. Complications of transradial catheterization. *Cardiovasc Revasc Med* 2012;13:39-50. [[CrossRef](#)]
 8. Pujara K, Wood A, Roberts EB. Management of radial artery perforation during coronary angiography and angioplasty-a report of two cases. *Catheter Cardiovasc Interv* 2011;78:54-7. [[CrossRef](#)]
 9. Sallam MM, Ali M, Al-Sekaiti R. Management of radial artery perforation complicating coronary intervention: a step-wise approach. *J Interv Cardiol* 2011;24:401-6. [[CrossRef](#)]
-
- Key words:** Angioplasty, balloon, coronary/adverse effects; coronary angiography; coronary artery disease; iatrogenic disease; radial artery/injuries; rupture; ultrasonography, Doppler.
- Anahtar sözcükler:** Anjiyoplasti, balon, koroner/yan etki; koroner anjiyografi; koroner arter hastalığı; iatrojenik hastalık; radyal arter/ yaralanma; yırtılma; ultrasonografi, Doppler.