

CASE REPORT

Polymorphic ventricular tachycardia due to variant angina diagnosed on Holter monitoring and confirmed with cold pressor test

Holter monitörizasyonu ile teşhis edilen ve soğuk bası testi ile tasdik edilen varyant anjina nedenli polimorfik ventriküler taşikardi

Semi Öztürk¹, M.D., Tuğba Aktemur², M.D., Muhsin Kalyoncuoğlu¹, M.D.,
Gündüz Durmuş¹, M.D., Mehmet Can¹, M.D.

¹Department of Cardiology, Haseki Training and Research Hospital, İstanbul, Turkey

²Department of Cardiology, Ersoy Hospitals Group, İstanbul, Turkey

Summary– A 52-year-old man complaining of persistent recurring chest pain at night underwent coronary angiogram at another institution. Normal coronaries were observed and he was discharged with muscle spasmolytic prescription. Since symptoms had continued, 24-hour Holter monitoring was ordered at our facility and results revealed huge ST elevation and polymorphic ventricular tachycardia. Cold pressor test performed in catheterization laboratory also resulted in ventricular tachycardia. Nifedipine was prescribed and follow-up Holter monitoring revealed no further vasospastic episodes. Utility of 24-hour Holter rhythm monitoring and cold pressor test in patients with recurrent chest pain at night is demonstrated in this report.

Diagnosis of vasospastic angina (VA) (variant, Prinzmetal angina) can be challenging, since it typically depends on use of drugs, such as ergonovine (ER) or acetylcholine (ACh), at time of diagnostic angiography. Operators sometimes skip this procedure as result of unavailability of the drugs, which may result in misdiagnosis. Easily conducted tests, 24-hour Holter monitoring and cold pressor test (CPT), can help the clinician diagnose VA. Presently described is case of VA diagnosed by Holter monitoring and confirmed with CPT.

CASE REPORT

A 52-year-old man presented at outpatient clinic complaining of chest pain persisting for 3 months.

Özet– Elli iki yaşındaki erkek hastaya inatçı ve gece tekrarlayan göğüs ağrısı nedeniyle başka bir merkezde koroner anjiyografi yapılmış ve koroner arterleri normal bulunmuş, hasta kas spazmı giderici ilaçlar ile taburcu edilmiş. Semptomları devam eden hastaya yapılan 24 saat Holter monitörizasyonunda dev ST yükselmesi ve polimorfik ventriküler taşikardi saptandı. Kateterizasyon laboratuvarında uygulanan soğuk bası testi de polimorfik ventriküler taşikardi ile sonuçlandı. Hastaya nifedipine başlandı ve Holter monitörizasyonu ile olaysız olarak takip edildi. Olgu sunumumuz gece tekrarlayıcı göğüs ağrısı olan hastalarda 24 saatlik ritm holteri değerlendirmesinin ve soğuk bası testinin yararını ortaya koymaktadır.

He described recurrent episodes of burning type of pain lasting for 5 minutes occurring every night and intensity of pain increasing in early morning.

Each episode of pain resolved itself without taking any medication. Coronary angiography performed 3 weeks earlier at another institution had revealed normal coronaries; however, pain had continued, despite use of 8 mg of thicocolchicoside twice a day for 1 week as recommended upon discharge. He had no relevant history of disease or smoking. Physical examination was unremarkable. Electrocardi-

Abbreviations:

ACh	Acetylcholine
COVADIS	Coronary Vasomotion Disorders International Study Group
ECG	Electrocardiography
ER	Ergonovine
CPT	Cold pressor test
VA	Vasospastic angina

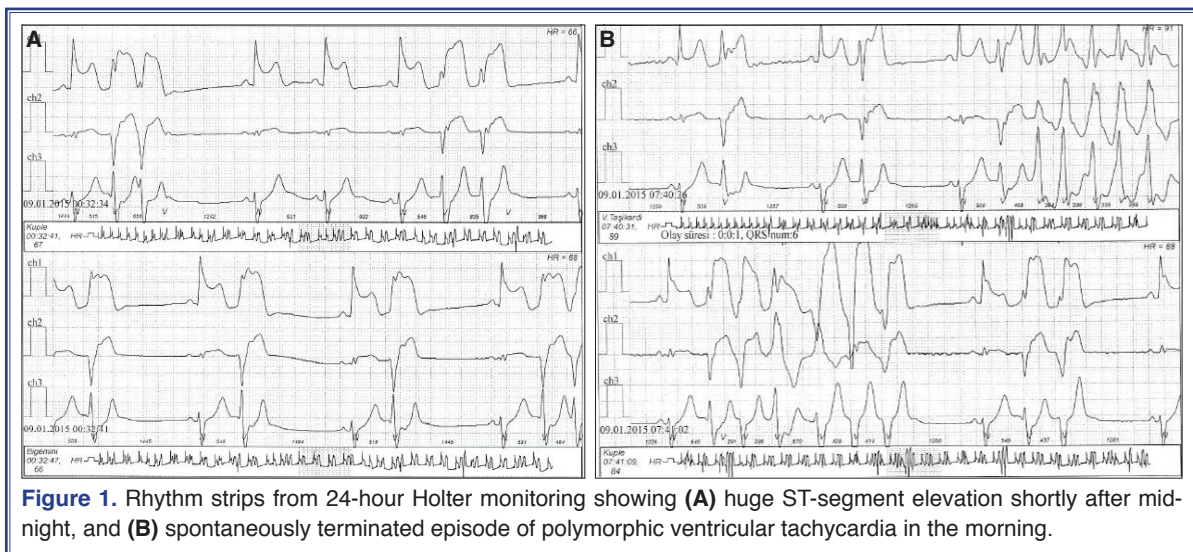
Received: August 03, 2016 Accepted: October 14, 2016

Correspondence: Dr. Semi Öztürk. Haseki Eğitim ve Araştırma Hastanesi, Kardiyoloji Kliniği, İstanbul, Turkey.

Tel: +90 212 - 529 44 00 e-mail: semi_ozturk@yahoo.com

© 2017 Turkish Society of Cardiology





ography (ECG) and treadmill exercise test findings were normal. Since it was night pain, 24-hour Holter monitoring was ordered. Results displayed gradual ST segment elevation leading to huge ST segment elevation (Figure 1a). Recurrent episodes of non-sustained polymorphic ventricular tachycardia that terminated spontaneously were observed (Figure 1b). The patient was taken into catheterization laboratory. Coronary angiogram was normal. Since ER and ACh were unavailable, we decided to perform CPT. Left Judkins catheter was positioned in coronary artery to visualize possible vasospasm. Huge ST segment elevation occurred 30 seconds after patient's left hand was immersed in ice water container and evolved into polymorphic ventricular tachycardia. Due to life-threatening arrhythmia, 100 mcg nitroglycerine was urgently injected into catheter and the hand was removed from ice water. ST segment elevation resolved in a few seconds. Extended release nifedipine 30 mg twice a day was prescribed. Follow-up 24-hour Holter monitoring on third day ruled out further vasospastic episode. Regular Holter monitoring for 1 year was uneventful.

DISCUSSION

VA was first described as rest angina and ST segment elevation.^[1] It most often occurs between midnight and early morning hours. Coronary Vasomotion Disorders International Study Group (COVADIS) published international criteria with nitrate-responsive angina as fundamental to diagnosis. COVADIS fur-

ther classified VA into definitive and possible forms. Definitive VA is defined as: (i) nitrate-responsive angina during spontaneous episodes and (ii) either transient ischemic ECG changes during spontaneous episodes or inducible coronary artery spasm criteria are all fulfilled. Suspected VA is defined as: (i) nitrate-responsive angina during spontaneous episodes and (ii) either equivocal/unavailable ischemic ECG changes during spontaneous episode, and equivocal inducible coronary artery spasm criteria.^[2]

According to COVADIS definition, provocation test is not required in case of transient ECG changes during nitrate-responsive episode, which confirms definitive VA. However, when nitrate-responsiveness is not documented or ECG changes are equivocal, further provocative tests are suggested. ER and ACh are widely used for this purpose. In a large study of 1508 selective spasm provocation tests, intracoronary ACh provoked spasms in 36.0% of patients, and intracoronary ER induced spasms in 29.8% of patients.^[3] Since ER and ACh have different effects on coronaries, recently, sequential provocation tests with alternating use of these 2 agents has been proposed to overcome limitations of standard provocation tests and increase sensitivity.^[4] Furthermore, in addition to providing diagnostic accuracy, a recent study found association between poorer prognosis and positive ER provocation test after 24 months of follow up.^[5]

Initially used CPT, a powerful sympathetic stimulus, to predict subsequent hypertension.^[6] CPT-mediated sympathetic stimulation causes increase in blood

pressure and heart rate, and thus increase in oxygen demand, which is compensated for with dilation of normal coronary arteries. On the contrary, however, CPT may result in paradoxical constriction in atherosclerotic coronaries.^[7] Diabetic and hypertensive patients without coronary atherosclerosis may have impaired response to CPT.^[8,9] Due to its close relationship to endothelial dysfunction, CPT is a predictor of cardiovascular events.^[9] Waters et al. compared sensitivity of exercise, cold pressor, and ER testing in provoking attacks of VA. They demonstrated that in patients with active VA, an attack can be provoked by ER in more than 90% of cases, by exercise in approximately 30%, and by the cold pressor test in about 10%.^[10] We performed cold pressor test in present case in order to determine nitrate responsiveness and to confirm definitive VA diagnosis despite low sensitivity of the test due to unavailability of ER or ACh.

Rarely, VA can cause ventricular arrhythmia, syncope, or sudden cardiac death.^[11] Although reperfusion arrhythmia after resolution of ST elevation was suspected, amount of ST segment elevation may be related to ventricular arrhythmia.^[12] Sympathetic overactivity and vagal withdrawal may have impact on vasospastic episodes. Vasospasm may involve normal coronaries; however, atherosclerotic segments are more susceptible. Despite the fact that prognosis of VA is accepted as benign, with 10-year survival rate of 80%, occasionally it causes sudden cardiac death.^[13] Regarding therapy, calcium channel blockers are first-option drugs and highly effective in suppressing symptoms, although there are rare failures.^[14] Since patients with coronary stenosis have poorer prognosis, stenting of severe lesions is recommended. Turning to prognosis, patients experiencing ventricular arrhythmia have increased risk for sudden death. Despite lack of randomized studies, cardiac defibrillator implantation has been proposed by some authors for survivors of sudden cardiac arrest who remain symptomatic despite medical therapy.^[15]

Our case provides information about importance of 24-hour rhythm Holter assessment and CPT in patients with night pain. This pain can easily be induced with musculoskeletal pain and results could be life-threatening. In a certain patient group, VA should be taken into account in differential diagnosis. Since our patient was responsive to medical therapy, patient was followed-up without further intervention. He did not

have additional episode of VA during 1-year follow-up.

Financial support

The authors received no financial support for the research or authorship of this article.

Conflict-of-interest issues regarding the authorship or article: None declared.

REFERENCES

1. Prinzmetal M, Kennamer R, Merliss R, Wada T, Bor N. Angina pectoris. I. A variant form of angina pectoris; preliminary report. *Am J Med* 1959;27:375–88. [\[CrossRef\]](#)
2. Beltrame JF, Crea F, Kaski JC, Ogawa H, Ong P, Sechtem U, et al. International standardization of diagnostic criteria for vasospastic angina. *Eur Heart J* 2015. [\[CrossRef\]](#)
3. Sueda S, Kohno H, Fukuda H, Ochi N, Kawada H, Hayashi Y, et al. Clinical impact of selective spasm provocation tests: comparisons between acetylcholine and ergonovine in 1508 examinations. *Coron Artery Dis* 2004;15:491–7. [\[CrossRef\]](#)
4. Sueda S, Miyoshi T, Sasaki Y, Sakaue T, Habara H, Kohno H. Sequential spasm provocation tests might overcome a limitation of the standard spasm provocation tests. *Coron Artery Dis* 2015;26:490–4. [\[CrossRef\]](#)
5. Shin DI, Baek SH, Her SH, Han SH, Ahn Y, Park KH, et al. The 24-Month Prognosis of Patients With Positive or Intermediate Results in the Intracoronary Ergonovine Provocation Test. *JACC Cardiovasc Interv* 2015;8:914–23. [\[CrossRef\]](#)
6. Hines EA, Brown G. The cold pressor test for measuring the reactivity of the blood pressure. Data concerning 571 normal hypertensive subjects. *Am Heart J* 1936;11:1–9. [\[CrossRef\]](#)
7. Mudge GH Jr, Grossman W, Mills RM Jr, Lesch M, Braunwald E. Reflex increase in coronary vascular resistance in patients with ischemic heart disease. *N Engl J Med* 1976;295:1333–7.
8. Antony I, Aptekar E, Lerebours G, Nitenberg A. Coronary artery constriction caused by the cold pressor test in human hypertension. *Hypertension* 1994;24:212–9. [\[CrossRef\]](#)
9. Nitenberg A, Valensi P, Sachs R, Cosson E, Attali JR, Antony I. Prognostic value of epicardial coronary artery constriction to the cold pressor test in type 2 diabetic patients with angiographically normal coronary arteries and no other major coronary risk factors. *Diabetes Care* 2004;27:208–15. [\[CrossRef\]](#)
10. Waters DD, Szlachcic J, Bonan R, Miller DD, Dauwe F, Theroux P. Comparative sensitivity of exercise, cold pressor and ergonovine testing in provoking attacks of variant angina in patients with active disease. *Circulation* 1983;67:310–5. [\[CrossRef\]](#)
11. Arias MA, Sánchez AM, Fajardo A. Sudden cardiac death during Holter recording in a patient with vasospastic angina. *Int J Cardiol* 2007;118:60–2. [\[CrossRef\]](#)
12. de Luna AB, Cygankiewicz I, Baranchuk A, Fiol M, Birnbaum Y, Nikus K, et al. Prinzmetal angina: ECG changes and

- clinical considerations: a consensus paper. *Ann Noninvasive Electrocardiol* 2014;19:442–53. [CrossRef]
13. Yasue H, Takizawa A, Nagao M, Nishida S, Horie M, Kubota J, et al. Long-term prognosis for patients with variant angina and influential factors. *Circulation* 1988;78:1–9. [CrossRef]
14. Ogawa T, Komukai K, Ogawa K, Kosuga T, Nagoshi T, Minai K, et al. High incidence of repeat anginal attacks despite treatment with calcium-channel blockers in patients with coronary spastic angina. *Circ J* 2009;73:512–5. [CrossRef]
15. Eschalier R, Souteyrand G, Jean F, Roux A, Combaret N, Saludas Y, et al. Should an implanted defibrillator be considered in patients with vasospastic angina? *Arch Cardiovasc Dis* 2014;107:42–7. [CrossRef]

Keywords: Holter monitoring; polymorphic ventricular tachycardia; variant angina.

Anahtar sözcükler: Holter monitorizasyonu; polimorfik ventriküler taşikardi; varyant anjina.