

## A demonstrative cardiac hydatid cyst in the interventricular septum

### *İnterventriküler septumda belirgin bir kardiyak hidatid kist*

Abdullah Nabi Aslan

Serdal Baştuğ

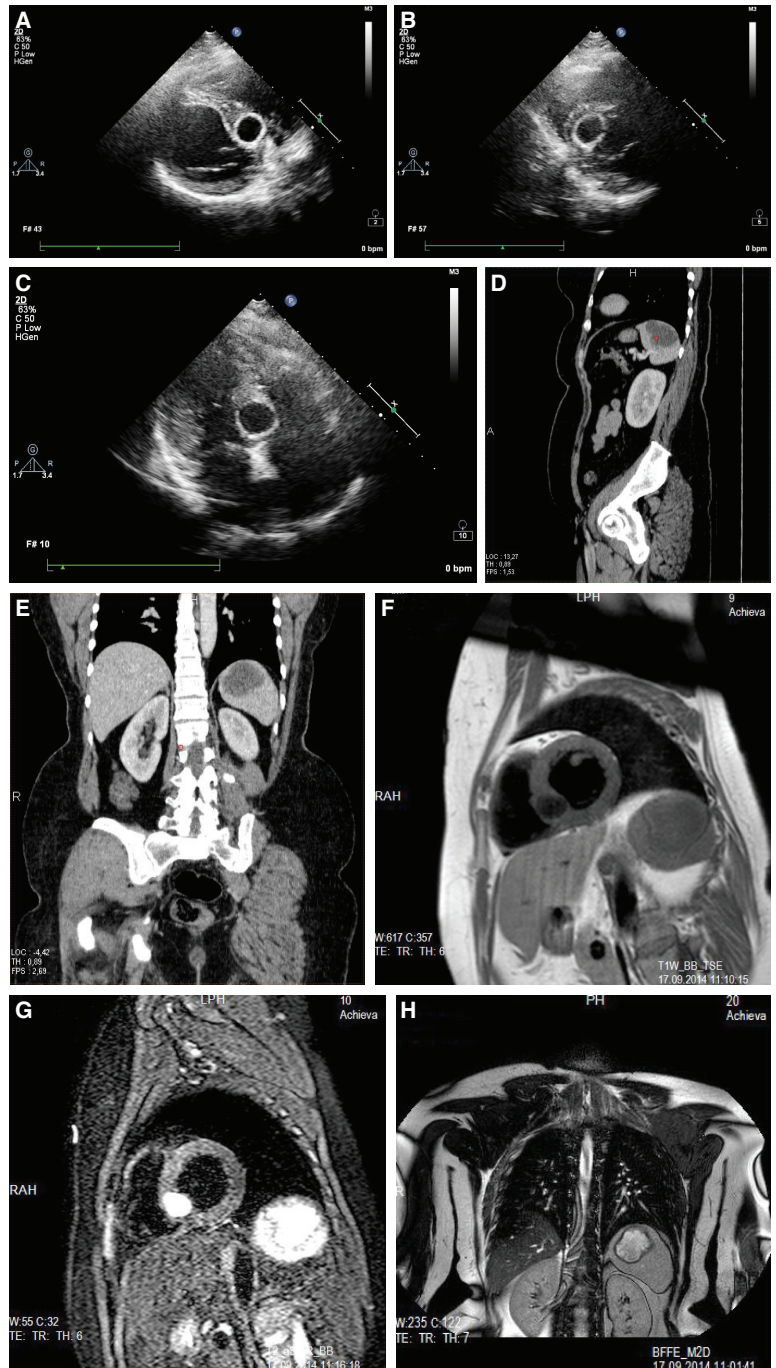
Zeynep Şeyma Türinay#

Engin Bozkurt#

Department of Cardiology,  
Ankara Atatürk Training and  
Research Hospital, Ankara;  
#Department of Cardiology,  
Yildirim Beyazıt University  
Faculty of Medicine, Ankara

A 53-year-old woman presented to our polyclinic complaining of knife-like chest pain of 6 weeks duration. Physical examination and electrocardiogram were unremarkable. Transthoracic

echocardiography revealed a smooth-edged, cystic mass with calcific contours measuring 19x20 mm in the lower part of the interventricular septum (Figure A-C). Abdominal ultrasonography revealed a normal liver, and a 42x25 mm smooth-edged, septate cystic lesion, compatible with a type 3 hydatid cyst, in the spleen. Abdominal computed tomography (CT) confirmed the presence of the cystic lesion in the spleen (Figure D and E). Cardiac magnetic resonance imaging (MRI) showed a 24x20 mm smooth-edged cystic mass lesion in the lower part of the interventricular septum (Figure F and G) and a 53x44 mm smooth-edged cystic mass lesion with lobulated contour in the upper pole of the spleen (Figure H). A thoracic CT revealed no extracardiac cyst in the thorax. The definite diagnosis of cardiac and splenic hydatid cyst was made based on the radiological findings. Albendazole treatment was then started for at least four weeks duration, and the patient was referred to cardiovascular surgery for cyst excision.



**Figures–** (A) Two-dimensional echocardiographic appearance of the hydatid cyst on the interventricular septum. A: Parasternal long-axis view, (B) Parasternal short-axis view, (C) Apical four-chamber view. Abdominal CT images showing splenic hydatid cyst and normal liver (D) Sagittal view (E) Coronal view. Cardiac MRI showing a cystic lesion on the interventricular septum and spleen (F) T1 weighted (G) T2 weighted (H) Splenic cyst.

