

## Case images

## Olgu görüntüsü

## Occurrence of atrial fibrillation while isolating the left atrial appendage due to vasospasm at the sinoatrial node artery

### *Sol atriyal apendiks izolasyonu sırasında sinoatriyal nod arterindeki spazma bağlı atriyum fibrilasyonu gelişmesi*

Uğur Canpolat<sup>1</sup>  
Banu Evranos<sup>1</sup>  
Hikmet Yorgun<sup>1</sup>  
Tuncay Hazirolan<sup>2</sup>  
Kudret Aytemir<sup>1</sup>

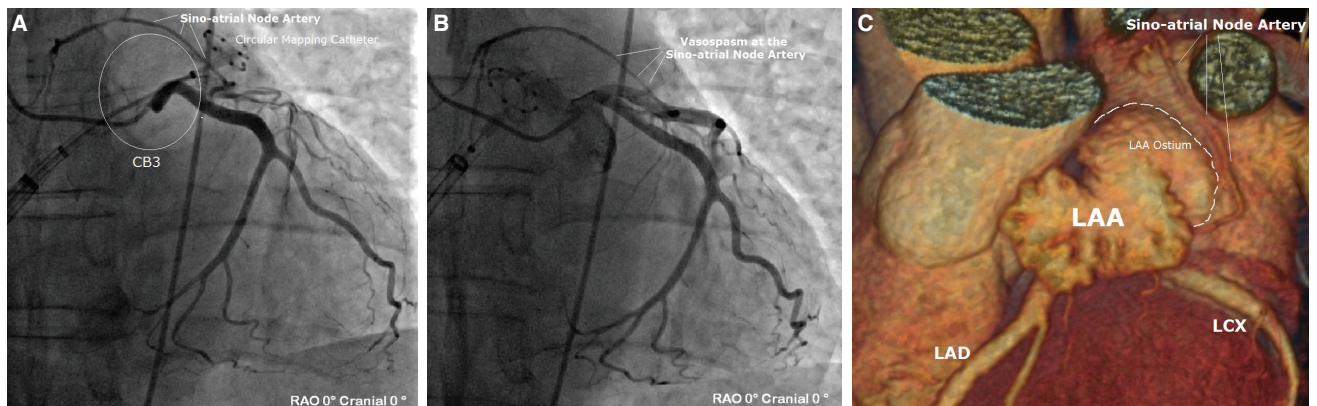
<sup>1</sup>Department of Cardiology,  
Hacettepe University Faculty  
of Medicine, Ankara, Turkey

<sup>2</sup>Department of Radiology,  
Hacettepe University Faculty  
of Medicine, Ankara, Turkey

A 58-year-old male with symptomatic persistent atrial fibrillation (AF) underwent index cryoablation. Computerized tomography angiography (CTA) revealed that sinoatrial node (SAN) artery originated from the left circumflex (LCX) artery. We routinely perform an empirical electrical left atrial appendage (LAA) isolation as well

as pulmonary vein isolation (PVI) in all patients with persistent AF. After a single transeptal puncture, a 28-mm third generation cryoballoon (CB3-Advance Short Tip; Medtronic, Inc., Minneapolis, MN, USA) and inner lumen circular mapping catheter (Achieve 15-mm; Medtronic, Inc., Minneapolis, MN, USA) were advanced into the LA. After isolation of all the

PV potentials, the circular mapping catheter was advanced into the LAA and the CB3 was inflated and positioned at the LAA ostium, aiming for complete occlusion (Video 1). The left phrenic nerve, because it neighbored the LAA, was monitored by fluoroscopy during spontaneous breathing. Due to anatomical knowledge of close proximity of LCX and SAN artery to the LAA, a simultaneous left coronary sine-angiogram was performed during LAA isolation (Figure A). Acute onset of AF at freezing time of 205 seconds and CB temperature of  $-33^{\circ}\text{C}$  occurred. The CB was deflated immediately and the catheter was withdrawn from LAA into the LA. Control cine-angiography revealed a vasospasm at the SAN artery (Figure B). After administration of intracoronary nitrate, vasospasm was rapidly relieved (Video 1\*). The patient spontaneously converted to sinus rhythm within 5 minutes. The procedure was finalized uneventfully. After the procedure, the pre-ablation CTA raw data were analyzed and the close proximity of LAA ostium to SAN artery course was confirmed (Figure C).



**Figures– (A)** Simultaneous left coronary sine-angiogram during left atrial appendage (LAA) isolation using cryoballoon. **(B)** Control cine-angiography revealed a vasospasm at the sinoatrial node (SAN) artery. **(C)** Pre-procedural computerized tomography angiography showing the close proximity of the LAA ostium to the SAN artery course. \*Supplementary video files associated with this presentation can be found in the online version of the journal.