

## Görüntülü olgu örnekleri

## Case images

## Left ventricular “grape-shaped”, mobile thrombi in an elderly patient

## Yaşlı bir hastada sol ventriküler “üzüm şekilli” hareketli trombüsler

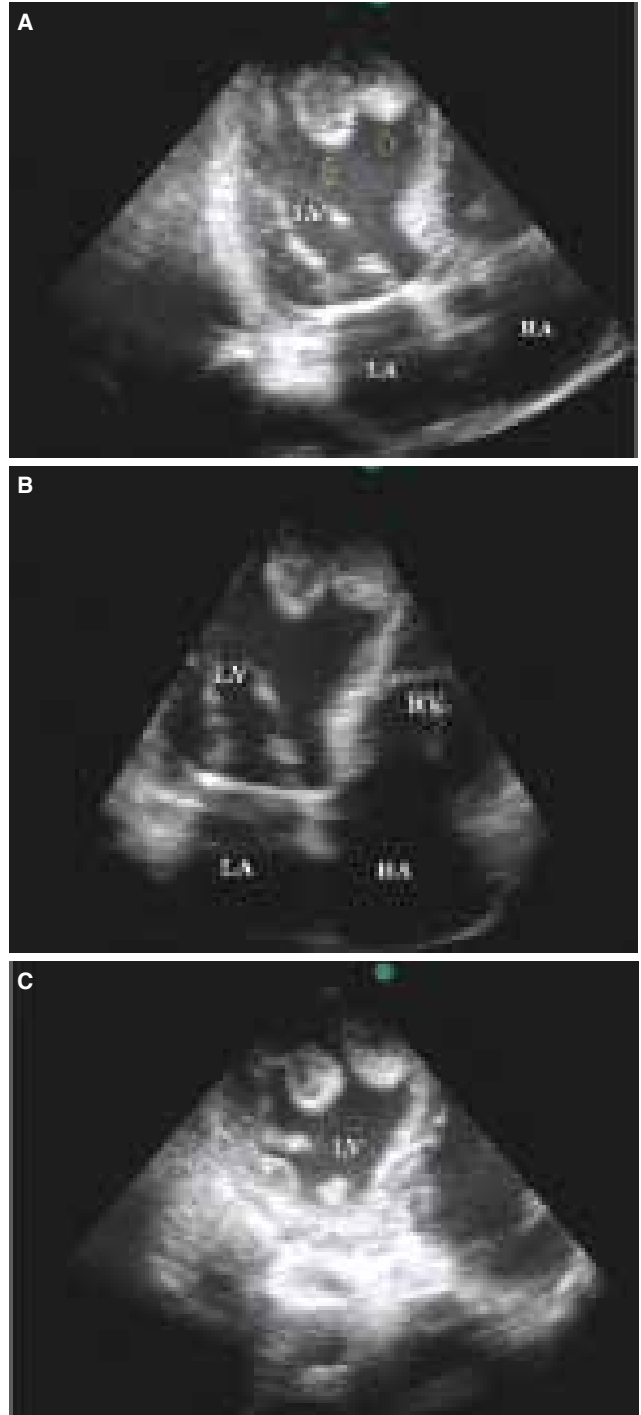
Yalçın Velibey

Alırıza Erbay

Emrah Usta

Department of Cardiology, Bitlis State Hospital, Bitlis

An immobile 86-year-old female patient presented with shortness of breath (NYHA IV) and a prior history of hypertension, Alzheimer’s disease and anterior myocardial infarction in 2011. On admission, her arterial blood pressure and heart rate were 155/90 mmHg and 70 bpm, respectively. Electrocardiography evaluation demonstrated pathologic Q waves in the V1-V6 leads. Chest X-ray revealed the presence of interstitial pulmonary edema. Routine laboratory testing revealed normal electrolyte levels and renal and liver functions. However, serum brain natriuretic peptide was elevated (1100 pg/dL). Transthoracic echocardiography (TTE) revealed an enlarged left ventricle with severe interventricular septal and anterior wall hypokinesis, moderate mitral and tricuspid regurgitation, and left ventricular “grape-shaped”, large (3.2x2.1 cm and 2.9x2.0 cm) and mobile thrombi (Figure A-C, Video 1\*). Ejection fraction and pulmonary artery systolic pressure were 25% and 50 mmHg, respectively. The patient was transferred to the intensive care unit and was treated with standard acute decompensated heart failure medications (ramipril 2.5 mg, spironolactone 25 mg and metoprolol succinate 50 mg once per day and 0.6 mg/kg/h intravenous furosemide infusion over three hours with noninvasive ventilation) and intravenous unfractionated heparin therapy (80 U/kg bolus subsequently 18 U/kg/hour infusion over 48 hours). Sudden asystole developed after 48 hours despite the good response to intravenous diuretic therapy. The patient died following an attempt at cardiopulmonary resuscitation (CPR). Thrombus was observed in the same location during the TTE created during the CPR.



**Figures**– Enlarged left heart and apical thrombi from the apical four-chamber (A and B) and short-axis (C) view. \*Supplementary video files associated with this presentation can be found in the online version of the journal.