

## Arteriovenous fistula between descending aorta and left inferior pulmonary vein: Closure with vascular plugs

### Vasküler tıkaç ile kapatılan inen aort ile sol alt pulmoner ven arasında arteriyovenöz fistül

Mustafa Kösecik, M.D., Nurullah Doğan, M.D.,# Bahri Elmas, M.D.\*

Department of Pediatric Cardiology, Sakarya University Faculty of Medicine, Sakarya, Turkey

#Department of Radiology, Bahar Private Hospital, Bursa, Turkey

\*Department of Pediatrics, Sakarya University Faculty of Medicine, Sakarya, Turkey

**Summary**– Echocardiography revealed systemic artery to pulmonary venous fistula, a rare vascular anomaly, in a 20-month-old girl, and multislice computed tomography angiography (CTA) was performed to rule out congenital heart disease. Normal bronchial connection and pulmonary vasculature were observed in the lung. The fistula drained through the left inferior pulmonary vein to the left atrium leading to a left-to-left shunt. Percutaneous intervention was performed in 2 stages using Amplatzer vascular plugs to close successfully.

**Özet**– Yirmi aylık kız çocuğu, kilo alamama ve kalpte üfürüm duyulması nedeniyle gönderildi. Ekokardiyografik incelemesinde sol atriya sol alt pulmoner ven yoluyla açılan fistül olabileceği düşünüldü. Çok kesitli bilgisayarlı tomografi anjiyografisinde inen aort ile sol alt pulmoner ven arasındaki soldan sola şanlı fistül varlığı doğrulandı. Akciğerin bronş ve damar yapısı normaldi. Fistül perkütan girişimle iki aşamada Amplatzer damar tıkaçı kullanılarak başarı ile kapatıldı.

**C**ongenital systemic arteriovenous fistula (AVF) arising from the aorta and draining through the pulmonary vein to the left atrium without lung sequestration is a rare vascular malformation.<sup>[1,2]</sup> On physical examination there is usually a continuous or systolic murmur. Clinical presentation depends upon size and place of the vascular malformation.<sup>[3]</sup> If there is suspicion of AVF on physical examination and echocardiography, multislice computed tomography angiography (CTA) can be helpful in confirming diagnosis and anatomic model, and in choosing appropriate treatment modality.<sup>[3,4]</sup> While surgical ligation was once the recommended therapy for AVF, percutaneous intervention has come to the forefront.<sup>[1–3,5]</sup>

#### Abbreviations:

AVF Arteriovenous fistula  
CTA Computed tomography angiography

A rare case of AVF between the thoracic aorta and left inferior pulmonary vein occluded with Amplatzer

vascular plugs (AGA Medical Corporation, Golden Valley, MN, USA) is described in the present report.

#### CASE REPORT

A 20-month-old girl with failure to thrive and cardiac murmur was referred with suspected congenital heart disease by a pediatrician for echocardiography. Her weight and height were 9 kg (<3<sup>rd</sup> percentile) and 78 cm (10<sup>th</sup>–25<sup>th</sup> percentiles), respectively. Physical examination confirmed presence of grade 3/6 systolic murmur, heard over the apical region and radiating to the mid-scapular region posteriorly. A hyperdynamic pulse at the rate of 110/min, a forceful left ventricular apex impulse, and mild hepatomegaly were observed. Neither cyanosis nor clubbing were present. Chest radiography showed mild cardiomegaly (cardiothoracic ratio=0.54) with increased pulmonary vascular markings, particularly in the lower left pulmonary region. The patient had mild clinical congestive heart failure.

Received: June 24, 2015 Accepted: August 17, 2015

Correspondence: Dr. Mustafa Kösecik. Sakarya Üniversitesi Tıp Fakültesi, Çocuk Kardiyoloji Bilim Dalı, Sakarya, Turkey.

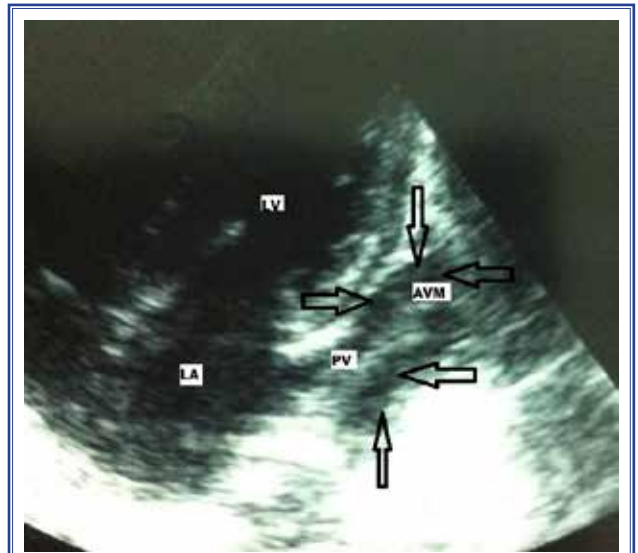
Tel: +90 264 - 444 54 00 e-mail: mustafakosecik@yahoo.com

© 2016 Turkish Society of Cardiology



Echocardiography revealed left atrial and ventricular enlargement, moderate mitral-valve regurgitation, and increased blood flow into the left atrium from the enlarged left inferior pulmonary vein. An abnormal vessel that demonstrated communication with the left inferior pulmonary vein was noted nearly to the left atrium (Figure 1). Diagnosis of the patient may be arteriovenous malformation/fistula but was not clear. Hence, multislice CTA was performed, revealing abnormal communication, AVF, originating from the thoracic aorta and draining into the left inferior pulmonary vein (Figure 2). The fistula drained through the left inferior pulmonary vein to the left atrium leading to a left-to-left shunt. The lung had normal bronchial connection and pulmonary vasculature.

The patient had failure to thrive and mild clinical congestive heart failure. Therefore, the fistula was occluded with vascular plugs. Cardiac catheterization was performed via the transfemoral approach using a 5 French femoral sheath and catheters. Thoracic aortogram revealed AVF originating from the thoracic aorta, draining into the left inferior pulmonary vein, and finally into the left atrium (Video 1<sup>\*</sup>). Fistula diameter on the side of the thoracic aorta was 6.5 mm; 10 mm Amplatzer vascular plug was embolized with successful closure. Postprocedure thoracic aortogram showed complete occlusion. However, after 1 day, clinical and echocardiographic findings indicated an



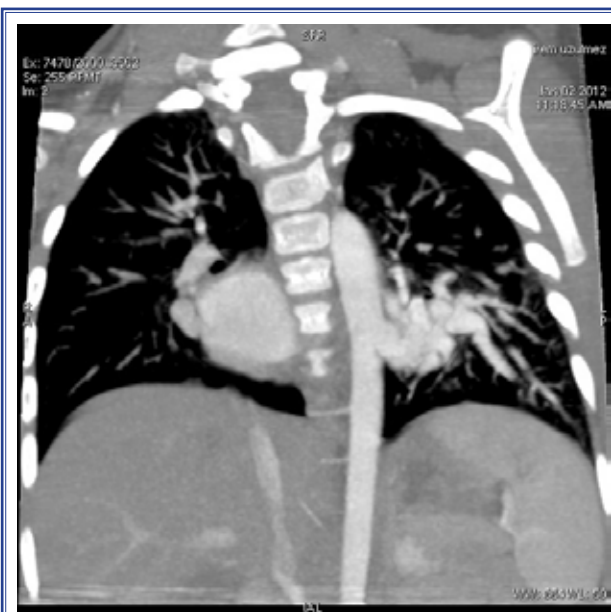
**Figure 1.** 2-dimensional echocardiographic image showing an abnormal vessel that demonstrated communication with the left inferior pulmonary vein.

incomplete occlusion. It was thought that device displaced distally due to smaller size and the open fistula, and a second intervention was scheduled in order to occlude the fistula. The second intervention took place 2 months later. Thoracic aortogram showed that the device had displaced distally and that the fistula was open. It was closed with embolization of 12 mm Amplatzer vascular plug. Post procedure thoracic aortogram showed a complete occlusion (Video 2<sup>\*</sup>). After 6-month follow-up, clinical and echocardiographic findings demonstrated a complete occlusion and patient gained 1 kg, showing improvement in appetite.

## DISCUSSION

AVFs are communication between arterial and venous systems without a normal capillary bed. Lack of resistance of capillary bed results in large blood flow through the fistula. Clinical presentation is dependent on location and size of the fistula and the affected vascular structure. Continuous or systolic murmur can be heard on the affected site. Larger fistulas may cause congestive heart failure.<sup>[1,3]</sup> This situation requires further clinical evaluation.

Congenital AVF arising from thoracic aorta and draining into the left inferior pulmonary vein without lung sequestration is an extremely rare malformation. <sup>[1,6,7]</sup> Pernot et al. reported a case in which left lobectomy showed a fistula arising from the aorta and a



**Figure 2.** Multislice computed tomography image showing an arteriovenous fistula arising from the descending aorta.

pulmonary vein, associated with absence of a branch of the pulmonary artery.<sup>[8]</sup> Dahiya et al. reported a fistula between the abdominal aorta and right inferior pulmonary vein in an asymptomatic 25-year-old man; surgical ligation performed.<sup>[9]</sup> Shebani et al. reported a fistula between the descending aorta and the right pulmonary vein in a neonate presenting with heart failure; surgical ligation was also performed.<sup>[1]</sup> To the best of our knowledge, the present is the first report of a case in which percutaneous occlusion was performed to treat a significant left-to-left shunt due to fistulous communication between the thoracic aorta and left inferior pulmonary vein.

In cases in which AVF is clinically and echocardiographically suspected, multislice CTA is an appropriate imaging method to confirm diagnosis and select therapy modality.<sup>[4,7]</sup> In addition, cardiac catheterization and angiography is necessary for both diagnosis and intervention procedures.<sup>[3]</sup>

Brühlmann et al. described the first transarterial therapeutic embolization of systemic arterialization of the lung without sequestration.<sup>[10]</sup> Girona et al. described the successful closure of 51 vascular fistulas in 30 patients aged from 6 days to 28 years by percutaneous embolization, in which coils were utilized for smaller fistulas and vascular plugs were utilized for larger fistulas, as in our case.<sup>[11]</sup> Coils and vascular plugs were utilized for successful occlusion during endovascular intervention in the selected cases.<sup>[2,5,7]</sup>

Amplatzer vascular plugs were used for transcatheter embolization in the peripheral vasculature and for occlusion of abnormal vessel communications with reported technical success rate of 100%.<sup>[7,12]</sup> The patient in the present report had clinically congestive heart failure, cardiomegaly demonstrated by X-ray, and increased left ventricular end-diastolic diameter and moderate mitral regurgitation demonstrated by echocardiography. Therefore, the fistulous communication between the thoracic aorta and left inferior pulmonary vein was occluded with Amplatzer vascular plugs.

Aorta to pulmonary venous fistula without lung sequestration is extremely rare. No similar case has been reported in the literature. Transcatheter vascular plug occlusion therapy should be considered as a preferred option for patients with moderate to large systemic

AVF and congestive heart failure.

**Conflict-of-interest issues regarding the authorship or article: None declared.**

**\*Supplementary video file associated with this article can be found in the online version of the journal.**

## REFERENCES

1. Shebani SO, Khan MD, Tofeig MA. A congenital fistula between the descending aorta and the right pulmonary vein in a neonate presenting with heart failure. *Cardiol Young* 2007;17:563–4. [CrossRef](#)
2. Kosutic J, Minic P, Sovtic A, Prijic S. Upper lung lobe systemic artery-pulmonary vein fistula with signs and symptoms of congestive heart failure: successful treatment with coil embolization. *J Vasc Interv Radiol* 2007;18:299–302. [CrossRef](#)
3. Keane JF, Fyler DC. Vascular fistulae. In: Keane JF, Lock JE, Fyler DC, editors. *Nadas' pediatric cardiology*. 2nd ed. Philadelphia, PA: Saunders Elsevier; 2006. p. 799–804.
4. Moral S, Ortuño P, Aboal J. Multislice CT in congenital heart disease: Partial anomalous pulmonary venous connection. *Pediatr Cardiol* 2008;29:1120–1. [CrossRef](#)
5. Recto MR, Elbl F. Transcatheter coil occlusion of a thoracic arteriovenous fistula in an infant with congestive heart failure. *Tex Heart Inst J* 2001;28:119–21.
6. Currarino G, Willis K, Miller W. Congenital fistula between an aberrant systemic artery and a pulmonary vein without sequestration. A report of three cases. *J Pediatr* 1975;87:554–7.
7. Jariwala P, Ramesh G, Sarat Chandra K. Congenital anomalous/aberrant systemic artery to pulmonary venous fistula: closure with vascular plugs & coil embolization. *Indian Heart J* 2014;66:95–103. [CrossRef](#)
8. Pernot C, Simon P, Hoeffel JC, Worms AM, Marcon F, Prevot J. Systemic artery-pulmonary vein fistula without sequestration. *Pediatr Radiol* 1991;21:158–9. [CrossRef](#)
9. Dahiya A, Collier P, Krasuski R, Kalahasti V, Del Nido P, Stewart WJ. Aorta-to-pulmonary vein fistula in an asymptomatic 25-year-old man. *Circulation* 2013;127:1727–9. [CrossRef](#)
10. Brühlmann W, Weishaupt D, Goebel N, Imhof E. Therapeutic embolization of a systemic arterialization of lung without sequestration. *Eur Radiol* 1998;8:355–8. [CrossRef](#)
11. Girona J, Martí G, Betrián P, Gran F, Casaldàliga J. Percutaneous embolization of vascular fistulas using coils or Amplatzer vascular plugs. *Rev Esp Cardiol* 2009;62:765–73. [CrossRef](#)
12. Cil B, Peynircioğlu B, Canyiğit M, Geyik S, Ciftçi T. Peripheral vascular applications of the Amplatzer vascular plug. *Diagn Interv Radiol* 2008;14:35–9.

**Keywords:** Arteriovenous fistula; vascular plugs.

**Anahtar sözcükler:** Arteriovenöz fistül; vasküler tıkaç.