

Bulging sign: A precursor of annular rupture observed before aortic balloon rupture during valvuloplasty in transcatheter aortic valve implantation

Kabartı işareti: Transkateter aort kapak implantasyonunda valvuloplasti esnasında aortik balon rüptüründen önce görülen anüler rüptürün habercisi

Hacı Ahmet Kasapkara, M.D., Abdullah Nabi Aslan, M.D.,# Tahir Durmaz, M.D., Engin Bozkurt, M.D.

Department of Cardiology, Yıldırım Beyazıt University Faculty of Medicine, Ankara, Turkey

#Department of Cardiology, Atatürk Training and Research Hospital, Ankara, Turkey

Summary– Transcatheter aortic-valve implantation (TAVI) is a reliable alternative to surgical aortic-valve replacement in inoperable or high-risk patients. However, this evolving therapy is associated with a wide range of potential complications— some specific to TAVI, some often fatal. Prevention, early recognition, and taking essential precautions will significantly improve results. The case of an 85-year-old woman with balloon rupture during valvuloplasty in TAVI, a very rare and potentially fatal complication, is presented.

Özet– Transkateter aort kapak implantasyonu (TAVI) cerrahi açıdan yüksek riskli olan ya da ameliyat edilemeyen hastalarda cerrahi aort kapak replasmanına güvenilir bir alternatiftir. Ancak, bu gelişmekte olan tedavi bazısı TAVI'ye özgü, bazısı sıklıkla ölümcül olan geniş yelpazede komplikasyon riski taşımaktadır. Bu komplikasyonların önlenmesi, erken saptanması ve gerekli önlemlerin önceden alınması bu işlemin sonuçlarını anlamlı derecede iyileştirecektir. Burada, TAVI için valvüloplasti yapılırken çok nadir görülen ve ölümcül olabilen bir komplikasyon olan balon rüptürü gelişen 85 yaşında bir kadın hasta sunuldu.

Transcatheter aortic-valve implantation (TAVI) is a promising technology for high-risk or inoperable patients who are not candidates for conventional surgical aortic-valve replacement.^[1] However, significant challenges must be overcome before the procedure can be considered a truly safe alternative. Aortic balloon rupture during TAVI is a rare complication that can be observed during valvuloplasty just before valve deployment.

This complication in an 85-year-old woman is reported, and potential precautions are described.

CASE REPORT

An 85-year-old woman with a history of coronary artery bypass surgery and heart failure, and with New York Heart Association class III-IV symptoms, was

evaluated for very severe aortic stenosis. Electrocardiogram revealed atrial fibrillation with a rate of 112 bpm. Transthoracic echocardiogram showed low left ventricular ejection fraction (25%), very severe aortic stenosis with a mean gradient of 114 mmHg and aortic valve area of 0.4 cm², moderate aortic regurgitation (AR), and very severe pulmonary hypertension (systolic pulmonary artery pressure: 90 mmHg). Comorbid diseases of the patient included hypertension, insulin-dependent diabetes mellitus, atrial fibrillation, and chronic obstructive pulmonary disease. Her calculated logistic EuroSCORE and STS score were 77.5% and 36.3%, respectively. Due to very high operative risk, TAVI

Abbreviations:

AR	Aortic regurgitation
BAV	Balloon aortic valvuloplasty
TAVI	Transcatheter aortic-valve implantation
TTE	Transthoracic echocardiography

Received: May 20, 2015 Accepted: August 18, 2015

Correspondence: Dr. Abdullah Nabi Aslan. 1238. Cad., Ata Apt., No: 10/35, Yukarı Öveçler, Ankara, Turkey.

Tel: +90 312 - 291 25 25 e-mail: drnabiaslan@hotmail.com

© 2016 Turkish Society of Cardiology



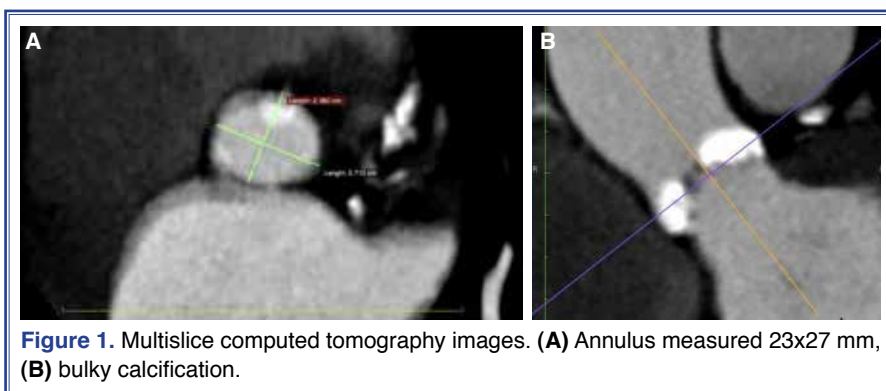


Figure 1. Multislice computed tomography images. **(A)** Annulus measured 23x27 mm, **(B)** bulky calcification.

was selected as treatment and informed consent was obtained.

Before the procedure, aortic annulus diameter was determined to be 22 mm in transthoracic echocardiography (TTE), 23 mm in transesophageal echocardiography, and 23x27 mm in multislice computed tomography (Figure 1a). Transesophageal echocardiography and multislice computed tomography demonstrated bulky calcification in all 3 leaflets of aortic valve (Figure 1b). With the use of multimodal imaging techniques, it was determined that a 26 mm Edwards SAPIEN XT valve (Edwards Lifesciences LLC., Irvine, CA, USA) would be implanted. The patient was taken to the catheterization laboratory for TAVI. After insertion of 18 French E sheath in the right femoral artery, aortic balloon valvuloplasty with 23x40 mm Edwards transfemoral balloon catheter (Edwards Lifesciences LLC., Irvine, CA, USA) was carried out across the aortic valve during simultaneous rapid ventricular pacing at 200 bpm. During procedure, dilatation then

bulging of the aortic root was observed just before rupture of the aortic balloon (Figure 2a-c, Video*). Blood pressure dropped (80/30 mmHg) suddenly for approximately 2 minutes. TTE was performed immediately with suspicion of aortic annulus rupture and cardiac tamponade. However, neither pericardial effusion or signs of annular rupture were present. The patient's blood pressure then increased to normal (110/60 mmHg). Due to high risk of annular rupture during balloon-expandable Edwards SAPIEN XT valve implantation, the option of conventional surgical aortic-valve replacement was discussed with relatives of the patient, and cardiovascular surgeons were consulted. The surgeons declined to perform open heart surgery due to the high risk to the patient. Due to the absence of self-expandable bioprostheses such as CoreValve (Medtronic CoreValve LLC., Santa Rosa, CA, USA) or Lotus Valve (Boston Scientific Corp., Fremont, CA, USA), we were forced to proceed with balloon-expandable Edwards SAPIEN XT valve, which greatly increased risk of annular rupture. The

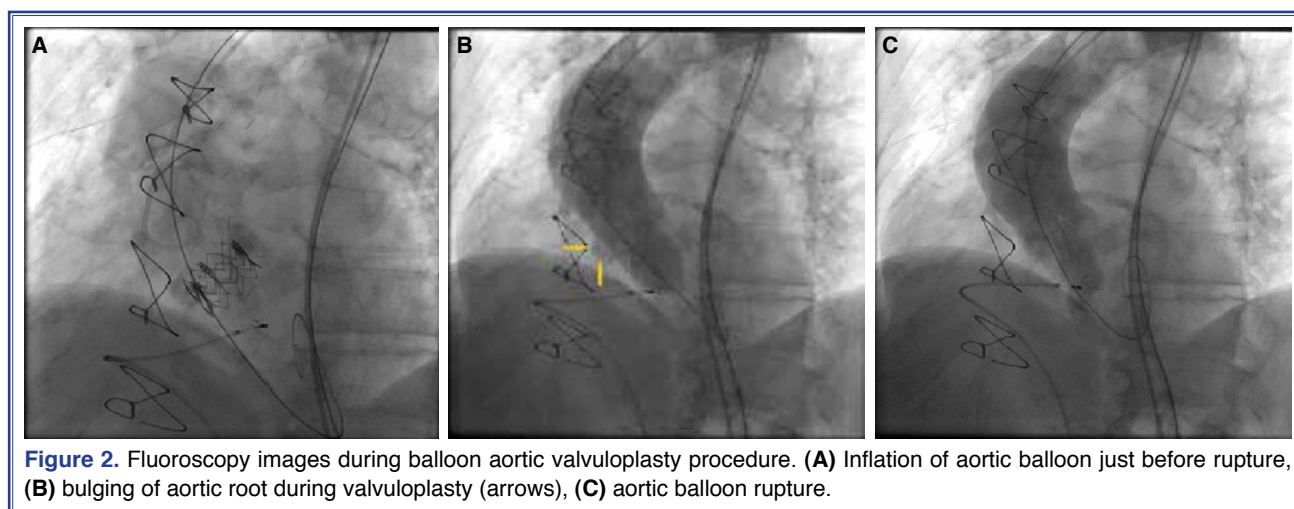


Figure 2. Fluoroscopy images during balloon aortic valvuloplasty procedure. **(A)** Inflation of aortic balloon just before rupture, **(B)** bulging of aortic root during valvuloplasty (arrows), **(C)** aortic balloon rupture.

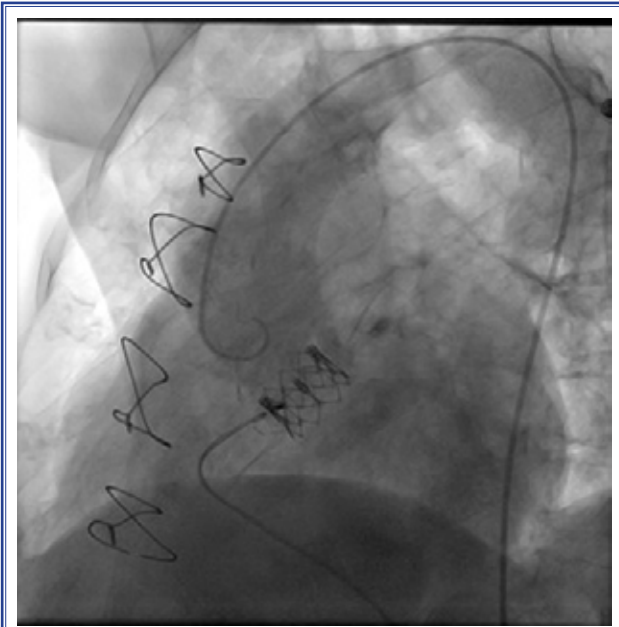


Figure 3. Successful 23 mm Edwards SAPIEN XT valve deployment.

relatives were again informed of extreme increase in risk, and procedure was resumed after consent was obtained. As a precaution, a 23 mm bioprosthetic valve was used. While this exposed the patient to an increased risk of high-grade paravalvular leak, it is a relatively benign complication, compared with annular rupture. The 23 mm valve was deployed successfully (Figure 3) with moderate paravalvular leak in aortography (Video*), and procedure was concluded. No complications were present at follow-ups, and the patient was discharged.

DISCUSSION

With an increasing number of TAVI procedures performed in recent years, there is a growing need to take essential precautions, and identify and appropriately manage potential complications. While balloon rupture during aortic valvuloplasty in TAVI has rarely been reported, it has been well described in balloon aortic valvuloplasty (BAV) literature.^[2] As reported in the Balloon Valvuloplasty Registry of the National Heart, Lung, and Blood Institute, balloon rupture occurred in 111 out of 674 patients who underwent BAV (17%).^[2] This complication is most commonly caused by a noncompliant, heavily calcified aortic root, by aggressive device oversizing, or by balloon pressure exceeding rated burst pressure during inflation.

^[3,4] Balloon rupture during pre-TAVI valvuloplasty can have potentially life-threatening results. These include aortic annular rupture with or without pericardial tamponade and acute severe AR leading to hemodynamic instability.^[4,5] Risk factors for annular rupture are nearly identical to those of aortic balloon rupture and include heavy annular calcification, aggressive balloon valvuloplasty, and excessive oversizing of the transcatheter valve.^[3]

In the present case, balloon rupture during BAV was caused by bulky calcification of the aortic root. Though aortic annular rupture was feared due to minutes of hemodynamic instability immediately following balloon rupture, TTE revealed neither pericardial effusion nor signs of annular rupture, and the patient recovered in 2 minutes. However, because the patient had high-risk criteria for annular rupture, precautions such as implantation of prosthesis via open heart surgery performed by cardiovascular surgeons or use of self-expandable transcatheter systems would have been necessary before valve deployment. Unfortunately, the surgeons declined to perform the surgery, and no self-expandable valves were available during the procedure. Postponing procedure until valve systems became available was considered. However, following BAV, moderate to severe AR was present on aortography. In addition, percutaneous closure technique with 2 ProGlides (Abbott Vascular Devices, Redwood City, CA, USA) had been used, and use of same access site for TAVI was not possible for long. Other access sites, including the left femoral artery and subclavian arteries, were not suitable for TAVI, and we did not have necessary experience with transapical TAVI.

In summary, due to poor long-term outcomes of BAV, presence of moderate to severe AR, absence of alternate access sites, high mortality rate, and cost-cutting measures, the procedure was resumed. Deployment of smaller bioprosthesis was determined to be the only means of decreasing risk of annular rupture, and 23 mm valve was used. No complications were present following procedure, and only moderate paravalvular leak was observed.

Five pieces of advice are offered to clinicians performing TAVI. First, such complications should be taken into consideration in patients with bulky calcification and severe AS. Second, comprehensive pre-procedural evaluation of the patient with various

imaging techniques is essential in the prevention of possible fatal complications, including annular rupture. Third, self-expandable valve systems should be available during procedure in addition to balloon-expandable bioprostheses for possible exchange. Fourth, it is recommended that smaller balloon-expandable bioprosthesis or self-expandable prosthesis are utilized in patients with high risk of annular rupture. Lastly and most importantly, it is recommended that clinicians should be aware of risk of aortic root rupture during BAV and attend to signs of bulging.

Conflict-of-interest issues regarding the authorship or article: None declared.

***Supplementary video file associated with this article can be found in the online version of the journal.**

REFERENCES

1. Leon MB, Smith CR, Mack M, Miller DC, Moses JW, Svensson LG, et al. Transcatheter aortic-valve implantation for aortic stenosis in patients who cannot undergo surgery. *N Engl J Med* 2010;363:1597–607. [CrossRef](#)
2. Percutaneous balloon aortic valvuloplasty. Acute and 30-day follow-up results in 674 patients from the NHLBI Balloon Valvuloplasty Registry. *Circulation* 1991;84:2383–97. [CrossRef](#)
3. Blanke P, Reinöhl J, Schlensak C, Siepe M, Pache G, Euringer W, et al. Prosthesis oversizing in balloon-expandable transcatheter aortic valve implantation is associated with contained rupture of the aortic root. *Circ Cardiovasc Interv* 2012;5(4):540–8. [CrossRef](#)
4. Berdajs D. Aortic root rupture: implications of catheter-guided aortic valve replacement. *Curr Opin Cardiol* 2013;28:632–8. [CrossRef](#)
5. Seiffert M, Conradi L, Baldus S, Schirmer J, Blankenberg S, Reichenspurner H, et al. Severe intraprocedural complications after transcatheter aortic valve implantation: calling for a heart team approach. *Eur J Cardiothorac Surg* 2013;44:478–84. [CrossRef](#)

Keywords: Aortic balloon rupture; transcatheter aortic-valve implantation; valvuloplasty.

Anahtar sözcükler: Aortik balon rüptürü; transkateter aort kapak implantasyonu; valvuloplasti.