

Subarachnoid hemorrhage that electrocardiographically mimics acute coronary syndrome: a case report

Elektrokardiyografik olarak akut koroner sendromu taklit eden subaraknoid kanama: Olgu sunumu

Erkan Köklü, M.D., İsa Öner Yüksel, M.D., Nermin Bayar, M.D.,
Selçuk Küçükseymen, M.D., Şakir Arslan, M.D.

Department of Cardiology, Antalya Training and Research Hospital, Antalya

Summary– Electrocardiography alterations and cardiac enzyme elevation have been reported in patients with cerebrovascular events in various articles. This case reports a case of syncope with an electrocardiography of atrioventricular complete block and extensive ST segment elevation. However, it was finally diagnosed as subarachnoid hemorrhage. To the best of our knowledge, this patient is the first case of subarachnoid hemorrhage mimicking ST elevation myocardial infarction with atrioventricular complete block.

Nonspecific ST-T wave changes on electrocardiography (ECG) and high troponin levels can be observed in subarachnoid hemorrhages (SAH) and intracranial bleedings. Although the exact pathophysiology is not well known, myocardial toxicity and transient coronary vasoconstriction due to catecholamine discharge feature among the possibilities.

This report presents a case of syncope with an ECG showing atrioventricular (AV) complete block along with ST elevations in lead II, III, and aVF. However, the patient was diagnosed with SAH. To the best of our knowledge, this is the first case of SAH presented as syncope with ST elevation myocardial infarction (STEMI) and AV complete block.

CASE REPORT

A 64-year-old female presented to the emergency department due to syncope. The patient was unconscious, and had no remarkable medical history. A

Özet– Birçok makalede serebrovasküler olaylar sırasında elektrokardiyografik değişiklikler ve kardiyak enzimlerde yükseklik bildirilmiştir. Bu yazıda sunduğumuz atriyoventriküler tam blokla birlikte belirgin derecede ST yükselmesi ile seyreden senkoplu olguya ileri incelemeler sonunda subaraknoid kanama tanısı konuldu. Klinik tecrübelerimiz ve yaptığımız literatür taramasına göre hastamız, ST yükselmesi miyokart enfarktüsünü taklit eden atriyoventriküler tam bloklu ve subaraknoid kanamalı ilk olgudur.

complaint of chest pain, dyspnea or trauma history before the syncope was recorded. The patient was bradycardic (42/min) and hypotensive (80/50 mmHg) on admission, and had a score of 7 on the Glasgow Coma Scale. On ECG, AV complete block with ST elevations in leads II, III, and aVF rather than diffuse ST segment elevation was observed (Figure 1a). Bundle branch block pattern was not observed on ECG. Parenteral 0.9% physiological serum and dopamine infusion was commenced. Respiratory arrest developed 10 minutes after admission and the patient was intubated. Cardiac arrest did not occur. The patient was immediately taken to the angiography laboratory in order to perform primary percutaneous coronary intervention and transient pacemaker implantation. The patient could not be given acetyl salicylic acid and clopidogrel due to

Abbreviations:

AV	Atrioventricular
CCT	Cranial computed tomography
ECG	Electrocardiography
SAH	Subarachnoid hemorrhages
STEMI	ST elevation myocardial infarction

Received: March 15, 2015 Accepted: July 08, 2015

Correspondence: Dr. Selçuk Küçükseymen. Varlık Mah., Kazım Karabekir Cad., 07100 Soğuksu, Antalya.

Tel: +90 242 - 249 44 00 e-mail: skucukseymen@gmail.com

© 2015 Turkish Society of Cardiology



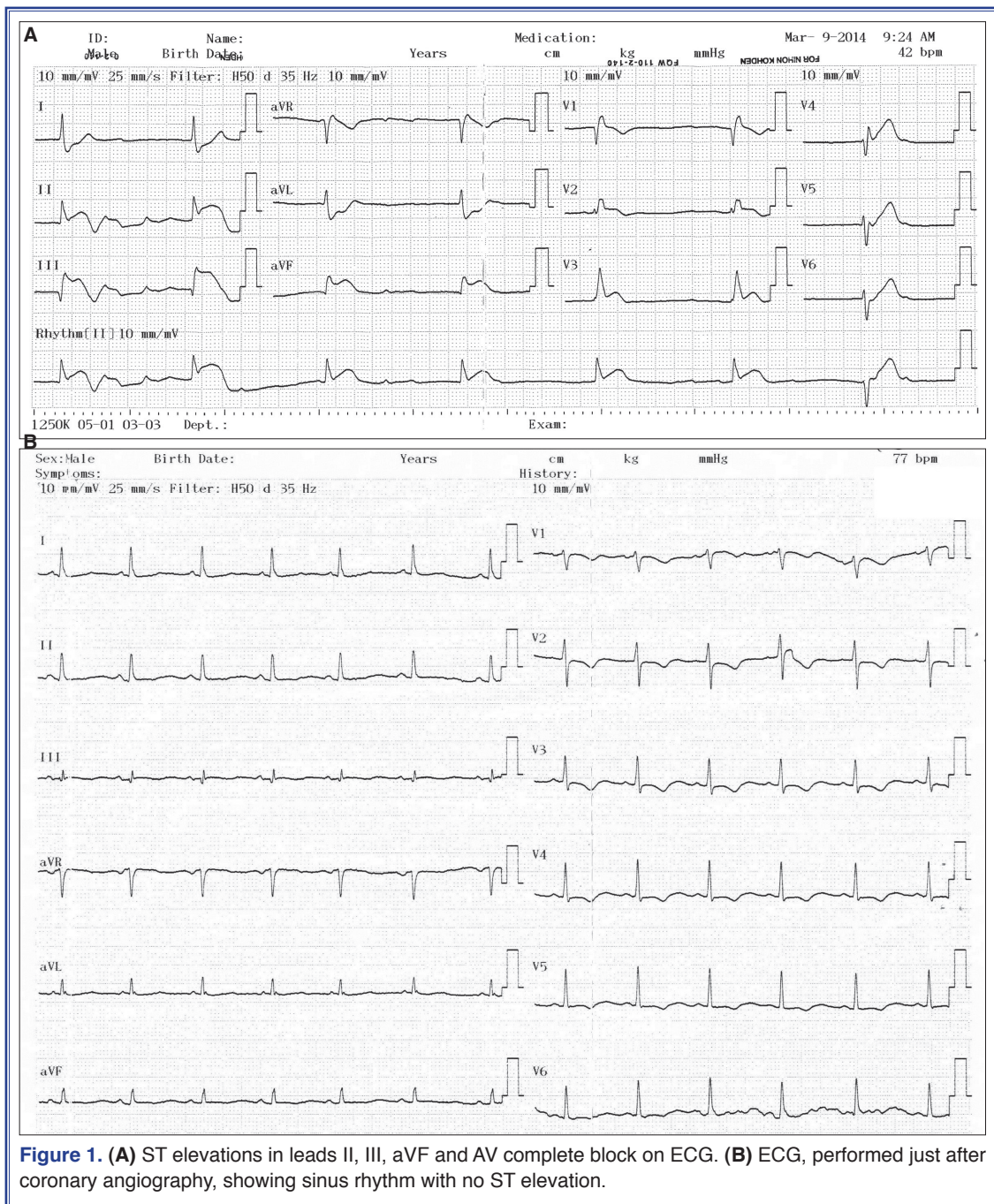


Figure 1. (A) ST elevations in leads II, III, aVF and AV complete block on ECG. (B) ECG, performed just after coronary angiography, showing sinus rhythm with no ST elevation.

unconsciousness, and heparin was not administered. However, the rhythm was sinus and ST elevations were resolved immediately after angiography (Figure 1b). Normal coronary arteries, ventriculography and ascending aortography were detected (Figure 2a-c). Transthoracic echocardiography findings were all normal, but troponin I level was high (1.3 ng/mL). The patient's serum potassium concentration was 4.3 mmol/L and calcium concentration 9.6 mg/dL; other

biochemical values were within the normal ranges. The patient underwent a cranial computed tomography (CCT) due to unconsciousness, and this revealed a 5.2x3.1 cm subarachnoid hemorrhage in the right parietal lobe (Figure 3). A right posterior communicating artery aneurysm was detected with CCT angiography (Figure 4). The patient was promptly operated on by neurovascular surgeons, but death occurred intraoperatively.

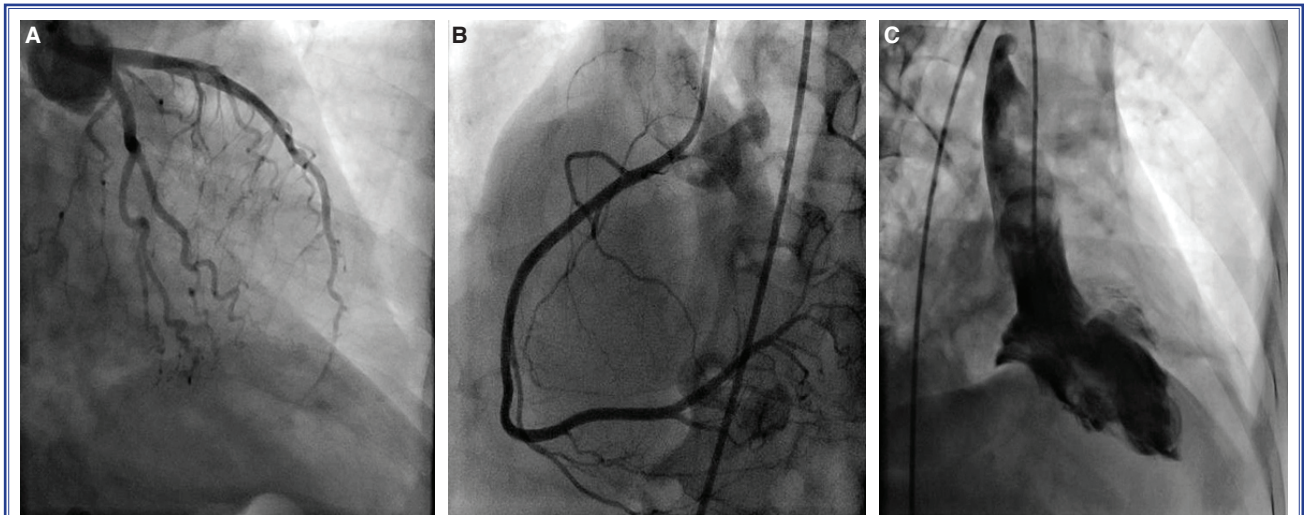


Figure 2. (A, B) Normal coronary arteries, (C) left ventriculography and ascending aortography.

DISCUSSION

ECG alterations and cardiac enzyme elevation have been reported in patients with cerebrovascular events in various studies.^[1,2] SAH has been reported as the most commonly encountered cause, followed by cranial trauma, meningitis and cranial tumors as less common reasons.^[3,4] The most prevalent ECG changes are nonspecific ST segment deviation, T wave inversion and QT interval prolongation.^[5,6] ST segment elevation is extremely rare. Diffuse ST segment elevation without indicating any coronary artery territory may be a non-ischemic ECG finding.

Hypotension, pulmonary edema and systolic dysfunction may be seen in SAH patients. Moreover, troponin levels may be elevated following cerebral ischemia.^[7,8] The unfavorable effect of cranial hemorrhage on the myocardium and coronary arteries is not well-established, albeit that the very high levels of catecholamines released during cerebral hemorrhages may lead to coronary vasoconstriction or direct toxic effect on myocardial cells, ultimately resulting in myocardial damage.^[6,7] A possible mechanism for hemodynamic instability in the present case might be that hypotension developed secondary to the cranial hemorrhage, and it impaired the coronary perfusion, and consequently led to myocardial ischemia and caused complete AV block.

The differential diagnosis between STEMI and intracerebral bleeding is vital. Antiaggregant, antico-

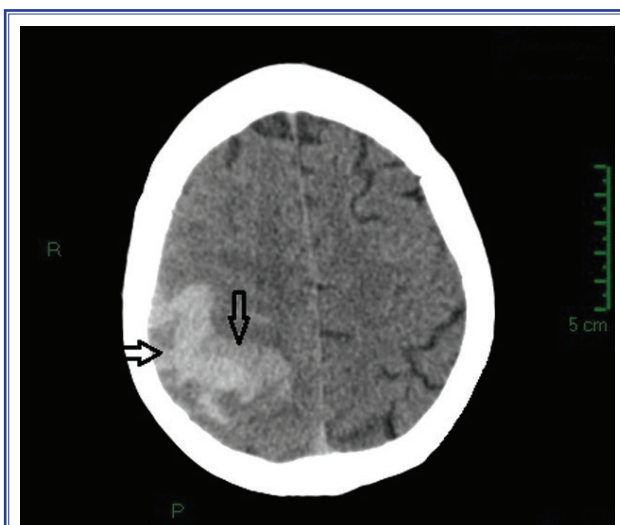


Figure 3. SAH in right parietal lobe and parenchymal hemorrhage measuring 5.2x3.1 cm on CCT.

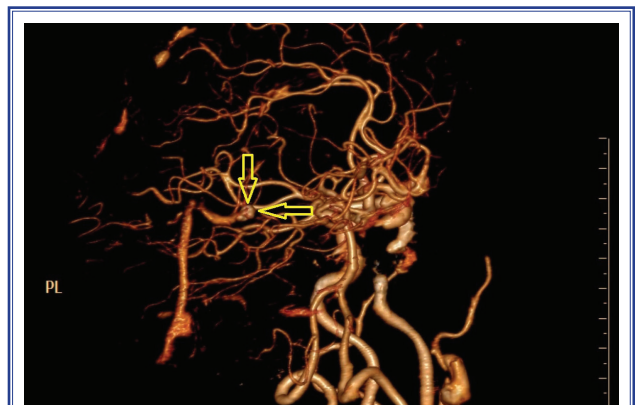

Figure 4. Right posterior communicating artery aneurysm demonstrated by CCT angiography.

agulant and fibrinolytic drugs are essential in STEMI treatment, while these medications are contraindicated in intracerebral hemorrhages. Therefore, coronary angiography is extremely important in the differential diagnosis, especially in unconscious patients without atherosclerotic risk factors and yet with ST elevation on ECG. Intracranial bleeding should also be kept in mind as an alternative diagnosis when coronary angiography demonstrates normal coronary arteries. The diagnosis and etiology of cranial hemorrhage can rapidly be determined in such patients by CCT and CCT angiography.

Probability of cranial hemorrhage should be considered in the absence of a serious lesion on coronary angiography in unconscious patients with ST segment elevation and AV block on ECG.

Conflict-of-interest issues regarding the authorship or article: None declared.

REFERENCES

1. Elrifai AM, Bailes JE, Shih SR, Dianzumba S, Brillman J. Characterization of the cardiac effects of acute subarachnoid hemorrhage in dogs. *Stroke* 1996;27:737–42. [CrossRef](#)
2. Tsuchihashi K, Ueshima K, Uchida T, Oh-mura N, Kimura K, Owa M, et al. Transient left ventricular apical ballooning without coronary artery stenosis: a novel heart syndrome mimicking acute myocardial infarction. Angina Pectoris-Myocardial Infarction Investigations in Japan. *J Am Coll Cardiol* 2001;38:11–8. [CrossRef](#)
3. Burch GE, Meyers R, Abildskov JA. A new electrocardiographic pattern observed in cerebrovascular accidents. *Circulation* 1954;9:719–23. [CrossRef](#)
4. Yamour BJ, Sridharan MR, Rice JF, Flowers NC. Electrocardiographic changes in cerebrovascular hemorrhage. *Am Heart J* 1980;99:294–300. [CrossRef](#)
5. Sommargren CE, Zaroff JG, Banki N, Drew BJ. Electrocardiographic repolarization abnormalities in subarachnoid hemorrhage. *J Electrocardiol* 2002;35 Suppl:257–62. [CrossRef](#)
6. Brouwers PJ, Wijdicks EF, Hasan D, Vermeulen M, Wever EF, Frericks H, et al. Serial electrocardiographic recording in aneurysmal subarachnoid hemorrhage. *Stroke* 1989;20:1162–7. [CrossRef](#)
7. Tung P, Kopelnik A, Banki N, Ong K, Ko N, Lawton MT, et al. Predictors of neurocardiogenic injury after subarachnoid hemorrhage. *Stroke* 2004;35:548–51. [CrossRef](#)
8. Parekh N, Venkatesh B, Cross D, Leditschke A, Atherton J, Miles W, et al. Cardiac troponin I predicts myocardial dysfunction in aneurysmal subarachnoid hemorrhage. *J Am Coll Cardiol* 2000;36:1328–35. [CrossRef](#)

Keywords: Electrocardiography; myocardial infarction; subarachnoid hemorrhage.

Anahtar sözcükler: Elektrokardiyografi; miyokart enfarktüsü; subaraknoid kanama.