

Multimodality imaging of a giant caseous calcification of the mitral annulus

Mitral halkasındaki büyük bir kazeöz kalsifikasyonun değişik yöntemlerle görüntülenmesi

Suzan Hatipoğlu Akpınar, M.D., Ruken Bengi Bakal, M.D.,
Ahmet Güler, M.D., Nihal Özdemir, M.D.

Department of Cardiology, Kartal Kosuyolu Heart Training and Research Hospital, Istanbul

Summary– We present an unusual case of giant caseous calcification of the mitral annulus in a 58-year-old female patient. The mass was detected during echocardiography and was defined as a big, round echodense lesion attached to the posterior mitral ring annulus. The patient was further evaluated with a full spectrum of cardiac noninvasive imaging modalities and the diagnosis was confirmed. Caseous calcification of the mitral annulus is a rare entity usually diagnosed by transthoracic echocardiography. Since it is very important to differentiate it from cardiac tumors, complementary imaging modalities could be used for this purpose if a doubt exists about the diagnosis.

Caseous calcification of the mitral annulus (CCMA) is a rare entity that is seen in 0.067% of echocardiographic studies.^[1] It is usually asymptomatic and diagnosed incidentally during echocardiographic examination or CT study; however there are some rare cases causing valvular dysfunction.^[2] Additionally there are a few cases reporting CCMA as a source of cardiac emboli.^[3]

CASE REPORT

A 58-year-old hypertensive female patient was referred for cardiac evaluation because of recent left retinal emboli. Her ECG revealed normal sinus rhythm. Neurologic and physical examinations were normal except for an apical 3/6 systolic murmur. Transthoracic echocardiography was performed and a round, well-circumscribed, echodense mass (2.9 x 3.1

Özet– Bu yazıda, 58 yaşında bir kadın hastada mitral halkasının alışılmışın dışında bir büyüklükteki kazeöz kalsifikasyonu olgusu sunuldu. Kitle ekokardiyografik inceleme sırasında tespit edildi ve mitral arka halkasına tutunmuş büyük (2.9 x 3.1 cm), yuvarlak, yüksek ekojeniteli bir lezyon olarak tanımlandı. Hasta ileri kardiyak girişimsel olmayan görüntüleme yöntemleri ile değerlendirildi ve tanı kesinleştirildi. Mitral halkasının kazeöz kalsifikasyonu nadir görülen ve genelde tanısı transtorasik ekokardiyografi ile konulabilen bir durumdur. Kardiyak tümörlerden ayrımı çok önemli olduğundan tanı konusunda şüphe varsa tamamlayıcı ileri kardiyak görüntüleme yöntemlerine başvurulabilir.

cm) attached to the basal posterior leaflet and lateral mitral annulus was detected (Fig. 1a and Video

1*). Restricted motion of the posterior leaflet and the mass effect caused mild degree of mitral stenosis and moderate mitral regurgitation. Afterwards 2D and 3D transesophageal echocardiography (TEE) was performed to better delineate the mass and mitral valvular structure (Fig. 1b-d and Video 2, 3*). A mass arising from the posterior mitral valve annulus which was adherent to the P2 scallop and in close proximity to the left atrioventricular groove was confirmed. TEE did not show any thrombus or relevant spontaneous echo-contrast in left atrium, in atrial appendage, and in close proximity to the well-circumscribed mass.

Abbreviations:

CCMA Calcification of the mitral annulus
CMR Cardiac magnetic resonance
CT Computed tomography
TEE Transesophageal echocardiography

Received: June 19, 2012 Accepted: August 31, 2012

Correspondence: Dr. Suzan Hatipoğlu Akpınar. Barbaros Mah., Baskan Sok., No: 14-3, Üsküdar, İstanbul.

Tel: +90 216 - 651 93 14 e-mail: suzan_hatipoglu@hotmail.com

© 2013 Turkish Society of Cardiology



Color Doppler study of the carotid arterial system demonstrated an atherosclerotic plaque and mild stenosis in left internal carotid artery.

The diagnosis was thought to be CCMA, however, the size of the mass was very unusual for a caseous calcification so we proceeded with further imaging, to be able to exclude a calcified myxoma or other calcified cardiac tumors that could mimic the same echocardiographic images. Cardiac magnetic resonance (CMR) imaging showed a 3x3x4 cm nodular hypointense lesion on both T1 and T2-weighted images on posterior mitral valve leaflet, which was laterally attached to the myocardium at basal segments. These findings were compatible with calcification; additionally there was no contrast enhancement in the first pass perfusion images after intravenous gadolinium administration suggesting an avascular nature (Fig. 1e). Late gadolinium-enhancement images showed millimetric, peripheral linear rim of enhancement consistent with a dense calcified fibrotic cap

surrounding the mass. Computed tomography (CT) imaging also demonstrated dense nodular calcifications at the same location (Fig. 1f) and these findings were consistent with CCMA. Since the definite origin of retinal emboli was unclear, we decided to initiate medical management for the patient considering that CCMA is a benign lesion and the patient was asymptomatic.

DISCUSSION

Because our case had concomitant carotid artery lesion that was ipsilateral to the retinal emboli and we could not demonstrate any thrombus related to the mass; the definite cause of the retinal emboli was unclear. The unusual echocardiographic findings presented in this case can cause a diagnostic dilemma and differential diagnosis of CCMA should include calcified cardiac tumors and myocardial abscesses. Usually echocardiographic images of CCMA are very characteristic and echocardiography alone is enough

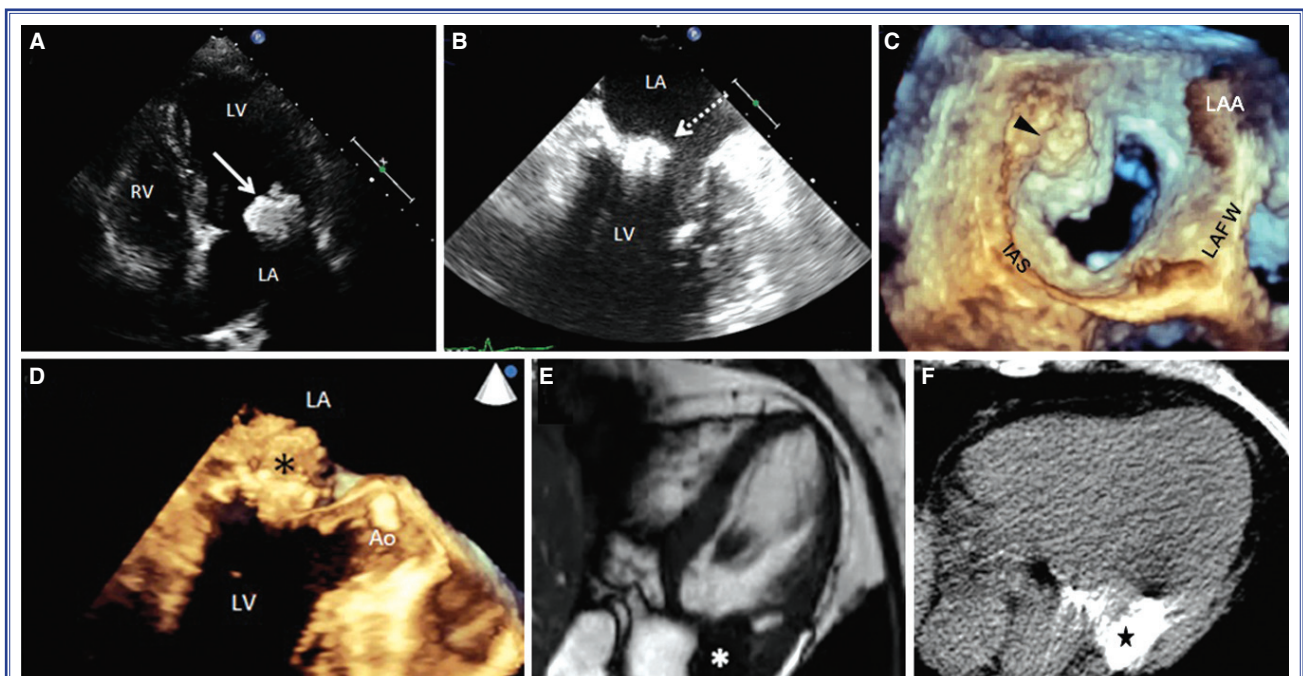


Figure 1. (A) Transthoracic apical 4-chamber view showing mitral annular echodense 2.9 x 3.1 cm mass (arrow) with central echolucent areas attached to the posterior leaflet restricting its motion. (B) 2D transesophageal echocardiographic image of the mitral annular mass (dotted arrow). (C) 3D transesophageal echocardiographic LA view of a heterogeneous mass (arrowhead) attached to the P2 scallop of the mitral valve annulus. Note that the leaflet was retracted by the mass. (D) Well-circumscribed mass (black asterisk) firmly attached to the basal posterior leaflet seen on 3D TEE. (E) Cardiac magnetic resonance images of the hypo-intense mass lesion (white asterisk) on both T1 and T2-weighted images. (F) Computed tomography images demonstrate a mass (star) with nodular calcifications at the base of the posterior mitral valve leaflet. There are small areas consisting of non-calcified material within the mass. LA: Left atrium; LV: Left ventricle; RV: Right ventricle; IAS: Interatrial septum; LAFW: Left atrial free wall; LAA: Left atrial appendage; Ao: Aorta.

for the diagnosis but if there is a doubt CMR or CT should be performed to confirm the diagnosis.^[4,5] CCMA is a benign condition and surgery should be reserved for symptomatic cases with severe valvular dysfunction or patients with cerebral emboli related to the calcified lesion.

In conclusion, CCMA is to be considered in the differential diagnosis of calcified mitral annular masses. CMR or CT scan can help to further identify this benign condition that usually does not necessitate surgical intervention, consequently, differentiation from cardiac tumors is important.

Conflict-of-interest issues regarding the authorship or article: None declared.

***Supplementary video files associated with this article can be found in the online version of the journal.**

REFERENCES

1. Harpaz D, Auerbach I, Vered Z, Motro M, Tobar A, Rosenblatt S. Caseous calcification of the mitral annulus: a neglected, unrecognized diagnosis. *J Am Soc Echocardiogr* 2001;14:825-31. [\[CrossRef\]](#)
2. Deluca G, Correale M, Ieva R, Del Salvatore B, Gramenzi S, Di Biase M. The incidence and clinical course of caseous calcification of the mitral annulus: a prospective echocardiographic study. *J Am Soc Echocardiogr* 2008;21:828-33. [\[CrossRef\]](#)
3. Chevalier B, Reant P, Laffite S, Barandon L. Spontaneous fistulization of a caseous calcification of the mitral annulus: an exceptional cause of stroke. *Eur J Cardiothorac Surg* 2011;39:184-5. [\[CrossRef\]](#)
4. Shriki J, Rongey C, Ghosh B, Daneshvar S, Colletti PM, Farvid A, et al. Caseous mitral annular calcifications: Multimodality imaging characteristics. *World J Radiol* 2010;2:143-7.
5. Türk UO, Alioglu E, Tengiz I, Ercan E. Atypical mitral annular calcification mimicking an intracardiac tumor. *Türk Kardiyol Dern Ars* 2007;35:427-9.

Key words: Calcinosis; heart valve diseases; magnetic resonance imaging; mitral valve/pathology.

Anahtar sözcükler: Kalsinoz; kalp kapağı hastalığı; manyetik rezonans görüntüleme; mitral kapağı/patoloji.