

Epileptic seizures secondary to high degree atrioventricular block without escape rhythm

Kaçış ritmi olmayan yüksek dereceli atriyoventriküler bloğa bağlı gelişen epileptik nöbet

İrfan Şahin, M.D., Ahmet Karabulut, M.D.,# Fatih Kızıkan, M.D., Ertuğrul Okuyan, M.D.

Department of Cardiology, Bağcılar Training and Research Hospital, Istanbul;

#Department of Cardiology, Istanbul Medicine Hospital, Istanbul

Summary– Differentiation between cardiac and neurological origin of syncope may be challenging. Prolonged cerebral hypoxia secondary to cardiac arrhythmias may lead to epileptic seizures. Moreover, partial epileptic seizures by themselves can trigger cardiac arrhythmias. Herein, we present a case of partial epileptic seizure occurring just after complete atrioventricular block has occurred. The diagnosis was established with simultaneous electroencephalographic and electrocardiographic recordings.

Özet– Senkopun kalp veya nöroloji kaynaklı olduğunun ayırımı zor olabilmektedir. Kardiyak aritmilere bağlı ikincil gelişen uzamış serebral hipoksi epileptik nöbetlere yol açabilir. Üstelik kısmi epileptik nöbetlerin kendisi kardiyak aritmileri tetikleyebilir. Bu yazıda, tam atriyoventriküler blokten hemen sonra gelişen kısmi epileptik nöbetli bir olgu sunuldu. Tanı eşzamanlı elektroensefalografi ve elektrokardiyografi kayıtları ile konuldu.

Epilepsy is a condition of chronic, recurrent seizures that occur because of brain hyperexcitability. Epileptic seizures and syncope have common presenting features that make it difficult to determine if a patient's collapse is primarily cardiac or neurological in origin.^[1] It is proposed that cardiac arrhythmias may trigger an epileptic seizure in the setting of prolonged cerebral hypoxia.^[2-4]

Herein, we present a case of epileptic seizure triggered by high degree atrioventricular (AV) block without escape rhythm. We demonstrated onset of epileptic seizures in a few seconds after an episode of high-grade AV block by simultaneous electrocardiographic (ECG) and electroencephalographic (EEG) recordings.

CASE REPORT

An 83-year-old male patient presented to the neurology out-patient clinic with complaints of recurrent

syncope accompanying convulsive attacks. The patient was followed up in the neurology out-patient clinic with a diagnosis of epilepsy. However, symptoms persisted despite anti-epileptic treatment. The patient did not define any cardiovascular diseases including hypertension and stroke and did not use any medication. A physical examination of the patient, including auscultation of the bilateral carotid arteries, was unremarkable. The laboratory panel was normal including complete blood count, cardiac biomarkers, sodium, potassium levels and thyroid function tests. The ECG of the patient showed sinus rhythm without ischemic ST/T changes and with normal PR and QT intervals. Transthoracic echocardiography revealed normal left ventricle systolic function, degenerative aortic and mitral valves with mild mitral and aortic valve insufficiency. Cranial computed tomography and magnetic resonance

Abbreviations:

AV	Atrioventricular
ECG	Electrocardiographic
EEG	Electroencephalographic
MRI	Magnetic resonance imaging

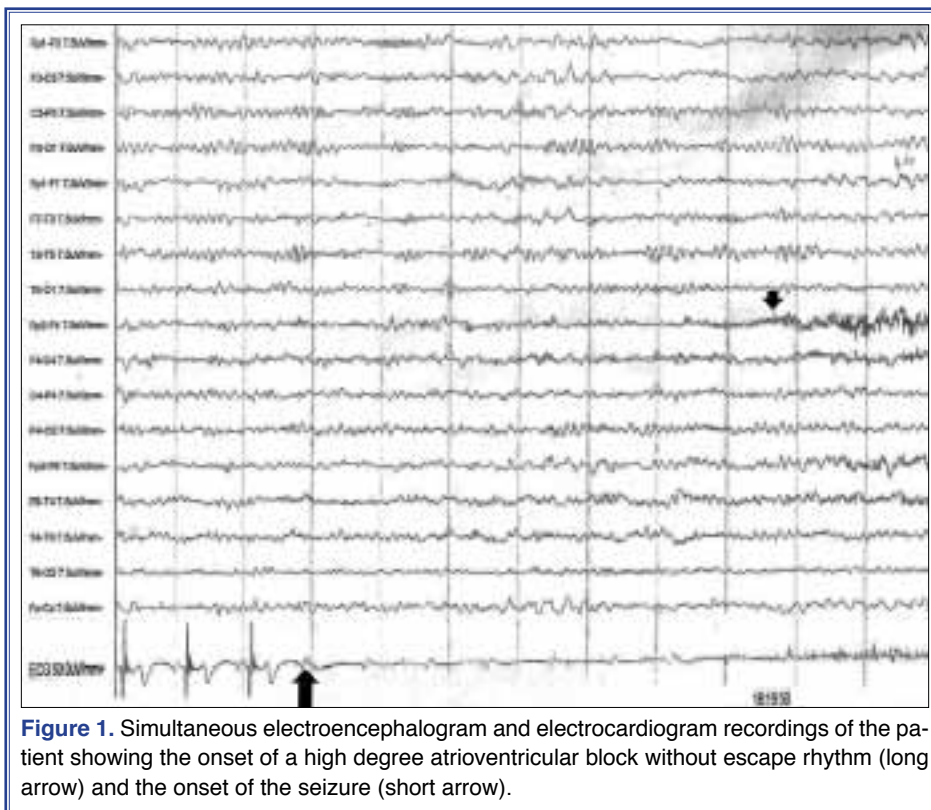
Received: February 18, 2014 Accepted: June 04, 2014

Correspondence: Dr. İrfan Şahin. Bağcılar Eğitim ve Araştırma Hastanesi, Kardiyoloji Kliniği, İstanbul.

Tel: +90 212 - 440 40 00 e-mail: medirfansahin@gmail.com

© 2014 Turkish Society of Cardiology





imaging (MRI) studies were subsequently performed, and both revealed senile cortical atrophy. Acute cerebrovascular accident was excluded by a diffusion cranial MRI study. After that, an EEG was performed, which showed normal cerebral function without hyperexcitability, and during which a high grade AV block without escape beats, which persisted for 22 s was observed incidentally (Figure 1). Seven seconds after the onset of the AV block, complex partial seizures originating from the left frontal lobe lasting 30 s were observed. Fifteen seconds after sinus rhythm was restored, the patient recovered with mild postictal confusion. After consultation between the departments of neurology and cardiology, epileptic seizures were accepted as having occurred secondary to cardiac conduction abnormality, and a permanent VVI pacemaker was implanted. The patient was discharged without any anti-epileptic medications and during a follow-up of 6 months the patient remained asymptomatic, with normal control EEG examination.

DISCUSSION

SSinus tachycardia are observed in most cases with epileptic seizures, mainly due to sympathetic dis-

charge.^[5] Bradyarrhythmias are less commonly seen, but recognition of such arrhythmias is important because of potential serious clinical implications, including sudden cardiac death.^[6,7] Actually, it is very difficult to differentiate between epileptic seizures originating from neurological and cardiac causes, especially if associated with bradyarrhythmias.^[8,9] It was proposed that partial epileptic seizures could disrupt normal cardiac rhythm and lead to bradycardia, AV block or even asystole.^[10]

Cardiogenic syncope-associated convulsion may be misdiagnosed as epilepsy because of its similarity in clinical presentation.^[2,7-9,11,12] Cardiogenic convulsions last only a few seconds, with an abrupt return of consciousness. Postictal confusion does not proceed, and it would not be triggered with provocative maneuvers.^[7] Rather than typical epileptic seizures, myoclonic jerks are usually observed, in such patients. Prolongation of cerebral hypoxia may lead to epileptic seizures.^[2-4] Reported data in the literature are debatable, even though some authors speculated that epileptic activity in the deeper structures could trigger bradyarrhythmias, and such activity could be overlooked with standard scalp EEG study.^[5]

In our case, even though seizures were secondary to cardiac abnormality, clinical presentation was compatible with cerebral seizures. Simultaneous EEG and ECG recording may be very useful in the differential diagnosis, as it was in our case.^[5,12,13]

Convulsive syncope and epileptic seizures have common clinical findings which make it difficult to determine the origin of the disease. Cardiac diseases, especially bradyarrhythmias, should be investigated in detail, especially in cases with advanced age and symptoms resistant to medical therapy.

Conflict-of-interest issues regarding the authorship or article: None declared.

REFERENCES

1. Kouakam C, Daems C, Guédon-Moreau L, Delval A, Lacroix D, Derambure P, et al. Recurrent unexplained syncope may have a cerebral origin: report of 10 cases of arrhythmogenic epilepsy. *Arch Cardiovasc Dis* 2009;102:397-407. [CrossRef](#)
2. Patel SJ, Jackson G, Marshall A. Convulsive syncope in young adults: think of a cardiac cause. *Int J Clin Pract* 2001;55:639-40.
3. Chavda KK, Dhuper S, Madhok A, Chowdhury D. Seizures secondary to a high-grade atrioventricular block as a presentation of acute myocarditis. *Pediatr Emerg Care* 2004;20:387-90. [CrossRef](#)
4. Jeon JH, Her SH, Chin JY, Park KH, Yoon HJ, Lee JM, et al. Complete atrioventricular block-induced Torsade de pointes, manifested by epilepsy. *Korean J Intern Med* 2011;26:99-102.
5. Wilder-Smith E. Complete atrio-ventricular conduction block during complex partial seizure. *J Neurol Neurosurg Psychiatry* 1992;55:734-6. [CrossRef](#)
6. Carinci V, Barbato G, Baldrati A, Di Pasquale G. Asystole induced by partial seizures: a rare cause of syncope. *Pacing Clin Electrophysiol* 2007;30:1416-9. [CrossRef](#)
7. You CF, Chong CF, Wang TL, Hung TY, Chen CC. Unrecognized paroxysmal ventricular standstill masquerading as epilepsy: a Stokes-Adams attack. *Epileptic Disord* 2007;9:179-81.
8. Zarraga IG, Ware DL. Syncope, seizure, or both? An unusual case of complete heart block. *J Electrocardiol* 2007;40:493-5.
9. Pfammatter JP, Donati F, Dürig P, Weber JW, Stocker FP, Vassella F. Cardiac arrhythmias mimicking primary neurological disorders: a difficult diagnostic situation. *Acta Paediatr* 1995;84:569-72. [CrossRef](#)
10. Devinsky O, Pacia S, Tatambhotla G. Bradycardia and asystole induced by partial seizures: a case report and literature review. *Neurology* 1997;48:1712-4. [CrossRef](#)
11. Altenmüller DM, Zehender M, Schulze-Bonhage A. High-grade atrioventricular block triggered by spontaneous and stimulation-induced epileptic activity in the left temporal lobe. *Epilepsia* 2004;45:1640-4. [CrossRef](#)
12. Brenner RP. Electroencephalography in syncope. *J Clin Neurophysiol* 1997;14:197-209. [CrossRef](#)
13. Rocamora R, Kurthen M, Lickfett L, Von Oertzen J, Elger CE. Cardiac asystole in epilepsy: clinical and neurophysiologic features. *Epilepsia* 2003;44:179-85. [CrossRef](#)

Key words: Atrioventricular block; epilepsy; seizure.

Anahtar sözcükler: Atriyoventriküler blok; epilepsie; nöbet.