

Görüntülü olgu örnekleri

Case images

**An unusual cause of implantable cardioverter defibrillator malfunction:
Twiddler syndrome**

*Yerleştirilebilir kardiyoverter defibrilatör arızasının nadir bir nedeni:
Twiddler sendromu*

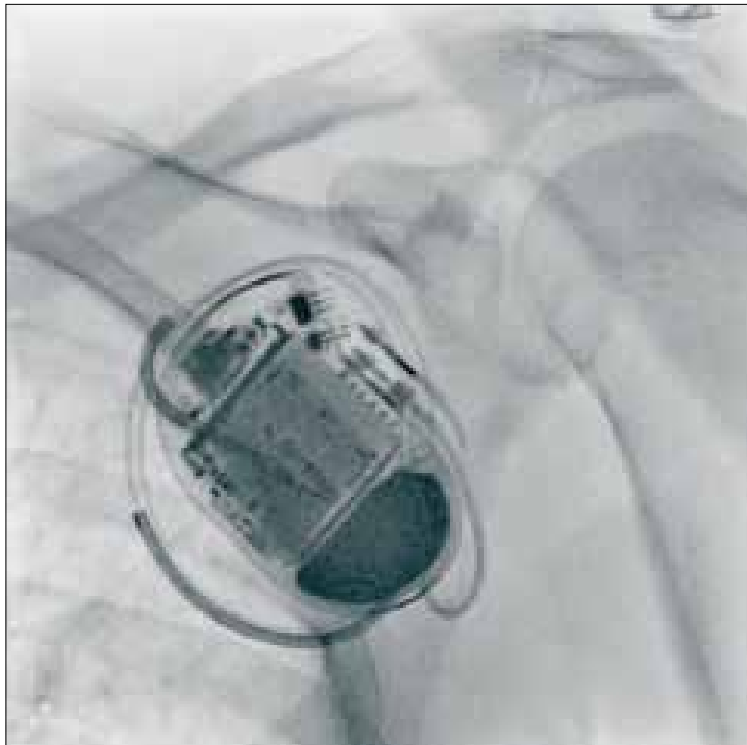
Ufuk Eryılmaz

Hasan Güngör

Çağdaş Akgüllü

Department of Cardiology,
Adnan Menderes University Faculty of
Medicine, Aydın

A 60-year-old man with ischemic cardiomyopathy received a single-chamber implantable cardioverter defibrillator (ICD) after cardiac arrest. Approximately one month after implantation, the patient was referred to the emergency room with pectoral muscle stimulation. Chest radiography showed the ventricular lead encircling the generator (Figure). He was discharged from the hospital after pocket revision and new ICD lead implantation.



Figure– Ventricular lead encircling the generator.

