

Ablation of epicardial premature ventricular contractions in a patient with ischemic cardiomyopathy and implementation of cardiac resynchronization therapy in the same procedure

İskemik kardiyomyopatili hastada epikardiyal ventriküler ekstrasistol ablasyonu ve aynı işlemde kardiyak resenkronizasyon tedavi uygulaması

Veysel Kutay Vurgun, M.D., Başar Candemir, M.D., Ali Timuçin Altın, M.D., Ömer Akyürek, M.D.

Department of Cardiology, Ankara University Faculty of Medicine, Ankara, Turkey

Summary– Premature ventricular contractions (PVCs) can cause clinical deterioration in patients with heart failure and increase the frequency of shocks delivered by an implantable cardioverter defibrillator (ICD). Epicardial PVC/ventricular tachycardia (VT) is seen less often in ischemic cardiomyopathy. Radiofrequency catheter ablation is the most effective treatment option for the management of PVC/VT and can improve cardiac function. Presently described is a patient with ischemic cardiomyopathy and frequent PVCs and VT runs with multiple ICD therapies who was treated with simultaneous radiofrequency catheter ablation in the anterior interventricular vein and cardiac resynchronization therapy defibrillator upgrade in the same procedure.

Özet– Ventriküler ekstrasistoller (VES) kalp yetersizliğinde kötüleşmeye ve implante edilebilen kardiyoverter defibrilatör (ICD) şoku sıklığında artışa neden olabilmektedirler. Epikardiyal VES'ler iskemik kardiyomyopatide daha az sıklıkla gözlenmektedir. VES tedavisinde radyofrekans kateter ablasyonu en etkili tedavi yöntemidir ve kalp fonksiyonlarında düzelme sağlayabilmektedir. Bu yazıda sunulan iskemik kardiyomyopatili, sık VES/ventriküler taşikardi atakları nedeniyle sık ICD şoku olan hastada, ön interventriküler ven içinden epikardiyal VES ablasyonu ve aynı işlemde kardiyak resenkronizasyon tedavisine yükseltme işlemi sunulmuştur.

Premature ventricular contractions (PVCs) can deteriorate heart failure status and increase appropriate implantable cardioverter defibrillator (ICD) therapies.^[1] Epicardial PVC/ventricular tachycardia (VT) is more common in non-ischemic cardiomyopathy than ischemic cardiomyopathy.^[2] Radiofrequency catheter ablation (RFCA) is a curative treatment option for PVC/VT and can improve cardiac function.^[3,4]

Abbreviations:

AIV	Anterior interventricular vein
CRT-D	Cardiac resynchronization therapy defibrillator
CS	Coronary sinus
ECG	Electrocardiogram
GCV	Great cardiac vein
ICD	Implantable cardioverter defibrillator
LV	Left ventricle
NYHA	New York Heart Association
PVC	Premature ventricular contraction
RFCA	Radiofrequency catheter ablation
VT	Ventricular tachycardia

This report describes the case of a patient with ischemic cardiomyopathy who had multiple appropriate ICD therapies and was treated with RFCA in the anterior interventricular vein and a cardiac resynchronization therapy defibrillator (CRT-D) upgrade in the same procedure.

CASE REPORT

A 60-year-old male was referred to the clinic for frequent PVCs and appropriate ICD shocks. He had a history of congestive heart failure (CHF) (New York Heart Association [NYHA] Class III-IV), coronary artery bypass grafting operation, and a prior DDD-ICD implantation for primary prevention 4 years earlier. He had been doing well until he received 6 ICD shocks in the 3 weeks prior to presentation, and 2 re-

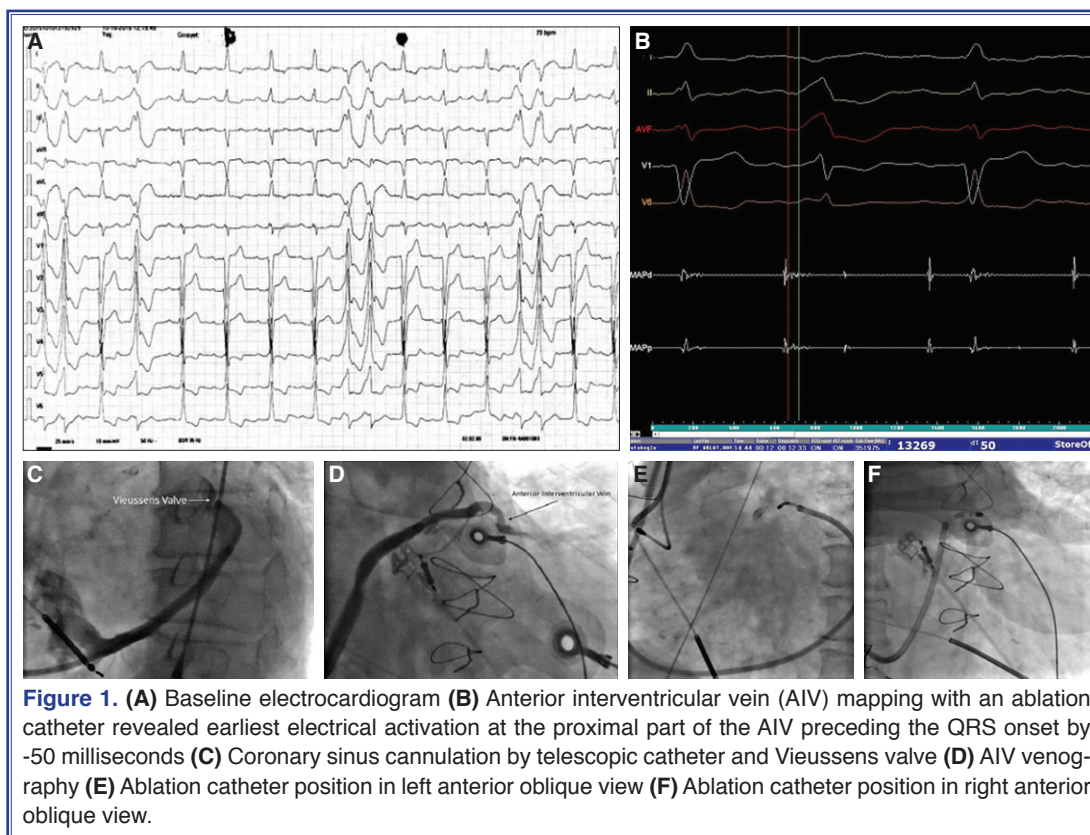
Received: January 02, 2017 Accepted: March 13, 2017

Correspondence: Dr. Veysel Kutay Vurgun. Ankara Üniversitesi Tıp Fakültesi, Cebeci Kalp Merkezi, 3. Kat, Kardiyoloji Anabilim Dalı, Dikimevi, 06590 Ankara, Turkey.

Tel: +90 312 - 595 62 86 e-mail: kutayvurgun@gmail.com

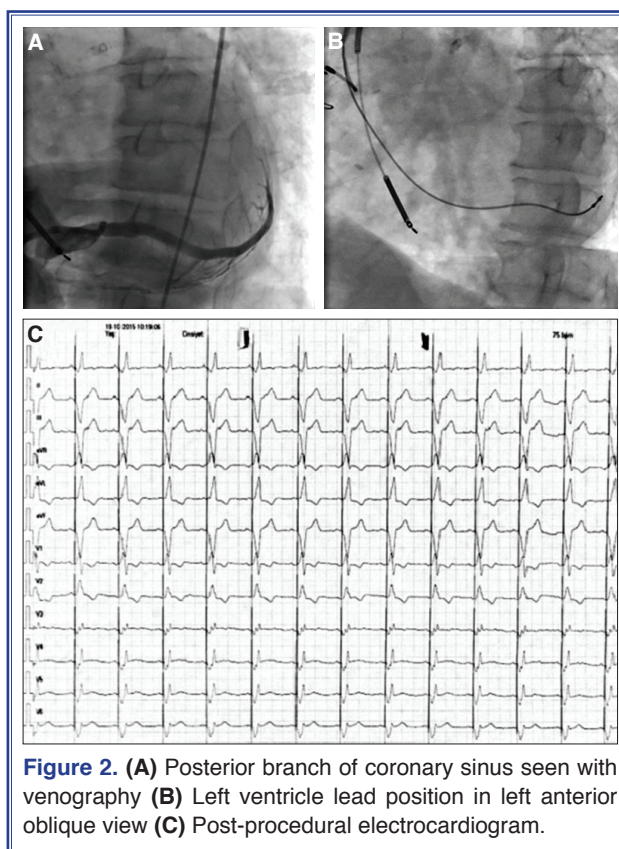
© 2017 Turkish Society of Cardiology





cent hospitalizations for episodes of decompensated heart failure. His medications included amiodarone, spironolactone, ramipril, atorvastatin, clopidogrel, and carvedilol. He had undergone 2 failed electroanatomic endocardial ablation attempts at another clinic 6 months earlier, during which the surgeons reportedly could not achieve successful endocardial ablation and could not pass distal to the great cardiac vein (GCV) due to a well-developed Vieussens valve.

Transthoracic echocardiography revealed depressed left ventricle (LV) systolic function (LV ejection fraction: 10%). An electrocardiogram (ECG) revealed nonspecific intraventricular conduction delay (QRSd=140 milliseconds) and frequent PVCs/couplets exhibiting a right bundle branch block and inferior axis QRS morphology. The PVCs had a pseudo-delta wave, and the precordial maximum deflection index was 0.70 milliseconds (>0.55 milliseconds), which suggested epicardial origin (Figure 1a). There were 24,200 (23%) single PVCs and 1118 couplets on the 24-hour Holter ECG monitoring report. RFCA treatment of the PVCs through the coronary sinus (CS) and subsequent CRT-D upgrade during the same procedure was planned.



CS cannulation was performed with a CS guiding catheter via a left axillary vein puncture. A circumferentially well-developed Vieussens valve was engaged with a telescopic inner catheter and passed with the help of 0.035" hydrophilic guidewire manipulation to the distal part of the CS (Figure 1c). CS venography was performed to delineate the anterior interventricular vein (AIV) (Figure 1d). AIV mapping with a 5-F ablation catheter revealed earliest electrical activation at the proximal part of the AIV preceding the QRS onset by -50 milliseconds with good 12/12 pacemapping (Figure 1b). Ablation at this site for 60 seconds promptly achieved total suppression of PVCs (Figure 1E and 1f). No PVC was inducible afterwards by right ventricular burst pacing or programmed electrical stimulation under isoproterenol infusion (2-4 $\mu\text{g}/\text{minute}$). A suitable posterior branch of the CS was cannulated with an inner catheter and a LV pacing lead was implanted to the middle segment of this branch (Figure 2a and b). The previous DDD-ICD system was replaced with a CRT-D. The post-procedural ECG result is provided in Figure 2c. His clinical status rapidly improved to NYHA Class II during the postoperative period and he was discharged 5 days later. He improved to NYHA I-II with no palpitations and no re-hospitalization. A Holter recording performed at 6-month visit revealed no VT but 345 multiform PVC.

DISCUSSION

RFCA has clinical benefits to patients with PVCs/VT, such as symptomatic relief and improvement of LV function, especially in patients with frequent PVCs in ischemic cardiomyopathy.^[3] Recent studies arising from electrophysiology laboratories have demonstrated that systolic dysfunction may improve, and even normalize, after successful ablation of high-burden PVCs (generally >10% PVCs).^[5-7] These data suggest that PVCs could be a significant and modifiable risk factor for incident CHF. PVCs can impair quality of life and sometimes require the long-term use of anti-arrhythmic medications, which are often ineffective and may have serious adverse effects.^[8]

RFCA of ventricular arrhythmias via the GCV-AIV may pose difficulties because of the proximity to coronary arteries and the limited capability of radiofrequency energy due to high impedance.^[9] A potential major complication of RFCA delivered to the

GCV is coronary artery injury as a result of the close anatomical relationship.^[10] Other potential problems are the possibility of catheter entrapment in small branches, limited catheter cooling from the surrounding blood flow, and failure to advance the ablation catheter through the GCV to the AIV, which was the case in this patient. Fifteen percent of patients were found to have a well-developed Vieussens valve after the GCV crossed the circumflex artery.^[10] The option of upgrading the CRT-D and postponing ablation of the PVC to another session was dismissed due to possibility of LV lead dislodgement during a subsequent ablation procedure. First, we planned to pass the venous valve and then to ablate the PVCs originating from the AIV. Second, because of the compelling venous valve, we decided to implant the LV lead quickly. In our patient, ventricular arrhythmia causing ICD shocks was idiopathic PVCs arising from the AIV. No endocardial substrate ablation was planned because there was no scar-related ischemic VT. After ablation of the epicardial PVCs, no ventricular arrhythmia was observed. To our knowledge, the present case represents the first case of simultaneous ablation of epicardial PVCs and CRT-D upgrade.

In conclusion, passing the Vieussens valve with the help of a telescopic system was very useful to provide enough catheter support and to demonstrate the Vieussens valve. Therefore, ablation of epicardial PVCs via the CS system and a CRT implantation/upgrade may be a reasonable alternative to a consecutive strategy in a limited number of patients who will eventually require both.

Conflict-of-interest: None declared.

REFERENCES

1. Penela D, Van Huls Van Taxis C, Aguinaga L, Fernández-Armenta J, Mont L, Castel MA, et al. Neurohormonal, structural, and functional recovery pattern after premature ventricular complex ablation is independent of structural heart disease status in patients with depressed left ventricular ejection fraction: a prospective multicenter study. *J Am Coll Cardiol* 2013;62:1195-202. [[CrossRef](#)]
2. Sarkozy A, Tokuda M, Tedrow UB, Sieria J, Michaud GF, Couper GS, et al. Epicardial ablation of ventricular tachycardia in ischemic heart disease. *Circ Arrhythm Electrophysiol* 2013;6:1115-22. [[CrossRef](#)]
3. Sarrazin JF, Labounty T, Kuhne M, Crawford T, Armstrong WF, Desjardins B, et al. Impact of radiofrequency ablation of frequent post-infarction premature ventricular complexes on

- left ventricular ejection fraction. *Heart Rhythm* 2009;6:1543–9. [\[CrossRef\]](#)
4. Lakkireddy D, Di Biase L, Ryschon K, Boria M, Swarup V, Reddy YM, et al. Radiofrequency ablation of premature ventricular ectopy improves the efficacy of cardiac resynchronization therapy in nonresponders. *J Am Coll Cardiol* 2012;60:1531–9. [\[CrossRef\]](#)
 5. Chugh SS, Shen WK, Luria DM, Smith HC. First evidence of premature ventricular complex-induced cardiomyopathy: a potentially reversible cause of heart failure. *J Cardiovasc Electrophysiol* 2000;11:328–9. [\[CrossRef\]](#)
 6. Bogun F, Crawford T, Reich S, Koelling TM, Armstrong W, Good E, et al. Radiofrequency ablation of frequent, idiopathic premature ventricular complexes: comparison with a control group without intervention. *Heart Rhythm* 2007;4:863–7.
 7. Baman TS, Lange DC, Ilg KJ, Gupta SK, Liu TY, Alguire C, et al. Relationship between burden of premature ventricular complexes and left ventricular function. *Heart Rhythm* 2010;7:865–9. [\[CrossRef\]](#)
 8. Akhtar M, Breithardt G, Camm AJ, Coumel P, Janse MJ, Lazzara R, et al. CAST and beyond. Implications of the Cardiac Arrhythmia Suppression Trial. Task Force of the Working Group on Arrhythmias of the European Society of Cardiology. *Circulation* 1990;81:1123–7. [\[CrossRef\]](#)
 9. Baman TS, Ilg KJ, Gupta SK, Good E, Chugh A, Jongnarangsin K, et al. Mapping and ablation of epicardial idiopathic ventricular arrhythmias from within the coronary venous system. *Circ Arrhythm Electrophysiol* 2010;3:274–9. [\[CrossRef\]](#)
 10. El-Maasarany S, Ferrett CG, Firth A, Sheppard M, Henein MY. The coronary sinus conduit function: anatomical study (relationship to adjacent structures). *Europace* 2005;7:475–81. [\[CrossRef\]](#)
-
- Keywords:** Cardiac resynchronization therapy; ischemic cardiomyopathy; premature ventricular contraction; radiofrequency ablation.
- Anahtar sözcükler:** Kardiyak resenkronizasyon tedavisi; iskemik kardiyomyopati; ventriküler ekstrasistol; radyofrekans ablasyon.