

Right atrial appendage thrombus

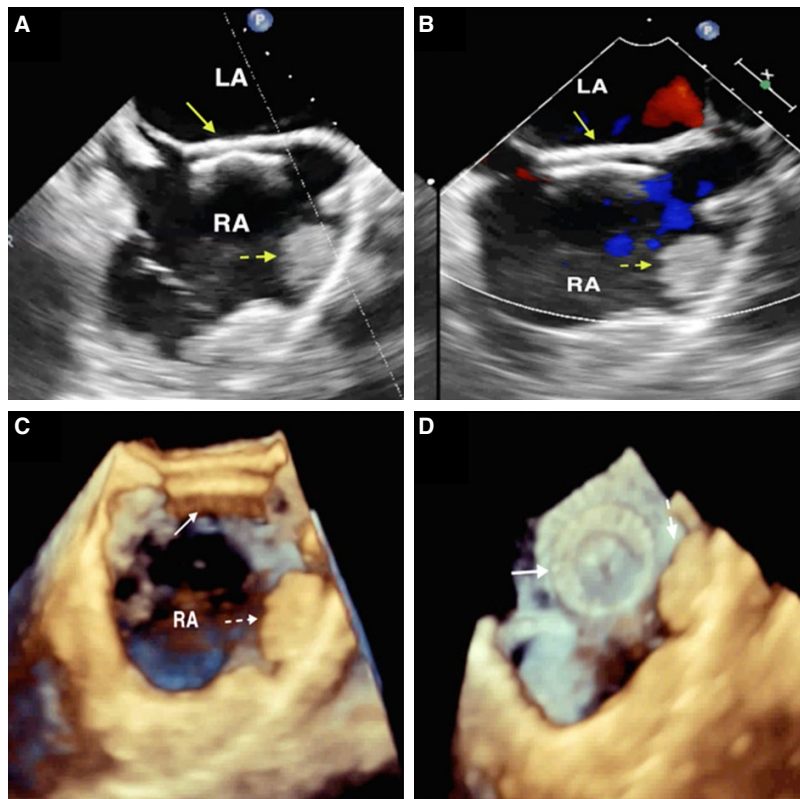
Sağ atriyal apendiks trombüsü

Muzaffer Kahyaoğlu
 Alev Kılıçgedik
 Çetin Geçmen
 Ender Özgün Çakmak
 İbrahim Akın İzgi

Department of Cardiology,
 Kartal Koşuyolu Yüksek İhtisas
 Training and Research
 Hospital, İstanbul, Turkey

A 32-year-old male patient who had undergone the percutaneous closure of a secundum-type atrial septal defect (ASD) with a 20-mm Amplatzer septal occluder (AGA Medical Corp., Plymouth, MN, USA) device 6 months earlier presented at the outpatient clinic for a routine follow-up visit. The physical examination was unremarkable. Electrocardiography showed a normal sinus rhythm. Transthoracic echocardiography demonstrated normal right heart chamber sizes and function and a normal systolic pulmonary artery pressure, but a suspicious flow was observed on color Dop-

pler. Two-dimensional (2D) and 3D transesophageal echocardiography (TEE) at the mid-esophageal level in bicaval view revealed that while the ASD closure device was intact at the interatrial septum, without any left-to-right shunt (Figures A–D), there was a huge right atrial appendage (RAA) thrombus, 1.7x2.4 cm in size (Figures A–D). Medical management was planned and he has been anticoagulated with warfarin and enoxaparin sodium. RAA thrombus is a rare finding, compared with the left-sided chambers. Atrial fibrillation, right ventricular failure, and pulmonary hypertension are known as risk factors for the development of RAA thrombi. RAA thrombus may also occur in patients with normal right ventricular function and normal sinus rhythm, as in this case, however, an association between ASD closure device implantation and the occurrence of RAA thrombus cannot be excluded.



Figures– (A) Mid-esophageal level bicaval view showing the closure device at the interatrial septum (arrow) and the right atrial appendage thrombus (dotted arrow). **(B)** Mid-esophageal level bicaval color Doppler image demonstrating no shunt between right and left atrium. **(C and D)** Three-dimensional transesophageal echocardiography image showing the closure device (arrow) and a right atrial appendage thrombus (dotted arrow).