

A rare case of aortic dissection; prolapse of flap into the ventricle

Ender rastlanan aort diseksiyonu olgusu: Ventrikül içine prolabe olan flep

Kadriye Gayretli Yayla

Sadık Açıklı

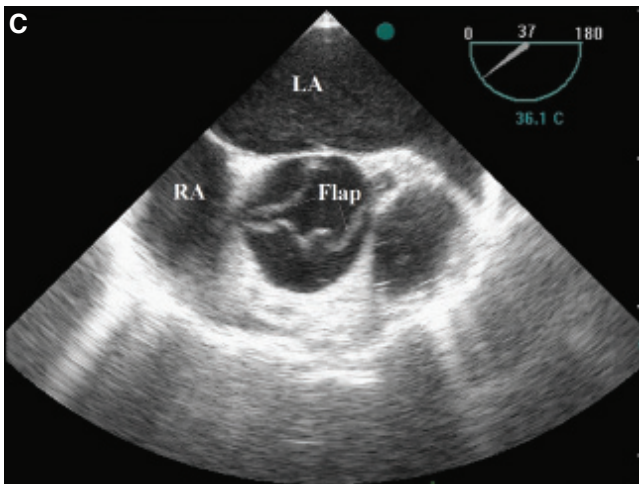
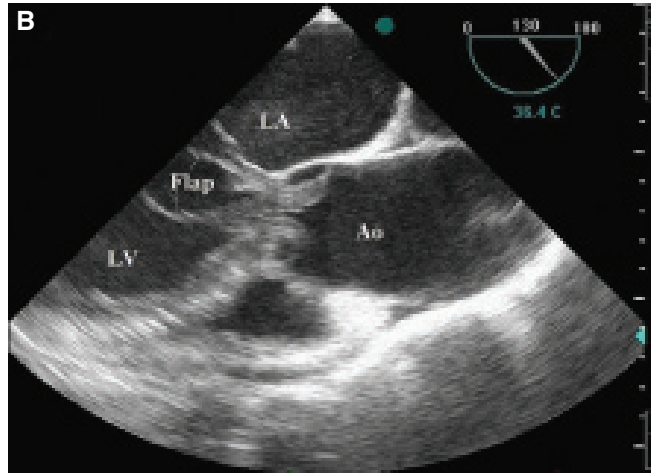
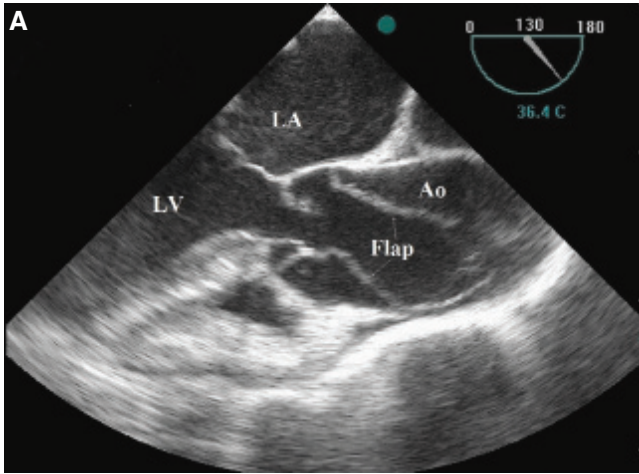
Çağrı Yayla#

Ekrem Yeter

Department of Cardiology,
Diskapi Yildirim Beyazıt
Training and Research Hospital,
Ankara;

#Department of Cardiology,
Gazi University Faculty of Medicine,
Ankara

A 74-year-old male who had been treated for hypertension was admitted to the emergency department with chest pain of four hours' duration radiating to his back. Electrocardiogram showed ST segment depression in antero-lateral and inferior leads. Blood pressure was 85/55 mmHg and heart rate 105 bpm. Minimal (grade 2/6) decrescendo diastolic murmur was audible on the left sternal edge. Emergency two-dimensional echocardiography showed severe ascending aortic dissection with an intimal flap prolapsing into the left ventricle despite normal left ventricle size and systolic function. Transesophageal echocardiography demonstrated circumferential intimal disruption that started just above the aortic root and extended distally through the aortic arch and into the carotid artery. The circumferential intimal flap was prolapsing into the left ventricle during the diastolic phase, causing severe aortic regurgitation and resulting in diastolic occlusion of both coronary arterial ostia (Figures A, B, C, Videos 1, 2*). The patient underwent a combined coronary artery bypass grafting and replacement of the aortic valve, ascending aorta and aortic arch.



Figures– (A) Transesophageal echocardiography midesophageal aortic valve long-axis view of type A aortic dissection: the intimal flap is seen prolapsing into the aortic root during systole. **(B)** Transesophageal echocardiography midesophageal aortic valve long-axis view of type A aortic dissection: the intimal flap is seen prolapsing into the left ventricle during diastole. **(C)** Transesophageal echocardiography midesophageal aortic valve short-axis view showing the intimal flap. LA: Left atrium; LV: Left ventricle; Ao: Aorta; RA: Right atrium. *Supplementary video files associated with this presentation can be found in the online version of the journal.

