

Recurrent pacemaker lead thrombosis in a patient with gene polymorphism: a rare case treated with thrombolytic therapy

Gen polimorfizmi olan bir hastada tekrarlayan pacemaker elektrodu trombüsü: Trombolitik ilaçla tedavi edilen nadir bir olgu

S. Selim Ayhan, M.D., Serkan Öztürk, M.D., Mehmet Fatih Özlü, M.D., Selma Düzenli, M.D.#

Departments of Cardiology, #Medical Biology and Genetics, Abant İzzet Baysal University Faculty of Medicine, Bolu

Summary– Pacemaker (PM)-related thrombosis is an infrequent complication of pacing. We present the case of a 58-year-old man with heart failure and atrial fibrillation who had recurrent episodes of PM lead thrombosis while undergoing anticoagulation therapy. The patient was admitted to the hospital with complaints of dyspnea and palpitation. Echocardiography revealed normal right ventricular dimensions and an enlarged left ventricle with poor contractility and an ejection fraction of 20%. Transesophageal echocardiography demonstrated a large, mobile thrombus in the right atrium that was attached to the PM lead. The patient was successfully treated with a thrombolytic agent. Genetic tests revealed that the patient was a heterozygous carrier of the methylenetetrahydrofolate reductase (MTHFR) gene mutation.

Özet– Pacemaker (PM) ile ilişkili trombüs, PM implantasyonun nadir görülen komplikasyonlarından biridir. Bu yazıda, kalp yetersizliği ve atriyum fibrilasyonu tanılarıyla takip edilen ve antikoagülan tedavi altındayken tekrarlayan PM elektrodu trombüsü gelişen 58 yaşında erkek hasta sunuldu. Nefes darlığı ve çarpıntı şikayeti ile hastaneye kabul edilen hastanın ekokardiyografisinde genişlemiş ve kasılması azalmış sol ventrikül (EF %20) ile normal sınırlarda sağ ventrikül görüldü. Ayrıca PM elektroduna tutunan sağ atriyum trombüsü saptandı. Transözefajiyal ekokardiyografi incelemesinde, sağ atriyumda PM elektroduna tutunan büyük ve hareketli trombüs gösterildi. Hasta, trombolitik ajan ile başarılı olarak tedavi edildi. Genetik testlerde hastanın heterozigot metilentetrahidrofolat redüktaz (MTHFR) taşıyıcısı olduğu saptandı.

Pacemaker (PM) leads are known to be predisposing factors for thrombosis.^[1,2] PM lead thrombosis is a rare but potentially fatal event. It is usually diagnosed as a coincidental echocardiographic finding and may be associated with serious complications such as pulmonary artery embolism and stroke.^[3,4]

Here, we report a rare case of a 58-year-old man with a heterozygous methylenetetrahydrofolate reductase (MTHFR) mutation who developed recurrent PM lead thrombosis. He was successfully treated by slow infusion of recombinant-tissue plasminogen activator (r-tPA).

CASE REPORT

A 58-year-old male patient who was diagnosed with chronic heart failure and diabetes mellitus presented

with complaints of dyspnea and palpitation. The patient had a permanent PM (VVI-R) that was implanted 5 years ago due to symptomatic high-degree atrioventricular

block. He was receiving 100 mg acetylsalicylic acid, 12.5 mg carvedilol, and 5 mg warfarin daily, but the value of his international normalized ratio (INR) was not within therapeutic ranges. In addition, he had been treated with streptokinase and discharged from another hospital due to PM lead thrombosis two months ago. Upon physical examination, his blood pressure was 100/70 mmHg, and he had an irregular rhythm of 110 beats per minute. Heart auscultation revealed a

Abbreviations:

| | |
|-------|--|
| AF | Atrial fibrillation |
| INR | International normalized ratio |
| MTHFR | Methylenetetrahydrofolate reductase |
| PM | Pacemaker |
| RA | Right atrial |
| r-tPA | Recombinant-tissue plasminogen activator |

Received: March 05, 2012 Accepted: June 06, 2012

Correspondence: Dr. S. Selim Ayhan, Abant İzzet Baysal Üniversitesi Tıp Fakültesi Kardiyoloji Anabilim Dalı, 14280 Bolu.

Tel: +90 - 374 - 253 46 56 - 3195 e-mail: ssayhan@yahoo.com

© 2013 Turkish Society of Cardiology

systolic murmur in the tricuspid focus, while the rest of the physical examination was unremarkable. Electrocardiogram revealed atrial fibrillation (AF) with left bundle branch block, his renal function tests and blood glucose were elevated, and his D-dimer level was 17.66 mg/L.

Echocardiography revealed normal right ventricular dimensions and an enlarged left ventricle with poor contractility and an ejection fraction of 20%. In addition, a large right atrial (RA) thrombus was adherent to the PM lead (Fig. 1a). Transesophageal echocardiography (TEE) revealed a large RA thrombus attached to the PM lead, which extended into the right ventricle during diastole (Fig. 1b). Thorax computed tomography was not performed to evaluate for pulmonary embolism because of his high creatinine levels. His arterial blood gases and lower limb venous Doppler ultrasonography were unremarkable. There had been no change in the size of the thrombus despite undergoing unfractionated heparin therapy for a week. As a result of a cardio-vascular surgery consultation, surgical treatment was advised due to the large dimensions and mobility of the thrombus. However, the patient refused the surgery, and we decided to re-apply thrombolytic therapy. Intravenous r-tPA (50 mg) was applied as a 15 mg bolus followed by a 35 mg infusion after 12 h. Treatment with a continuous infusion of heparin (aPTT 60-70 msc) was ordered in addition to the treatment with r-tPA. After 12 hours, the thrombus appeared to be moderately smaller on echocardiography, so we decided to give an additional dose of 50 mg tPA in the following 12 hours. Follow-up echocardiography revealed that the RA thrombus attached to a permanent PM lead was completely resolved after the second day of therapy (Fig. 1c, Video 1). The patient's symptoms improved markedly after treatment, which is most likely due to the dissolution of the microemboli at the distal branches of the pulmonary artery. He was discharged with a treatment of warfarin, acetylsalicylic acid (300 mg per day), carvedilol, and furosemide. The INR value was set to be 3-3.5.

DISCUSSION

RA thrombus associated with PM leads is an unusual complication of PM insertion. Previous studies have reported that significant thrombotic and embolic complications occur in 0.6-3.5% of patients with permanent transvenous pacing leads.^[1]

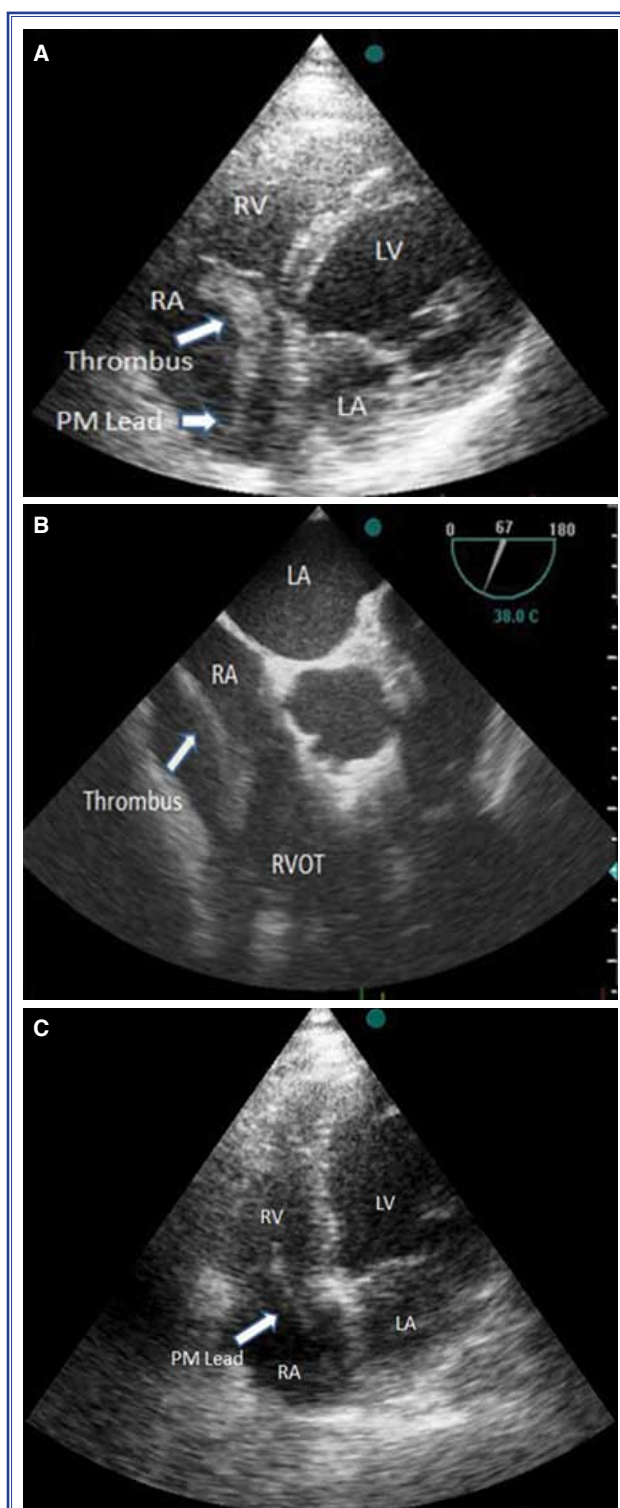


Figure 1. Transthoracic echocardiogram (TTE) showing (A) a large, mobile thrombotic mass in the right atrium (RA); (B) the RA attached to the PM lead and prolapsing into the RV outflow tract; (C) the thrombus has disappeared. Echocardiograms showing a PM lead in the RA and RV. LV: Left ventricle; LA: Left atrium; PM: Pacemaker; RV: Right ventricle; RA: Right atrium.

Several possible mechanisms have been suggested in the pathogenesis of PM-associated thrombosis, including endothelial injury, inflammation, and foreign body-type reaction.^[5] Heart failure, AF, and hypercoagulability may also cause thrombus formation. In our case, heart failure and AF together with inadequate anticoagulant therapy constituted significant predisposing factors for thrombosis. Our patient's platelet count revealed that his levels of serum protein C, serum protein S, and antithrombin III were normal. We performed thrombophilia screening tests for MTHFR C677T polymorphism, factor II, factor V Leiden mutations (G1691A), and plasminogen activator inhibitor-1 by polymerase chain reaction. These tests revealed that the patient had a heterozygous MTHFR gene mutation. Generally, a thrombophilia panel analysis may be appropriate in patients scheduled for device implantation who are particularly susceptible for thromboembolism, such as those with a history of embolism, AF, heart failure and immobility. In these patients, an evaluation of the balance between profit and harm may be appropriate before the device implantation.

Inherited thrombophilic disorders are known to increase the risk of venous thrombosis. Sabbagh et al.^[6] have shown that the prevalence of the MTHFR heterozygous mutation is very high (34.6%) in the general population. Patients with the MTHFR gene mutation may have elevated homocysteine levels, which are often related to an increased risk of venous thrombosis.^[7] However, homocysteine levels may also be normal in patients with MTHFR gene mutation, as was the case in our patient.^[8] We believe that the heterozygous MTHFR gene mutation, along with AF and heart failure, have given our patient an increased susceptibility to thrombosis. Another possible reason for our patient's recurrent thrombosis may be that there was an incomplete dissolution of the thrombus in the first instance. Consequently, any residual thrombus might have served as a nidus for further thrombosis.

Although there are several management strategies for RA thrombus, including thrombolytic therapy, surgical thrombectomy, and anticoagulation, the most appropriate therapeutic option remains controversial.^[9,10] Rose et al.^[11] indicated that thrombolytic therapy was associated with an improved survival rate when compared with anticoagulation therapy or surgery in this clinical setting. However, bleeding and massive

pulmonary embolism are some of the most feared complications of thrombolytic treatment. Surgical thrombectomy is a therapeutic option for patients with massive pulmonary embolism and opened foramen ovale, while anticoagulant therapy is accepted as a potent therapeutic option for the treatment of immobile thrombus and for patients with hemodynamic instability. Several reports have shown that the use of anticoagulants for the treatment of RA thrombus has yielded favorable results.^[12] However, the type of treatment should be established according to the dimension, mobility, and location of the RA thrombus. In our case, we suggested that the patient have surgery because the thrombus was mobile, large, and attached to the PM lead. However, he rejected the surgery, and therefore we started him on thrombolytic therapy.

Thrombolytic therapy remains the first line of treatment for the majority of patients. Streptokinase and r-tPA have been shown to be effective in the treatment of RA thrombus associated with PM leads.^[13,14] However, there is no standard protocol on how to apply thrombolytic agents for use in the treatment of intracardiac thrombus, as they have been used at various doses and with differing protocols in the literature. We initially gave our patient 50 mg t-PA (15 mg bolus followed-up with 35mg infusion after 12 hours), but at the end of the therapy his thrombus was not fully resolved. Therefore, we gave him an additional dose of 50 mg tPA over the following 12 hours. Although this treatment carries a theoretical risk of partial clot lysis and secondary pulmonary embolus, we did not detect these side effects in our patient. Slow infusion of r-tPA may be useful for the prevention of pulmonary embolization and bleeding complications during the treatment of intracardiac thrombus. Prosthetic valves that allow for fast thrombolytic infusion, especially in the presence of large thrombus, have shown an increased risk of embolism.^[15]

In conclusion, the heterozygous MTHFR gene mutation contributes to an increased risk of thrombosis in patients with PM lead. The slow infusion of r-tPA is effective and safe in the treatment of RA thrombus associated with PM lead.

Conflict-of-interest issues regarding the authorship or article: None declared

****Supplementary video file associated with this article can be found in the online version of the journal.***

REFERENCES

1. Barakat K, Robinson NM, Spurrell RA. Transvenous pacing lead-induced thrombosis: a series of cases with a review of the literature. *Cardiology* 2000;93:142-8.
2. Pfeiffer D, Jung W, Fehske W, Korte T, Manz M, Moosdorf R, et al. Complications of pacemaker-defibrillator devices: diagnosis and management. *Am Heart J* 1994;127:1073-80.
3. Porath A, Avnun L, Hirsch M, Ovsyshcher I. Right atrial thrombus and recurrent pulmonary emboli secondary to permanent cardiac pacing-a case report and short review of literature. *Angiology* 1987;38:627-30.
4. Koullias GJ, Eleftheriades JA, Wu I, Jovin I, Jadbabaie F, McNamara R. Images in cardiovascular medicine. Massive paradoxical embolism: caught in the act. *Circulation* 2004;109:3056-7.
5. Palatianos GM, Dewanjee MK, Panoutsopoulos G, Kapadvanjwala M, Novak S, Sfakianakis GN. Comparative thrombogenicity of pacemaker leads. *Pacing Clin Electrophysiol* 1994;17:141-5.
6. Sabbagh AS, Mahfoud Z, Taher A, Zaatari G, Daher R, Mahfouz RA. High prevalence of MTHFR gene A1298C polymorphism in Lebanon. *Genet Test* 2008;12:75-80.
7. den Heijer M, Koster T, Blom HJ, Bos GM, Briet E, Reitsma PH, et al. Hyperhomocysteinemia as a risk factor for deep-vein thrombosis. *N Engl J Med* 1996;334:759-62.
8. Kim KN, Kim YJ, Chang N. Effects of the interaction between the C677T 5,10-methylenetetrahydrofolate reductase polymorphism and serum B vitamins on homocysteine levels in pregnant women. *Eur J Clin Nutr* 2004;58:10-6.
9. Kinney EL, Wright RJ. Efficacy of treatment of patients with echocardiographically detected right-sided heart thrombi: a meta-analysis. *Am Heart J* 1989;118:569-73.
10. Chartier L, Béra J, Delomez M, Asseman P, Beregi JP, Bauchart JJ, et al. Free-floating thrombi in the right heart: diagnosis, management, and prognostic indexes in 38 consecutive patients. *Circulation* 1999;99:2779-83.
11. Rose PS, Punjabi NM, Pearse DB. Treatment of right heart thromboemboli. *Chest* 2002;121:806-14.
12. Kurisu S, Inoue I, Kawagoe T. Right atrial thrombosis after upgrading to a biventricular pacing/defibrillation system. *Intern Med* 2009;48:2101-4.
13. Cooper CJ, Dweik R, Gabbay S. Treatment of pacemaker-associated right atrial thrombus with 2-hour rTPA infusion. *Am Heart J* 1993;126:228-9.
14. May KJ Jr, Cardone JT, Stroebel PP, Riba AL. Streptokinase dissolution of a right atrial thrombus associated with a temporary pacemaker. *Arch Intern Med* 1988;148:903-4.
15. Ozkan M, Kaymaz C, Kirma C, Sönmez K, Ozdemir N, Balkanay M, et al. Intravenous thrombolytic treatment of mechanical prosthetic valve thrombosis: a study using serial transesophageal echocardiography. *J Am Coll Cardiol* 2000;35:1881-9.

Key words: Echocardiography; methylenetetrahydrofolate reductase; pacemaker, artificial/adverse effects; prosthesis failure; thrombolytic therapy; venous thrombosis/diagnosis; heart diseases.

Anahtar sözcükler: Ekokardiyografi; metilenterahidrofolat redüktaz; kalp pili/yan etki; protez başarısızlığı; trombolitik tedavi; venöz tromboz/tanı; kalp hastalıkları.