

Çift ağızlı yırtılmış Valsalva sinüsü anevrizmasının perkütan yolla tedavisi

Percutaneous treatment of a ruptured sinus Valsalva aneurysm with double orifices

Dr. Emre Refik Altekin, Dr. Hüseyin Yılmaz, Dr. Murathan Küçük, Dr. İbrahim Demir

Department of Cardiology, Akdeniz University Faculty of Medicine, Antalya, Turkey

Özet– Sinüs Valsalva anevrizması (SVA) yırtılıp kalp boşluklarına açılarak, aort ile diğer kalp boşlukları arasında anormal bağlantılara neden olabilir. Sağ atriyum ve/veya sağ ventrikül SVA yırtılmanın en sık açıldığı boşluklardır. Otuz yaşındaki erkek hasta nefes darlığı şikâyeti ile kardiyoloji polikliniğine başvurdu. Fizik muayenesinde sternumun sağ kenarında 5. interkostal aralıkta titreşim (tril) ve aort odağından başlayıp sternum sağ kenarı boyunca duyulan, boyuna ve sırta da yayılan sistolik-diastolik üfürüm saptandı. Ekokardiyografik ve invaziv incelemelerde sağ sinüs Valsalvadan sağ ventriküle geçişe neden olan iki defekt görüldü. Sol-sağ şant oranı 3,8 olarak hesaplanırken, defektlerin anatomik yerleşimleri ve boyutları perkütan kapamaya uygun bulundu. İki ayrı seansda Amplatzer Duct Occluder I cihazı kullanılarak defektler kapatıldı. Yırtılmış SVA'nın klasik tedavisi cerrahi onarım olmasına rağmen, uygun olgularda perkütan kapama cihazları alternatif ve güvenilir bir yöntem olarak kullanılabilir.

Summary– A Sinus Valsalva aneurysm (SVA) may rupture into the cardiac cavities and cause abnormal connections between these cavities and the aorta. The right atrium and/or right ventricle are the cavities into which the SVA is most commonly observed to rupture. A 30-year-old patient presented to our cardiology clinic with the complaint of dyspnea. His physical examination revealed a thrill localized in the 5th intercostal space on the right edge of the sternum and systolic-diastolic murmur beginning from the aortic focus and spreading to the neck and back along the right edge of the sternum. The echocardiographic and invasive examinations revealed two defects leading to a passage from the right sinus Valsalva into the right ventricle. While the left-to-right shunt ratio was calculated as 3.8, the anatomic locations and dimensions of the defects were found to be eligible for percutaneous closure. Using the Amplatzer Duct Occluder I device, the defects were closed in two sessions. Although the classical treatment method of ruptured SVA is surgical repair, percutaneous closure devices may be used as a reliable alternative method in suitable patients.

Geliş tarihi: 22.02.2012 Kabul tarihi: 06.06.2012

Yazışma adresi: Dr. Emre Refik Altekin. Akdeniz Üniversitesi Tıp Fakültesi Kardiyoloji Anabilim Dalı, Dumlupınar Bulvarı Akdeniz Üniversitesi Kampüsü, Konyaaltı 07100 Antalya.
Tel: +90 242 - 269 68 04 e-posta: dremre29@yahoo.com

Submitted on : 02.22. 2012 Accepted for publication on: 06.06.2012

Address of correspondence: Dr. Emre Refik Altekin. Akdeniz Üniversitesi Tıp Fakültesi Kardiyoloji Anabilim Dalı, Dumlupınar Bulvarı Akdeniz Üniversitesi Kampüsü, Konyaaltı 07100 Antalya, Turkey
Phone: +90 242 - 269 68 04 e-mail: dremre29@yahoo.com

Abbreviations:

ADO	<i>Amplatzer Duct Occluder</i>
ASD	<i>Atrial septal defect</i>
PDA	<i>Patent ductus arteriosus</i>
SVA	<i>Sinus Valsalva aneurysm</i>
TEE	<i>Transthoracic echocardiography</i>

Sinus Valsalva aneurysm (SVA) is a structural abnormality which constitutes 1-2 % of all congenital heart diseases. It is more frequently seen in male gender, and Asian populations. A congenital defect situated between an elastic lamina in Valsalva sinus over the aortic valve ring, and muscular tissue is held responsible for the development of this aneurysm.^[1,2] SVA is mostly (80-85 %) originates from the right coronary sinus, then non-coronary sinus (5-15 %), and rarely from the left coronary sinus. A 40-75 % of SVAs can rupture with time. Aneurysms mostly rupture into the right atrium and/or right ventricle, and seen mostly in patients aged 20-40 years.^[3] Classical treatment of ruptured SVA is surgical treatment. The outcomes of the surgical treatment are generally satisfactory, however risk of in-patient mortality (1.5-3.9 %), and stroke (1.6 %) still exists besides, recurrent SVA, and aortic insufficiency might develop.^[4,5]

In recent years various devices used for the percutaneous treatment of congenital heart diseases as atrial septal defect (ASD), and patent ductus arteriosus (PDA) have also been successful in the management of ruptured SVAs, and these treatment modalities have been reported as proper alternatives to surgery in appropriate cases.^[6]

In this article, a case with a ruptured SVA with double orifices arising from the right coronary sinus, and extending from aorta into the right ventricle which was closed percutaneously using Amplatzer Duct Occluder I (ADO I) device was presented.

CASE PRESENTATION

A 30-year-old male patient consulted to our outpatient clinics with complaints of exertional palpation, dyspnea, and stabbing chest for the last 2 months. His physical examination findings were as follows: arterial blood pressure, 140/60 mm Hg; pulse rate 95 /min, and body temperature, 36.5 °C. Cardiovascular system examination revealed a mild venous congestion, and a thrill was heard along the right edge of sternum in the 5th intercostal space. Besides fixed splitting of the 2nd heart sound, and continuous systolic-diastolic murmur starting from the aortic focus spreading to the neck, and back along the right edge of the sternum was heard. Bounding, and strong femoral arterial pulsation was also auscultated. Transthoracic (TTE), and transesophageal echocardiographic (TOE) examinations revealed an aneurysmatic right Valsalva sinus, and colour-Doppler ultrasonographic examination of the same region demonstrated a passage (a shunt) into the right ventricle (Figure 1a, b). On echocardiograms left -to -right shunt ratio was estimated as 3. On aortograms of the patient, two defects were observed. The large defect allowed passage of diffuse radioopaque material from the right Valsalva sinus into the right ventricle, and through the second defect lesser amount of contrast material passed. This left- to -right shunt ratio was 3.8 based on oximetric assessments (Figure 2a). With available findings, diagnosis of a sinus Valsalva aneurysm ruptured from aorta into the right ventricle was made. Aortograms, and echocardiograms of the patient were evaluated, and anatomic location, and dimensions (aortic edge of the main defect was 8 mm, and its length 6mm) of the defect were found to be suitable for percutaneous management. The patient was informed about surgical, and percutaneous treatment modalities. After written consent of the patient was obtained, firstly closure of the larger, and then the smaller defect were planned in two sessions.

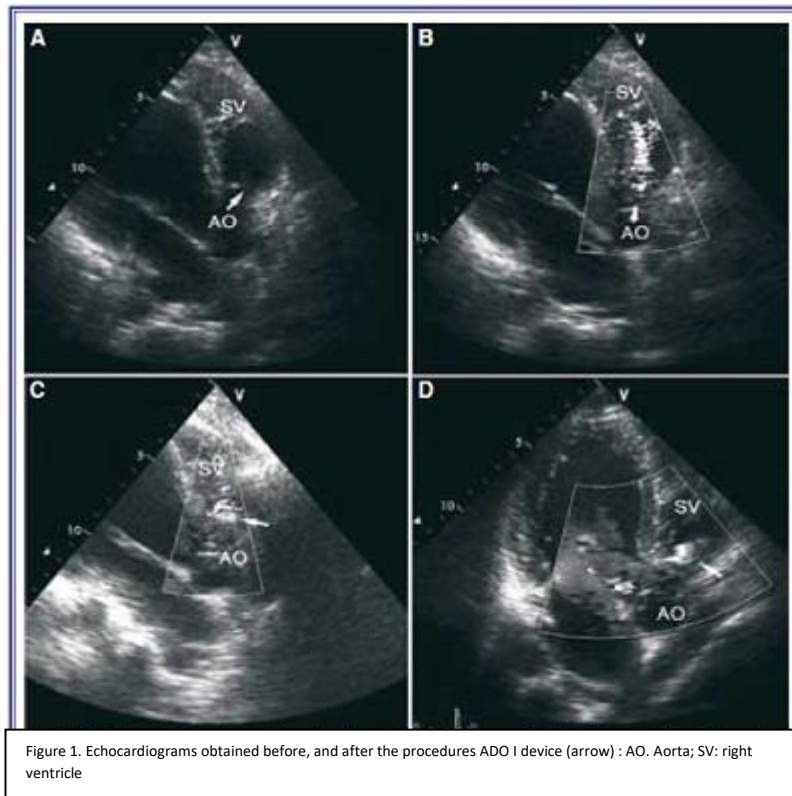


Figure 1. Echocardiograms obtained before, and after the procedures ADO I device (arrow) : AO. Aorta; SV: right ventricle

Both femoral regions were desensitized with local anesthesia. Using Judkins technique 6 French (F) delivery sheaths were inserted into the right femoral vein, and left femoral vein to establish required patent arterial, and venous access sites. Then heparin (50 IU/kg), and cefazoline sodium (2 g IV) were administered. A 6 Fr multi-purpose (Cordis) catheter was advanced with the aid of Terimo guidewire through femoral artery to reach ruptured SVA. The catheter was then passed through the right ventricle into the right atrium. Amplatzer Superstiff Straight (Boston Scientific, USA) guidewire (0.89 x 235 cm) was replaced with Terimo guidewire, and advanced through vena cava superior. Then multi-purpose catheter was withdrawn. Goose Neck retractor (10 mm, Microvenna, MN, ABD) was advanced intravenously into superior vena cava. At this level, Amplatzer Superstiff Straight guidewire was grasped, and removed from inside its femoral vein delivery sheath, to provide necessary arteriovenous route for the implantation of ADO 1 device (Figure 2b). With the aid of a guidewire an 8 Fr- catheter was passed via intravenous route, and advanced through the right ventricle, and

ruptured SVA site till it turned around the aortic arch. After removal of the guidewire, ADO I device (9-PDA-004, disc diameter 10 mm, length 7 mm and diameter 6 mm) loaded on the delivery system was advanced inside 8 Fr catheter till retention disc of the device was extruded beyond the distal end of the delivery sheath. Catheter together with the device was retracted from inside aortic arch. When the retention disc was engaged on the ruptured site, delivery system was held stable, and the catheter was retracted further to enable complete opening of the device. Meanwhile echocardiographic, and aortographic images were obtained from different angles to evaluate the position of the device and presence of leakage (if any). To determine if the device was engaged accurately in the ruptured site Minnesota manoeuvre was performed, and the device was left in situ after ideal location of the device was confirmed. Recorded images reviewed, and closure of the targeted defect, and continuous passage through the other defect were observed. (Figure 2c, d). Total duration of the procedure, and fluoroscopic examination was 60, and 30 min., respectively.

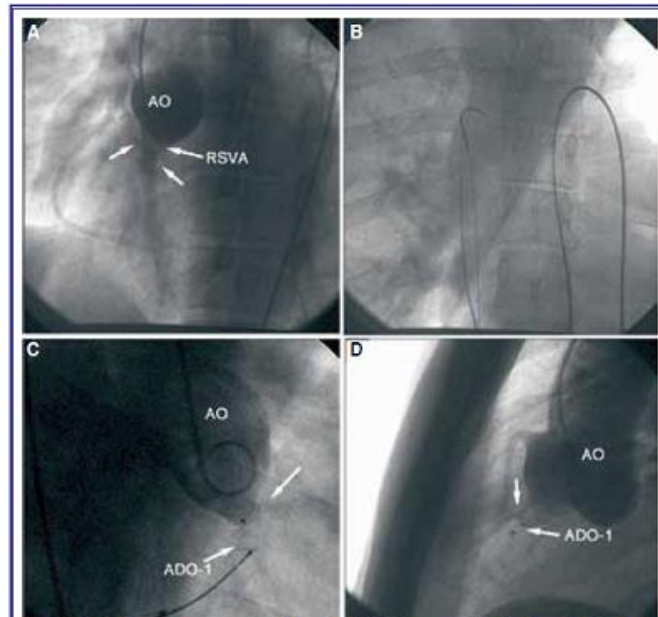


Figure 2. (A) Passage through aorta into the right ventricle (B) guidewire was grasped with the retractor (C, D) implantation of the first ADO I, and passage through (arrow) the other defect. ADO: Amplatzer Duct Occluder; AO: Aorta; RSVA; ruptured sinus Valsalva aneurysm

The patient was followed up for 6 months without development of any complication. At the end of the follow-up period invasive imaging, and hemodynamic studies were performed as planned beforehand. Lack of any passage through the firstly closed defect site, and regression of shunt ratio to 1.7 were observed. Meanwhile, aortic insufficiency did not deteriorate. Aortic edge (6 mm), and length (5mm) of the other defect site which allowed continuous passage were also determined as indicated in parentheses. Since dimensions, and anatomic location of the defect were deemed to be suitable for percutaneous management, we planned to close the defect with ADO I device used for

the first procedure. The device was positioned on the defect size as described for the first procedure (Figure 3a). Postprocedural images recorded demonstrated that both devices were positioned correctly. Postoperative aortograms displayed a markedly decreased passage from aorta into the right ventricle which was maintained at an acceptable level for the procedural success. (Figure 3b-d). The position of the devices was evaluated in control TTE performed one day later. Since any procedural complication was not observed, the patient was discharged with recommendation of dual antiplatelet drug therapy, and infective endocarditis prophylaxis to be maintained for one year.

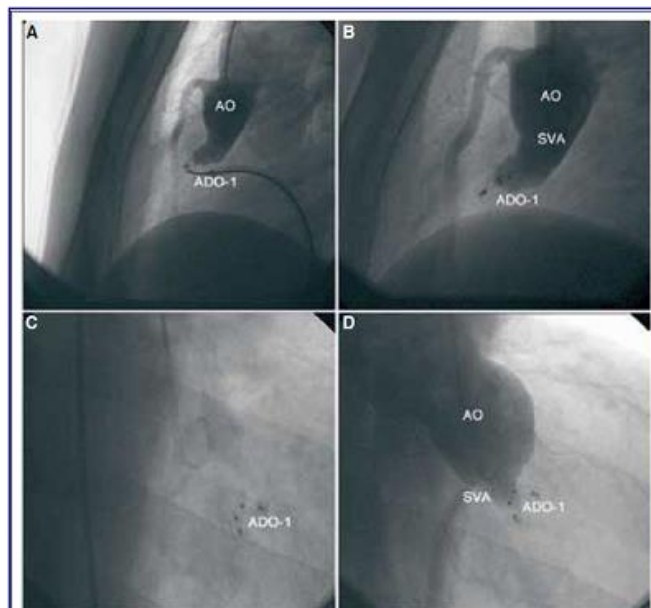


Figure 3. Implantation of the second ADO I device. Postprocedural images of the devices, and closure of the aorta-to-right ventricle shunt evidenced by disappearance of the left-to-right passage (ADO: Amplatzer Duct Occluder; AO; aorta; SVA Sinus Valsalva aneurysm)

DISCUSSION

ADO device developed for percutaneous treatment of patent ductus arteriosus, vascular fistulas, and pulmonary arteriovenous malformations was firstly used in 2003. by Fedson et al in the management of ruptured SVAs. Nowadays, case reports, and small scale case series have demonstrated potential use of ADO device in the management of selected cases of ruptured SVAs as an alternative to surgical treatment.^[7]

Before percutaneous treatment of ruptured SVAs, detailed evaluation of the patient as for other concomitant cardiovascular abnormalities is very important. The presence of additional anomalies can unfavourable effect the procedural success, and enhance the risk of postprocedural complications. Though larger patient series reporting treatment outcomes of ruptured SVAs using ADO devices have not been conducted yet, a 90 % procedural success rate has been indicated in available case reports, and small case series..^[8] Although rupture of SVA stemming from the right, and non-coronary sinus is suitable for percutaneous treatment, its communication with aortic leaflets, tricuspid valves, and coronary arteries are other factors effecting the procedural success rates. Selection of appropriate sized ADO devices is also important for the procedural success. Stabilization of the ADO device to be used for percutaneous closure on the defect site, use of devices 2-3 mm larger than the diameter of the defect is recommended.^[9]

In our case, because of absence of any concomitant structural abnormality, defect sizes, and locations suitable for percutaneous closure, we planned to repair both defects using ADO I device. We reviewed. the relevant literature, and couldn't find any reported case of ruptured SVA with adjacent two defects which opened into the same heart chamber, and treated using ADO device. Since simultaneous closure of these 2 defects might trigger thrombotic complications because of potential intraaortic metal load, problems which might be encountered in the adaptation of the devices on the defect size, and exacerbation of the existing aortic insufficiency secondary to excessive distension of the aortic ring, we planned to close these defects in two separate sessions

using ADO I device. We have thought that the firstly applied device would be able to complete its endothelization , and adapt to the defect size increasing the success rate of the 2. procedure with resultant facilitation of complete closure of the ruptured site during 6 month- interval between these two procedures. In evaluations performed 6 months after the first procedure, regression of the shunt ratio to 1.7, lack of any passage through the first device as observed on aortograms or absence of any deterioration of aortic insufficiency, markedly decreased passage from the aorta into the right ventricle after the 2nd. procedure without development of any complication demonstrate that complicated SVAs can be managed percutaneously in compliance with predetermined appropriate strategies.

In our clinics, previously, a ruptured right SVA which opened into the right atrium had been treated using ADO I device. The patient is still at his 2nd. postoperative year without occurrence of any adverse event. Though any complication has not been developed in any of our cases so far, in the medical literature procedural complications as right ventricular outlet obstruction, aortic insufficiency, coronary artery compression, and device-related hemolysis have been cited.^[10] Following percutaneous management of ruptured SVA, antiaggregant therapy, and prophylactic treatment of infective endocarditis have been recommended. Although conclusive data about the duration of therapy do not exist, since some authors have indicated that 6-12 month-therapy could suffice, we advised our patient to maintain dual antiaggregant therapy with clopidogrel, and acetylsalicylic for 12 months.^[11]

Percutaneous closure devices can be reliable, and safely used as alternative methods to surgical modalities for the management of conventional ruptured SVAs, and also more complex lesions. Though this treatment yields promising short-, and long-term outcomes , for more fully determination of its clinical efficacy, long-term results of larger scale studies are awaited.

Conflict of interest: None declared.

REFERENCES

1. Yıldız A, Canga A, Sen N. Ruptured sinus of Valsalva aneurysm associated with aortic

regurgitation and severe myocardial ischemia. Turk Kardiyol Dern Ars 2010;38:419-21.

2. Goldberg N, Krasnow N. Sinus of Valsalva aneurysms. Clin Cardiol 1990;13:831-6.

3. Chu SH, Hung CR, How SS, Chang H, Wang SS, Tsai CH, et al. Ruptured aneurysms of the sinus of Valsalva in Oriental patients. J Thorac Cardiovasc Surg 1990;99:288-98.

4. Dong C, Wu QY, Tang Y. Ruptured sinus of Valsalva aneurysm: a Beijing experience. Ann Thorac Surg 2002;74:1621-4.

5. Vural KM, Sener E, Taşdemir O, Bayazit K. Approach to sinus of Valsalva aneurysms: a review of 53 cases. Eur J Cardiothorac Surg 2001;20:71-6.

6. Kenny D, Hijazi ZM. Transcatheter approaches to non-valvar structural heart disease. Int J Cardiovasc Imaging 2011;27:1133-41.

7. Fedson S, Jolly N, Lang RM, Hijazi ZM. Percutaneous closure of a ruptured sinus of Valsalva aneurysm using the Amplatzer Duct Occluder. Catheter Cardiovasc Interv 2003;58:406-11.

8. Sivadasanpillai H, Valaparambil A, Sivasubramonian S, Mahadevan KK, Sasidharan B, Namboodiri N, et al. Percutaneous closure of ruptured sinus of Valsalva aneurysms: intermediate term follow-up results. EuroIntervention 2010;6:214-9.

9. Zhao SH, Yan CW, Zhu XY, Li JJ, Xu NX, Jiang SL, et al. Transcatheter occlusion of the ruptured sinus of Valsalva aneurysm with an Amplatzer duct occluder. Int J Cardiol 2008;129:81-5.

10. Altekin RE, Karakas MS, Er A, Yanikoglu A, Ozbek S, Yilmaz H. Percutaneous closure of ruptured sinus of Valsalva aneurysm with Amplatzer ductal occluder. Acta Cardiol 2011;66:657-60.

11. Kerka PG, Lanjewar CP, Mishra N, Nyayadhish P, Mammen I. Transcatheter closure of ruptured sinus of Valsalva aneurysm using the Amplatzer duct occluder: immediate results and mid-term follow-up. Eur Heart J 2010;31:2881-7.

Anahtar sözcükler: Aort anevrizması; aort yırtığı; ekokardiyografi; septal tıkaçıcı cihaz; Valsalva sinüsü.

Key words: Aortic aneurysm; aortic rupture; echocardiography; septal occluder device; sinus of Valsalva.