

## CASE REPORT

# Pseudoaneurysm after carotid stenting: A case report and review of the literature

## Karotis stentleme sonrası gelişen psödoanevrizma: Bir olgu sunumu ve literatür derlemesi

**Ahmet Güner, M.D.,<sup>1</sup> Selçuk Pala, M.D.,<sup>2</sup> Sabahattin Gündüz, M.D.,<sup>3</sup>  
Şeyhmus Külahçioğlu, M.D.,<sup>2</sup> Ezgi Gültekin Güner, M.D.<sup>1</sup>**

<sup>1</sup>University of Health Sciences Turkey, Mehmet Akif Ersoy Thoracic and Cardiovascular Surgery Center, Training and Research Hospital, Istanbul, Turkey;

<sup>2</sup>Department of Cardiology, Kartal Koşuyolu Heart Training and Research Hospital, Istanbul, Turkey;

<sup>3</sup>Department of Cardiology, VM Pendik Medical Park Hospital, Istanbul, Turkey

**Summary**– Carotid artery stenting has been a widely used interventional treatment method for the last 3 decades in the treatment of carotid artery stenosis. In the current literature, unlike major cardiovascular complications, less emphasis has been placed on carotid pseudoaneurysm (PA). A carotid artery PA can be caused by trauma, spontaneous infection, vasculitis, or it may be iatrogenic. However, the incidence of PA secondary to carotid stenting is extremely rare. Although it may be completely asymptomatic in rare instances, it usually progresses symptomatically (neck swelling, nerve compression, respiratory distress, hoarseness, dysphagia, and ischemic cerebrovascular events). Doppler ultrasound, contrast-enhanced computed tomography, and conventional angiography are the main diagnostic tools. Primary closure, including graft interposition, has been described as a surgical therapeutic option. An endovascular approach with placement of a covered or bare metal stent is an alternative treatment method to surgery.

**Özet**– Karotis arter stentlemesi, karotis arter stenozunun tedavisinde son 30 yıldır yaygın olarak kullanılan girişimsel bir tedavi yöntemidir. Güncel literatürde, majör kardiyovasküler komplikasyonların tersine karotis psödoanevrizmasına (PA) daha az vurgu yapılmıştır. Karotis arter PA'sı, travma, spontan enfeksiyon, vaskülit veya iyatrojenik nedenlerden kaynaklanabilir. Ancak, karotis stentlemeye ikincil PA oluşumu insidansı oldukça nadirdir. Daha nadir olarak tamamen semptomsuz olabildi de genellikle semptomlu (boyun şişmesi, sinir sıkışması, solunum sıkıntısı, ses kısıklığı, disfaji ve iskemik serebrovasküler olaylar) seyreder. Doppler ultrasonografi, kontrastlı bilgisayarlı tomografi ve konvansiyonel anjiyografi temel tanı aracıdır. Tedavide cerrahi seçenek olarak primer kapatma, greft interpozisyonu dahil tarif edilmiştir. Endovasküler yaklaşım ile kapalı/çıplak metal stentin yerleştirilmesi cerrahiye alternatif bir tedavi yöntemidir.

Carotid artery stenting (CAS) is becoming more widely used as an alternative to carotid endarterectomy in the treatment of carotid artery stenosis.<sup>[1]</sup> Most carotid artery studies have concentrated mainly on short-term cardiac and neurological complications of CAS. Less emphasis has been placed on long-term complications, such as restenosis, stent fracture, or carotid pseudoaneurysm (PA).<sup>[2]</sup> An extracranial carotid artery PA is an infrequent lesion that can arise from various causes, including trauma

(most common), spontaneous infection, vasculitides (such as Behçet's disease) or as an iatrogenic complication following a procedure.<sup>[3]</sup> Iatrogenic lesions can include complications of carotid endarterectomy or central venous catheterization. The incidence of a PA formation secondary to carotid stenting is extremely rare. The primary causes are infection, stent fracture, arterial wall injury by the

### Abbreviations:

CAS	Carotid artery stenting
CTA	Computed tomography angiography
PA	Pseudoaneurysm

Received: October 29, 2019 Accepted: March 06, 2020

Correspondence: Dr. Ahmet Güner. Mehmet Akif Ersoy Göğüs ve Kardiyovasküler Cerrahi Eğitim ve Araştırma Hastanesi, Kardiyoloji Kliniği, İstanbul, Turkey.

Tel: +90 216 - 500 15 00 e-mail: ahmetguner489@gmail.com

© 2020 Turkish Society of Cardiology

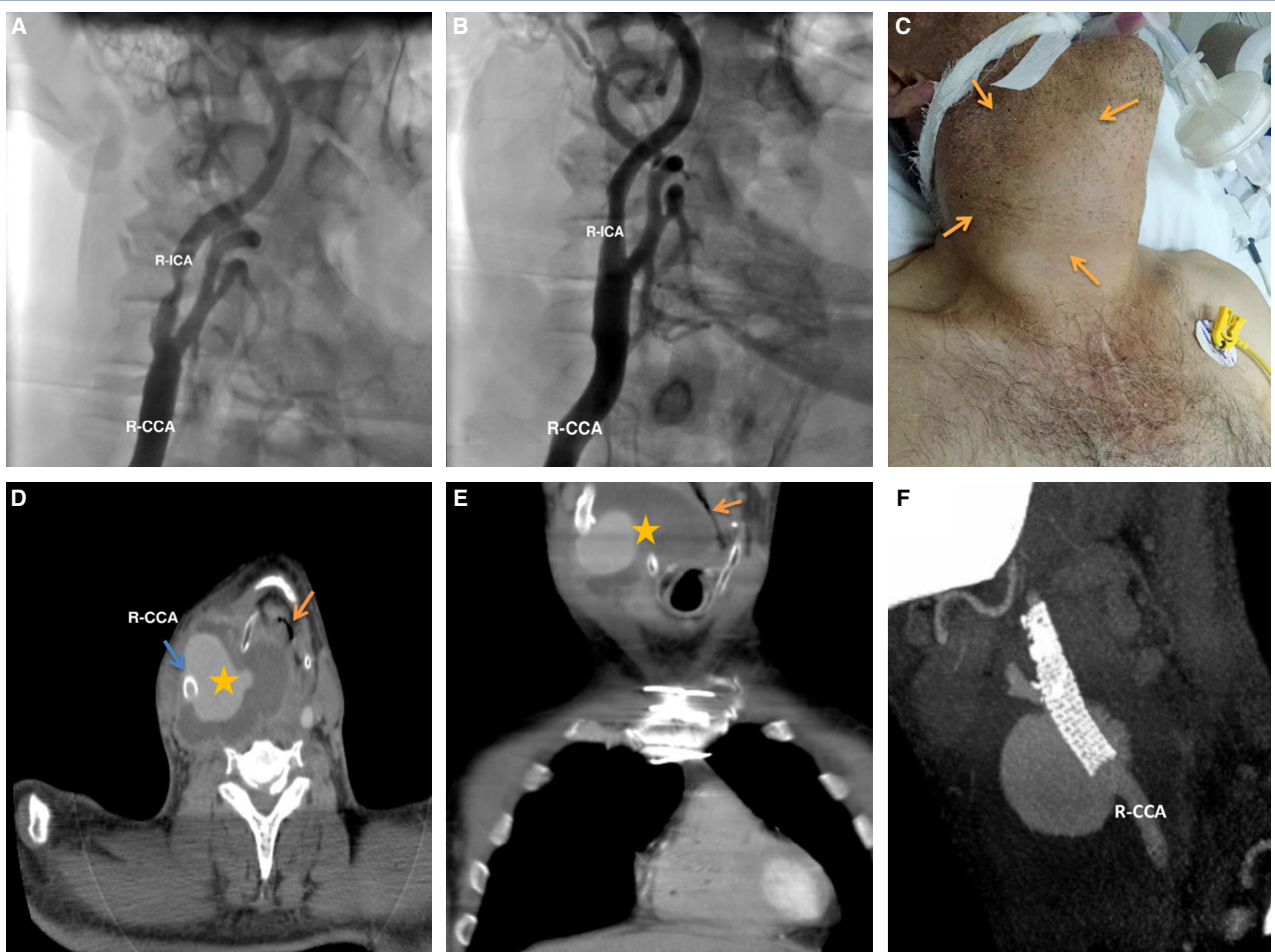


stent struts, hyperextension of the neck, and degeneration of the arterial wall.<sup>[4-10]</sup> There are completely asymptomatic forms, or more often, symptoms may include neck swelling, nerve compression, respiratory distress, hoarseness, dysphagia, and ischemic cerebrovascular events. Once the diagnosis is made, treatment is recommended in order to avoid rupture, distal embolization, and nerve compression; furthermore, several studies have reported a stroke prevalence of 50% and a mortality of 60% to 70% when a PA is left untreated.<sup>[11,12]</sup> Several surgical treatments have been described, including primary closure and patch angioplasty or graft interposition. An endovascular approach with the insertion of a covered or bare metal stent is an alternative option.<sup>[3,13,14]</sup> Presented here is a clinical case of PA after CAS and a review of cases of carotid PA after CAS described in the literature.

A search of the PubMed database was conducted for reviews and case reports of patients who developed a PA of the carotid artery after carotid stenting in the period between 2002 and 2017. The keywords used were carotid artery, pseudoaneurysm, carotid stenting, carotid pseudoaneurysm after carotid stenting, and false aneurysm after carotid stenting. All cases of a PA that developed after carotid endarterectomy or developed prior to carotid stenting were excluded. The number of PAs, details of presentation, etiology, and treatment were recorded and evaluated.

### CASE REPORT

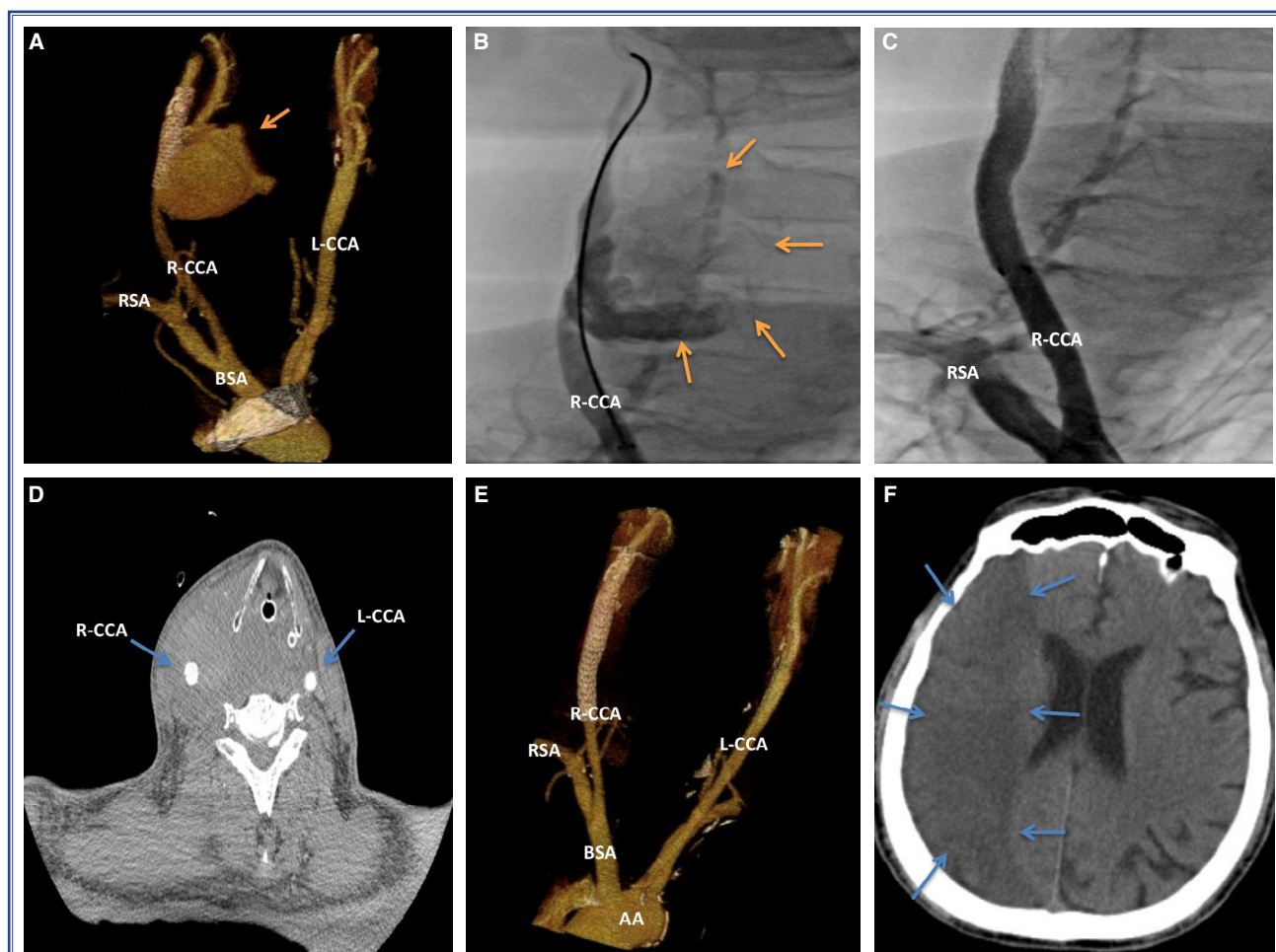
A 64-year-old male patient was admitted to the emergency department with stridor and shortness of breath. The patient had no history of rheumatic disorder or



**Figure 1.** A Conventional angiography shows a 80% stenotic lesion in the right carotid artery and successful stent implantation (A, B). The image demonstrates the mass on the right side of the neck (C) (yellow arrowheads). The horizontal, sagittal, and coronal planes of the contrast-enhanced computed tomography display a right carotid artery pseudoaneurysm (yellow star) and compressed trachea (yellow arrowhead) (D-F).

neck trauma. Percutaneous intervention using the right carotid artery had been performed approximately 7 months prior (Fig. 1a and b). A painless, pulsatile neck mass was discovered on the right side of the neck during the physical examination. The patient's vital signs were unstable; therefore, intubation was performed (Fig. 1c). Computed tomography angiography (CTA) revealed that a PA of the right carotid artery (112x55 mm) had caused tracheal compression (Fig. 1d-f, Fig. 2a). Catheterization was immediately performed on the carotid artery and a diagnostic carotid angiography was conducted through the right femoral artery. Blood flow was observed from the proximal end of the carotid stent into the PA and slow blood flow was observed in the distal carotid (Fig. 2b). A

covered stent 8x80 mm in size (Fluency Plus; Bard Peripheral Vascular, Tempe, AZ) was successfully implanted (Fig. 2c). Following the stent implantation, the CTA display indicated that the aneurysmal sac was closed (Fig. 2d and e). CT imaging of the brain and neck was performed, and the neck scan revealed cerebral edema covering the right hemisphere and wide infarction due to occlusion of the right mid-cerebral artery (Fig. 2f). *Staphylococcus haemolyticus* was determined to be present in triple-positive blood culture growth. The medical treatment included dual antiplatelet therapy (clopidogrel, acetyl salicylic acid) and antibiotic therapy (vancomycin, gentamicin). The patient died 8 days later due to respiratory failure and extensive cortical and brainstem infarction.



**Figure 2.** A 3-D version of the computer-assisted tomography shows the right carotid artery aneurysm (yellow arrowhead) (A). A conventional angiography of the right carotid demonstrates slow distal flow and a pseudoaneurysm (B) (yellow arrowheads). The aneurysmal sac was closed following the stent implantation (C). Following the stent implantation, the horizontal plane of the contrast-enhanced computed tomography scan displays the closed aneurysmal sac (D). Following the stent implantation, the 3-D version of the computer-assisted tomography demonstrates the closed aneurysmal sac (E). The brain CT displays common brain edema located in the right hemisphere (F).

Nine cases of PA following primary carotid stenting were identified in the English-language literature (Table 1). The presenting complaints were neck mass (55.5%), submandibular abscess (11.1%), dysphagia (11.1%), and ischemic cerebrovascular event (11.1%). One patient was diagnosed as asymptomatic. In 44.4% (4/9) of these patients, a bacterial infection was detected, and *Staphylococcus aureus* infection was detected in 75% (3/4). The presentation of 7 patients ranged from 1 week to 80 weeks after CAS. In 2 case reports, no definite length of time since CAS was provided. Open surgery was performed in 66.6% (6/9) of the patients. Saphenous vein graft interposition was performed in 4 of the surgical cases, a Pruitt-Inahara shunt (LeMaitre Vascular Inc., Burlington, MA, USA) was used in 1 case, and detailed surgical technique was not reported in the other case. Two of the remaining 3 patients underwent successful endovascular intervention. The other patient underwent successful stent implantation with a hybrid approach. The carotid PA and the stent were excised via longitudinal arteriotomy. The main carotid artery was then replaced with a polytetrafluoroethylene graft.

## DISCUSSION

APA, or false aneurysm, is an arterial dilatation formed by an intimal tear where the aneurysm is not walled by the 3 layers of the blood vessel, but by a blood clot or fibrous wall.<sup>[15]</sup> The development of a carotid PA is a very rare condition, with an incidence after CAS reported in the literature of less than 1%.<sup>[4-10,13,14]</sup> When a PA is suspected, CTA should be considered as the first diagnostic modality. This imaging technique guides both the diagnosis and the optimal treatment choice. Most of the cases described in the literature occurred within the first 3 months, and were associated with *Staphylococcus aureus* infection.<sup>[4,6-9,14]</sup> In this case report and literature review, we decided to focus our attention on carotid PAs following CAS. The usual symptoms are swelling of the neck with or without abscess, ischemic cerebrovascular event, or dysphagia, though more rarely, it may be asymptomatic, and the reported onset varied from 1 week to 80 weeks after CAS.

During the last 30 years, several endovascular approaches have been described. The most common option is the insertion of a covered stent or a bare metal

**Table 1. Carotid pseudoaneurysm after carotid stenting**

References	Year	Presentation	Timing	Etiopathogenesis	Treatment
Grazziotin et al. <sup>[4]</sup>	2002	A submandibular abscess	52 weeks	<i>S. aureus</i> infection	Surgery (Pruitt-Inahara shunt)
Kaviani et al. <sup>[5]</sup>	2006	A pulsatile neck mass with purulent drainage	80 weeks	Beta-hemolytic streptococcal infection	Surgey (saphenous vein interposition)
Stirling et al. <sup>[6]</sup>	2008	Dysphonia and dysphagia	11 weeks	Stent fracture	Surgery (saphenous vein interposition)
Raso et al. <sup>[7]</sup>	2011	A painful cervical mass	11 weeks	<i>S. aureus</i> septicemia	Surgery (saphenous vein interposition)
Bracale et al. <sup>[8]</sup>	2012	A pulsatile neck mass	4 weeks	Hyperextension of the neck	Endovascular stent graft implantation
Son et al. <sup>[9]</sup>	2014	Ischemic cerebrovascular event (right-sided weakness with dysarthria)	1 week	<i>S. aureus</i> septicemia	Surgery (saphenous vein interposition)
Baldawi et al. <sup>[10]</sup>	2015	Asymptomatic	N/A	Injury by stent struts	Hybrid
Yeo et al. <sup>[13]</sup>	2015	A pulsatile neck mass	N/A	N/A	Surgery
Tomai et al. <sup>[14]</sup>	2017	A pulsatile neck mass	1 week	N/A	Endovascular stent graft implantation

S. Aureus: *Staphylococcus aureus*. (Pruitt-Inahara shunt; LeMaitre Vascular Inc., Burlington, MA, USA).



stent followed by embolization of the PA.<sup>[8,14]</sup> There is a high risk of embolization in CAS with PA due to the passage of catheters and guidewires as well as stent occlusion. In a review, Seward et al.<sup>[3]</sup> reported a 7% perioperative occurrence of ischemic events after an endovascular approach to a carotid artery PA. Moreover, one should keep in mind that it may not be possible to achieve resolution of compression and prevent consequent cranial nerve injuries with an endovascular approach. The results of this literature review also indicate that after CAS, suspicion of edge dissection, fracture of the stent, or use of an oversized stent, suggest close monitoring of these patients should be considered. Surgical options include resection with a saphenous graft or prosthetic graft interposition, resection and primary reanastomosis, aneurysmectomy, and reconstruction using a venous or prosthetic patch. Complications of surgery include cerebrovascular events and death (reported to be 9% and 15%, respectively), cranial nerve injuries (as high as 15%), microembolization, and vascular rupture. In the treatment of an infected PA, saphenous vein graft interposition is the safest option.<sup>[16]</sup>

In our case, we chose to use an endovascular approach with placement of a stent graft due to the clinical condition of the patient and the lack of experienced surgeons to perform an emergency carotid surgery. It is most likely that our patient developed a carotid PA due to an infection after local contamination. Another possibility is a carotid PA due to edge dissection following CAS.

In conclusion, PA is an extremely rare complication after CAS. Nonetheless, PA of the carotid artery has the potential for high mortality and should be promptly recognized and treated. Based on our literature review, we find that open debridement following venous graft interposition is the safest treatment. The use of prosthetic materials should be discouraged when operating in an infective field. An endovascular approach should be reserved for noninfectious cases and may be considered in emergency cases. The early and long-term follow-up results for open surgery are favorable, but the instance of cranial nerve injury is not insignificant. There are no long-term follow-up data for endovascular treatment of a carotid PA. An international multicenter registration system is needed to identify the best treatment for a carotid PA.

**Peer-review:** Externally peer-reviewed.

**Conflict-of-interest:** None.

**Funding:** The author(s) received no financial support for the research, authorship, and/or publication of this article.

**Informed Consent:** Written informed consent was obtained from the patient for the publication of the case report and the accompanying images.

**Authorship contributions:** Concept: A.G.; Design: A.G., S.P.; Supervision: S.G.; Materials: Ş.K.; Data collection: E.G.G.; Literature search: Ş.K., E.G.G.; Writing: A.G., E.G.G.; Critical revision: A.G., S.P., S.G.

## REFERENCES

1. Arslan S, Köklü E, Yüksel İÖ, Çağırıcı G, Bayar N, Yılmaz A, Ket al. Two-year results of carotid artery stenting. *Türk Kardiyol Dern Ars* 2014;42:429–34. [\[CrossRef\]](#)
2. Yip HK, Sung PH, Wu CJ, Yu CM. Carotid stenting and endarterectomy. *Int J Cardiol* 2016;214:166–74. [\[CrossRef\]](#)
3. Seward CJ, Dumont TM, Levy EI. Endovascular therapy of extracranial carotid artery pseudoaneurysms: case series and literature review. *J Neurointerv Surg* 2015;7:682–9. [\[CrossRef\]](#)
4. Grazziotin MU, Strother CM, Turnipseed WD. Mycotic carotid artery pseudoaneurysm following stenting—a case report and lessons learned. *Vasc Endovascular Surg* 2002;36:397–401.
5. Kaviani A, Ouriel K, Kashyap VS. Infected carotid pseudoaneurysm and carotid-cutaneous fistula as a late complication of carotid artery stenting. *J Vasc Surg* 2006;43:379–82. [\[CrossRef\]](#)
6. Stirling MJ, Smith TP, McCann RL. Carotid artery angioplasty and stent placement: postprocedural hemorrhage and delayed pseudoaneurysm formation. *J Vasc Interv Radiol* 2008;19:595–9. [\[CrossRef\]](#)
7. Raso J, Darwich R, Ornellas C, Cariri G. Cervical carotid pseudoaneurysm: A carotid artery stenting complication. *Surg Neurol Int* 2011;2:86. [\[CrossRef\]](#)
8. Bracale UM, Vitale G, Caruso M, Bajardi G. Late carotid artery stent erosion and pseudoaneurysm after accidental hyperextension of the neck. *J Vasc Surg* 2012;55:242. [\[CrossRef\]](#)
9. Son S, Choi NC, Choi DS, Cho OH. Carotid stent infection: a rare but potentially fatal complication of carotid artery stenting. *BMJ Case Rep* 2014;2014:bcr2014011143. [\[CrossRef\]](#)
10. Baldawi M, Renno A, Abbas J, Nazzal M. Carotid artery pseudoaneurysm as a complication of carotid artery stenting. *Ann Vasc Surg* 2015;29:363.e1–363.e3633. [\[CrossRef\]](#)
11. Varetto G, Castagno C, Quaglini S, Garneri P, Benintende E, Gibello L, et al. Successful management with 2 overlapping bare stents for post-carotid endarterectomy carotid pseudoaneurysm secondary to carotid shunt. *Ann Vasc Surg* 2015;29:594.e1–4. [\[CrossRef\]](#)
12. Li Z, Chang G, Yao C, Guo L, Liu Y, Wang M, et al. Endovascular stenting of extracranial carotid artery aneurysm: a sys-

- tematic review. Eur J Vasc Endovasc Surg 2011;42:419–26.
13. Yeo LL, Wong J, Paliwal P, Majumder A, Chee EY, Ting E, Sharma VK. Giant Carotid Pseudoaneurysm. J Cardiovasc Ultrasound 2015;23:118. [CrossRef]
14. Tomai F, De Persio G, Petrolini A, Altamura L, Corcione N, Borioni R. Acute Pseudoaneurysm Following Carotid Artery Stenting. JACC Cardiovasc Interv 2017;10:622–3. [CrossRef]
15. Garg K, Gurjar HK, Singh PK, Singh M, Chandra PS, Sharma BS. Internal Carotid Artery Aneurysms Presenting with Epistaxis - Our Experience and Review of Literature. Turk Neurosurg 2016;26:357–63.
16. Mann CD, McCarthy M, Nasim A, Bown M, Dennis M, Sayers R, et al. Management and outcome of prosthetic patch infection after carotid endarterectomy: a single-centre series and systematic review of the literature. Eur J Vasc Endovasc Surg 2012;44:20–6. [CrossRef]

---

**Keywords:** Carotid artery; death; endovascular treatment; pseudoaneurysm.

**Anahtar sözcükler:** Karotis arteri; ölüm; endovasküler tedavi; pseudoanevrizma.