

## A ventricular septal defect with a continuous left-to-right shunt mimicking a ruptured sinus of Valsalva aneurysm

Soldan sağa şantlı, rüptüre Valsalva sinüs anevrizmasını taklit eden bir ventriküler septal defekt olgusu

Ali Hosseinsabet<sup>1</sup>

Khalil Forozannia<sup>2</sup>

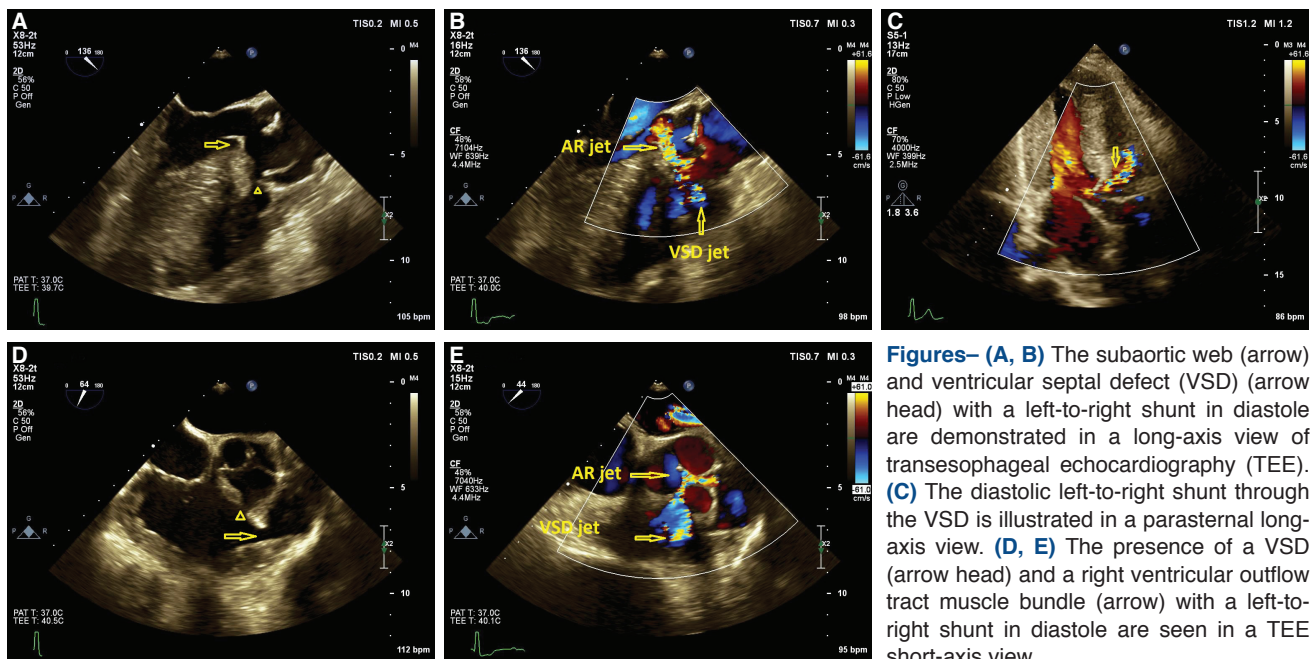
<sup>1</sup>Department of Cardiology, Tehran University of Medical Sciences, Tehran, Iran

<sup>2</sup>Department of Cardiac Surgery, Tehran University of Medical Sciences, Tehran, Iran

A 31-year-old man with the initial diagnosis of a ruptured sinus of Valsalva aneurysm was referred to our echocardiography ward for further evaluation. The patient complained of dyspnea on exertion. The physical examination revealed a systolic murmur (III/VI) at the left sternal border and apex, and a

faint diastolic murmur at the left sternal border. Electrocardiogram results demonstrated a left ventricular (LV) hypertrophy pattern. Transthoracic and transesophageal echocardiographic examinations revealed a subaortic web with severe LV outflow tract stenosis (peak pressure gradient: 65 mmHg) accompanied by severe aortic regurgitation. In addition, there was a muscle bundle in the right ventricular outflow tract (RVOT), resulting in severe RVOT stenosis (peak pressure gradient: 97 mmHg) that was suggestive of a double-chambered right ventricle (RV). A perimembranous ventricular sep-

tal defect (VSD) 9 mm in size was also observed. The LV orifice of the VSD was located between the aortic valve and the aortic web, and the RV orifice was located in the proximal high-pressure RV chamber. This position of the VSD conducted the aortic regurgitation flow to the RV in diastole, simulating a continuous flow in systole and diastole (Fig. 1). Other echocardiographic findings included normal LV size and function, severe RV enlargement with moderate systolic dysfunction, mild LV and severe RV hypertrophy, and severe pulmonary valve regurgitation (pressure half time: 60 ms). These findings were confirmed in the operating room, where aortic and pulmonic valve replacement, VSD closure, subaortic web resection, and RVOT muscle bundle resection were performed. A postoperative echocardiography documented normal function of the aortic and pulmonary prosthetic valves and the disappearance of the subaortic and RVOT stenosis with no residual VSD shunt. VSD shunts are seen below the aortic valve; however, it is deserving of special attention that a continuous shunt mimicking a ruptured aneurysm of the sinus of Valsalva can be found above the aortic valve.



**Figures– (A, B)** The subaortic web (arrow) and ventricular septal defect (VSD) (arrow head) with a left-to-right shunt in diastole are demonstrated in a long-axis view of transesophageal echocardiography (TEE). **(C)** The diastolic left-to-right shunt through the VSD is illustrated in a parasternal long-axis view. **(D, E)** The presence of a VSD (arrow head) and a right ventricular outflow tract muscle bundle (arrow) with a left-to-right shunt in diastole are seen in a TEE short-axis view.

AR: Aortic regurgitation; VSD: Ventricular septal defect.

\*Supplementary video files associated with this presentation can be found in the online version of the journal.