

## A Rare Case of Multiple Thrombosis Associated with COVID-19 Pneumonia

### COVID-19 Pnömonisi ile İlişkili Nadir bir Çoklu Tromboz Vakası

#### ABSTRACT

Coronavirus disease 2019 is an infectious disease caused by the severe acute respiratory syndrome coronavirus 2 virus. Hypoxic respiratory failure, multiorgan dysfunction, septic shock, thrombosis, and thromboembolic complications have been associated with the severe acute respiratory syndrome coronavirus 2 infection. We report the presentation of the severe acute respiratory syndrome coronavirus 2 infection with acute upper extremity ischemia and mesenteric ischemia clinic. We also report that this patient had an aortic arch mural thrombus as a possible source of thromboembolism, and we emphasize that the aorta should also be carefully evaluated in thromboembolic patients with coronavirus disease 2019.

**Keywords:** Aortic arch, COVID-19, thromboembolism, thrombosis

#### ÖZET

Koronavirus hastalığı 2019 (COVID-19), şiddetli akut solunum sendromu koronavirüs 2 (SARS-CoV-2) virüsünün neden olduğu bulaşıcı bir hastalıktır. Hipoksik solunum yetmezliği, çoklu organ disfonksiyonu, septik şok, tromboz ve tromboembolik komplikasyonlar SARS-CoV-2 enfeksiyonu ile ilişkilendirilmiştir. SARS-CoV-2 enfeksiyonunun akut üst ekstremitte iskemisi ve mezenterik iskemi kliniği ile prezentasyonunu bildiriyoruz. Ayrıca bu hastada olası bir tromboemboli kaynağı olarak aort ark mural trombüsü olduğunu bildiriyor ve COVID-19 hastalarında aortanın da tromboemboli kaynağı olarak dikkatlice değerlendirilmesi gerektiğini vurguluyoruz.


**Anahtar Kelimeler:** Aortik ark, COVID-19, tromboembolizm, tromboz


The coronavirus disease 2019 (COVID-19) pandemic continues to affect millions of people around the world. Patients infected with COVID-19 may present with high fever, hypoxic respiratory failure, cough, gastrointestinal symptoms, kidney damage, dermatological findings, and neuropsychiatric symptoms. Also, clinicians in many countries have reported an increase in thrombotic and thromboembolic events since the beginning of the COVID-19 pandemic. Proinflammatory environment, hypercoagulable state, and endothelial dysfunction resulting from systemic infection are held responsible for the development of thrombotic and thromboembolic complications.<sup>1</sup> We report a patient with COVID-19 presenting with simultaneous arm pain and abdominal pain due to subclavian artery and superior mesenteric artery thrombosis accompanying aortic arch mural thrombosis.

#### Case Report

A 67-year-old male presented to the emergency department with complaints of severe pain, numbness, and purple skin discoloration in the left arm that had started acutely since a few hours. The patient also described sudden-onset severe abdominal pain 15 minutes after admission to our emergency department. The patient had no significant respiratory distress or fever. His past medical history comprised diabetes mellitus and coronary artery bypass graft surgery 10 years ago. The regular medications that he used were acetylsalicylic acid 100 mg, atorvastatin 20 mg, metoprolol 50 mg, vildagliptin 100 mg, and metformin 2000 mg per day. The diagnosis of the severe acute respiratory syndrome coronavirus 2 (SARS-CoV-2) had been made 12 days before admission by

#### CASE REPORT OLGU SUNUMU

İbrahim Yıldız<sup>1</sup> 

Şerif Hamideyin<sup>2</sup> 

Zeynel Duman<sup>3</sup> 

Fahrettin Güngördü<sup>4</sup> 

Mehmet Korkmaz<sup>5</sup> 

<sup>1</sup>Department of Cardiology, Adana Çukurova State Hospital, Adana, Turkey

<sup>2</sup>Department of Cardiology, Kafkas University Faculty of Medicine, Kars, Turkey

<sup>3</sup>Department of Cardiovascular Surgery, Adana Çukurova State Hospital, Adana, Turkey

<sup>4</sup>Department of Radiology, Adana Çukurova State Hospital, Adana, Turkey

<sup>5</sup>Department of General Surgery, Adana Çukurova State Hospital, Adana, Turkey

#### Corresponding author:

İbrahim Yıldız

✉ ibrahimyildiz79@yahoo.com

**Received:** February 20, 2022

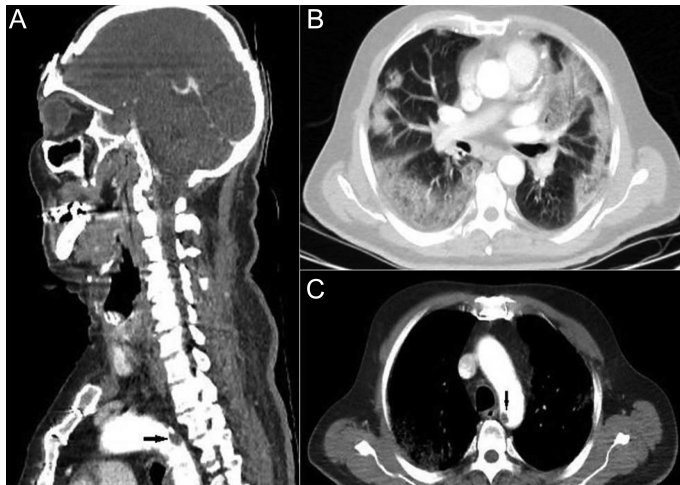
**Accepted:** April 14, 2022

**Cite this article as:** Yıldız İ, Hamideyin Ş, Duman Z, Güngördü F, Korkmaz M. A rare case of multiple thrombosis associated with COVID-19 pneumonia. *Türk Kardiyol Dern Ars.* 2022;50(6): 466-469.

DOI:10.5543/tkda.2022.22379



Available online at [archivestsc.com](http://archivestsc.com). Content of this journal is licensed under a Creative Commons Attribution - NonCommercial-NoDerivatives 4.0 International License.



**Figure 1. A-C. (A) Black arrow indicates thrombus attached to the aortic arch wall with its narrow base. (B) Chest computed tomography scan showing bilateral ground glass opacification with consolidation compatible with COVID-19 pneumonia. (C) Aortic thrombosis seen in the aortic arch.**

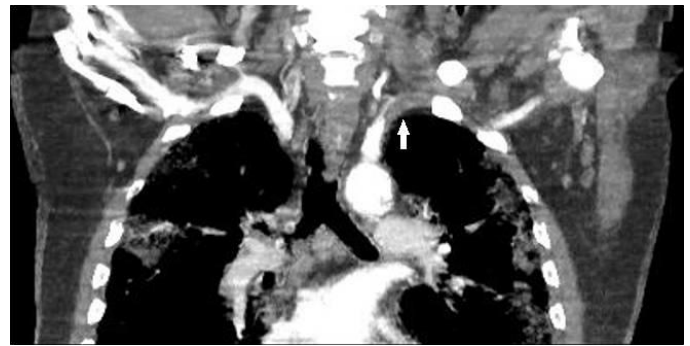
reverse transcriptase-polymerase chain reaction (PCR) analysis after experiencing malaise, cough, and general condition disorder. He had not been started on any medication related to COVID-19 disease after PCR positivity. On examination, the left arm was pale, cold, bruised, and there was tenderness in the abdomen. Pulses were not palpable at the left brachial artery and distal to the artery. Further systemic examination was unremarkable.

Electrocardiogram was normal with sinus rhythm. A transthoracic echocardiogram revealed normal size heart chambers, normal valve functions, and mildly decreased left ventricular function with an ejection fraction of 45% without any thrombosis excluding a cardiac source of embolization. Intracardiac shunting was also not observed, suggesting paradoxical embolism. No thrombus was observed in the heart chambers in computed tomography (CT) angiography either.

His presenting laboratory test showed an elevated white blood cell count of  $15.4 \times 10^9/L$  (normal:  $4.5-10 \times 10^9/L$ ), normal hemoglobin of 15.2 g/dL (normal: 11-16 g/dL), normal platelet count of  $340 \times 10^9/L$  ( $100-420 \times 10^9/L$ ), normal international normalized ratio of 1.14 (normal: 0.8-1.2), normal activated partial thromboplastin time of 21.0 seconds (normal: 20-38 seconds), normal prothrombin time of 13.8 seconds (normal: 10-15 seconds), elevated creatinine kinase of 2511 U/L (normal: 32-308 U/L), elevated D-dimer of 9460  $\mu g/L$  (normal: 0-550  $\mu g/L$ ), elevated C-reactive protein of 189.6 mg/L (normal: <5 mg/L), elevated ferritin of 814  $\mu g/L$  (normal: 10-322  $\mu g/L$ ), normal troponin I of 26.5 ng/L (normal: 0-47 ng/L), elevated aspartate aminotransferase of 74 U/L (normal: 0-41 U/L), normal alanine aminotransferase of 34 U/L

## ABBREVIATIONS

COVID-19	Coronavirus disease 2019
CT	Computed tomography
PCR	Polymerase chain reaction
SARS-CoV-2	Severe acute respiratory syndrome coronavirus 2

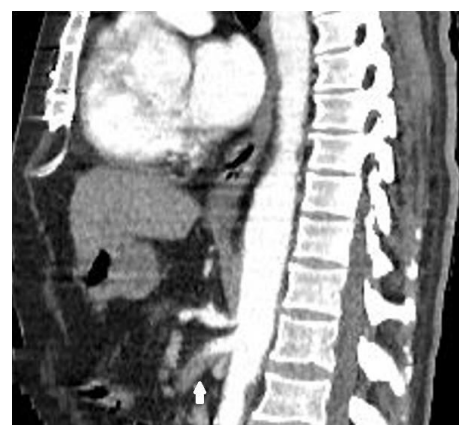

**Figure 2. Axial image showing the thrombotic subtotal occlusion of the left subclavian artery extending into the axillary artery.**

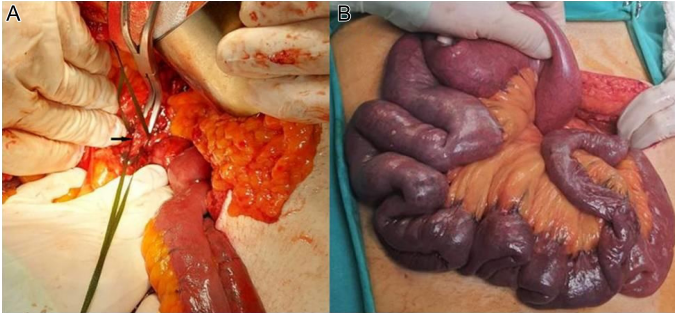
(normal: 0-49 U/L), and elevated lactate dehydrogenase of 775 U/L (normal: 120-246 U/L).

Thoracoabdominal and upper extremity CT angiography was planned for the patient. Computed tomography angiography showed a mural thrombus in the aortic arch (Figure 1A, 1B), subocclusive thrombus in the proximal left subclavian artery extending into the axillary artery (Figure 2), and complete occlusion of the superior mesenteric artery near the origin with evidence of thrombus (Figure 3). Chest CT showed bilateral ground-glass opacities with bilateral lung consolidation compatible with COVID-19 pneumonia (Figure 1C).

The patient was immediately heparinized in the emergency department and subsequently underwent emergent exploratory laparotomy and superior mesenteric artery thrombectomy. Small transverse arteriotomy to the superior mesenteric artery was made, and thrombectomy was performed with a Fogarty catheter (Figure 4A). Upon exploration, there was no necrotic segment of the bowel requiring resection but bowel ischemia was present (Figure 4B). The thrombus was removed, and pulsatile flow was established. Emergent surgical thrombectomy with Fogarty catheters through the left subclavian, axillary, brachial, and radial artery was also performed. As an outcome, perfusion to the arm and hand was restored. The patient was followed in the intensive care unit intubated after surgery. In the postoperative



**Figure 3. White arrow indicates total occlusion of the superior mesenteric artery near its origin.**



**Figure 4. A-B. (A) Black arrow indicates thrombus at the exit of the superior mesenteric artery. (B) Ischemic discoloration of the small intestine due to embolism.**

period, low-molecular-weight heparin therapy was administered at the therapeutic dose. Infectious disease was consulted, and he was started on a course of meropenem and linezolid for bacterial pneumonia and prednisolone for COVID-19 pneumonia. During follow-up in the intensive care unit, the patient developed hypotension. Intravenous fluid therapy and vasoconstrictor therapy were given for the treatment of hypotension. As a result of multiorgan dysfunction syndrome and likely sepsis, the patient died 1 week after hospitalization.

### Discussion

The coronavirus disease 2019 infection is more often associated with an increased risk of venous thromboembolism and less often with an increased risk of arterial thrombosis and subsequent embolic events. The incidence of arterial thrombosis and subsequent embolic events in critically ill patients with COVID-19 is 4.4% and most commonly occurs in the extremities and cerebral vessels.<sup>1</sup> The incidence of great vessel involvement is around 19% in all reported arterial thrombosis cases related to COVID-19.

Cases of arterial thrombosis associated with COVID-19 usually result from an underlying atherosclerotic plaque and its erosion.<sup>2</sup> Localized endothelial injury, diffuse endotheliitis, and the disease itself being prothrombotic in condition causing hemostasis disorder are also held responsible for arterial thrombus formation.<sup>1</sup> Although thromboembolic complications are frequently observed in patients with COVID-19 infection, our case highlights the formation of a thrombus in the aortic arch as the source of systemic thromboembolism.

Emerging case reports have described that patients with SARS-CoV-2 can develop aortic mural thrombus.<sup>3-5</sup> Aortic thrombosis due to COVID-19 may occur spontaneously or may occur as a result of destabilization of the existing atherosclerotic plaque.<sup>2,6</sup> The majority of the reports consist of cases with thrombus formation in the descending aorta and abdominal aorta. Reported cases of aortic arch thrombus are extremely rare due to high blood pressure and flow.<sup>7</sup> Since aortic arch thrombus cases due to COVID-19 infection are present in the literature, we thought that the thrombus in the aortic arch was due to COVID-19 infection.

The aortic thrombus is a rare but serious clinical condition that is able to cause dramatic peripheral embolism. It has

been previously reported that aortic thrombus can be seen in patients with COVID-19 and may be a source of embolism. Acute thromboembolism and aortic mural thrombus can also be primary manifestations of SARS-CoV-2 infection.<sup>8</sup> In our case, the simultaneous development of arm pain and abdominal pain suggested thromboembolism. In addition, there was thrombus appearance in the arcus aorta as the only source of thromboembolism seen in the left subclavian artery and superior mesenteric artery. No thrombus appearance was observed in the heart chambers and shunting within the heart suggestive of paradox embolism in transthoracic echocardiography and CT angiography. The median time from onset of clinic consistent with coronavirus infection to the development of arterial thrombosis was reported to be 19 (11-23) days.<sup>3</sup> Consistent with this finding, thromboembolism was observed in our patient on the 13th day of the disease.

Significant increase in D-dimer levels as a coagulopathy-related indicator and ferritin levels as an inflammation-related indicator are markers of increased thromboembolic events and poor prognosis in patients with COVID-19.<sup>9</sup> In our patient, the D-Dimer and ferritin levels were also quite high at admission. Comorbid conditions such as cardiovascular disease, chronic renal failure, atrial fibrillation, hypertension, and diabetes mellitus accompanying COVID-19 infection have been reported as risk factors for thrombus development.<sup>2</sup> Our case also had diabetes mellitus and coronary artery disease as comorbid diseases.

In a newly published cohort study of 4297 patients, the fact that early initiation of prophylactic anticoagulation reduces the risk of 30-day mortality supports guidelines recommending prophylactic anticoagulation as initial therapy.<sup>10</sup> In our case, our patient's PCR result was positive 12 days ago, but he had not received anticoagulant treatment after PCR positivity. It is yet unclear whether anticoagulation therapy should be initiated in all PCR-positive or hospitalized patients and whether anticoagulant therapy should be given at a prophylactic or therapeutic dose.

In conclusion, as the SARS-CoV-2 pandemic continues to impact the community, clinicians should be careful about complaints related to arterial thromboembolic complications due to a high association between COVID-19 infection and the development of an intensely prothrombotic state. Clinicians should be alert that aortic thrombus may also be a source of embolism in COVID-19 patients, and thoracoabdominal CT angiography should be considered in routine evaluation in COVID-19 patients presenting with embolic complications.

**Informed Consent:** Written informed consent was obtained from the patient's guardian for sharing the relevant medical history, laboratory, and imaging results.

**Peer-review:** Externally peer-reviewed.

**Author Contributions:** Concept - İ.Y., Ş.H.; Design - İ.Y., Ş.H.; Supervision - İ.Y., Ş.H.; Resources - Z.D., F.G., M.K.; Materials - Z.D., F.G., M.K.; Data Collection and/or Processing - Z.D., F.G., M.K.; Analysis and/or Interpretation - İ.Y., Ş.H.; Literature Search - İ.Y., Ş.H.; Writing Manuscript - İ.Y., Ş.H.; Critical Review - İ.Y., Ş.H.

**Declaration of Interests:** The authors have no conflict of interest to declare.

**Funding:** This study received no funding.

## References

1. Cheruiyot I, Kipkorir V, Ngure B, Misiani M, Munguti J, Ogeng'o J. Arterial thrombosis in coronavirus Disease d019 patients: a rapid systematic review. *Ann Vasc Surg.* 2021;70:273-281. [\[CrossRef\]](#)
2. Goudot G, Amrane M, El Ayoubi R, et al. Thrombus of the aorta and SARS-CoV-2 infection: cause or trigger? *Front Cardiovasc Med.* 2021;8:700292. [\[CrossRef\]](#)
3. Baeza C, González A, Torres P, Pizzamiglio M, Arribas A, Aparicio C. Acute aortic thrombosis in COVID-19. *J Vasc Surg Cases Innov Tech.* 2020;6(3):483-486. [\[CrossRef\]](#)
4. Gomez-Arbelaez D, Ibarra-Sanchez G, Garcia-Gutierrez A, Coman-ges-Yeboles A, Ansuategui-Vicente M, Gonzalez-Fajardo JA. COVID-19-related aortic thrombosis: a report of four cases. *Ann Vasc Surg.* 2020;67:10-13. [\[CrossRef\]](#)
5. Woehl B, Lawson B, Jambert L, Tusch J, Ghassani A, Hamade A. 4 Cases of aortic thrombosis in patients with COVID-19. *JACC Case Rep.* 2020;2(9):1397-1401. [\[CrossRef\]](#)
6. Mullan C, Powierza C, Miller PE, Geirsson A, Vallabhajosyula P, Assi R. Spontaneous coronavirus disease 2019 (COVID-19)-associated luminal aortic thrombus. *J Thorac Cardiovasc Surg.* 2020;160(2):e13-e14. [\[CrossRef\]](#)
7. Schmidt P, Vasquez J, Gagliano B, Moore AJ, Roberts CS. Ascending aortic thrombus with multiple emboli associated with COVID-19. *Proc (Bayl Univ Med Cent).* 2020;34(1):178-179. [\[CrossRef\]](#)
8. Szeles A, El-Daher NT, Lachant N, Rizk TA. Acute limb ischemia and aortic mural thrombosis as primary manifestations of severe acute respiratory syndrome coronavirus 2. *J Vasc Surg Cases Innov Tech.* 2021;7(4):605-609. [\[CrossRef\]](#)
9. Galland J, Thoreau B, Delrue M, et al. White blood count, D-dimers, and ferritin levels as predictive factors of pulmonary embolism suspected upon admission in noncritically ill COVID-19 patients: the French multicenter CLOTVID retrospective study. *Eur J Haematol.* 2021;107(2):190-201. [\[CrossRef\]](#)
10. Rentsch CT, Beckman JA, Tomlinson L, et al. Early initiation of prophylactic anticoagulation for prevention of coronavirus disease 2019 mortality in patients admitted to hospital in the United States: cohort study. *BMJ.* 2021;372:n311. [\[CrossRef\]](#)