

## Successful balloon angioplasty for inferior vena cava-right atrium anastomotic stenosis following orthotopic heart transplantation

Ortotopik kalp nakli sonrasında gelişen inferior vena kava-sağ atriyum anastomozundaki darlığın balon anjiyoplasti ile başarılı tedavisi

Şule Korkmaz, M.D.,<sup>1</sup> Serkan Topaloğlu, M.D.,<sup>1</sup> Serkan Çay, M.D.,<sup>1</sup> Mehmet Ali Özatik, M.D.<sup>2</sup>

Departments of <sup>1</sup>Cardiology and <sup>2</sup>Cardiovascular Surgery,  
Türkiye Yüksek İhtisas Heart - Education And Research Hospital, Ankara

Stenosis formation at anastomotic sites following cardiac transplantation is a rare complication. These strictures can be overcome surgically or percutaneously. A 54-year-old man underwent orthotopic heart transplantation for end-stage dilated cardiomyopathy. Size mismatch between the recipient and the donor resulted in a tight bicaval anastomosis. After seven days postoperatively, the patient developed significant bilateral leg edema. On the tenth postoperative day, he underwent right heart catheterization, and with the injection of contrast material, a stricture was noted at the anastomotic line between the inferior vena cava and the right atrium. The mean pressure gradient at the level of the stenosis was 8 mmHg. The stenotic segment was dilated using a Tyshak II percutaneous valvuloplasty catheter. At the end of the procedure, the mean pressure gradient decreased to 2 mmHg and dilatation was confirmed by venography. Leg edema diminished a few days after the procedure. Hence, the use of a pulmonary balloon catheter for stenotic lesions at the level of anastomosis line between the inferior vena cava and the right atrium yielded a desirable result.

**Key words:** Angioplasty, balloon; anastomosis, surgical/complications; constriction, pathologic; heart transplantation; vena cava, inferior.

Total orthotopic heart transplantation is performed for various end-stage heart and lung diseases. The most widely used technique includes total removal of the recipient's atria, bicaval end-to-end anastomosis, and anastomosis of the pulmonary veins.<sup>[1]</sup> Although it is a highly suitable technique for patients with end-stage heart/lung failure, some postoperative complications

kalp transplantasyonu sonrası anastomoz bölgesinde darlık oluşumu nadir bir komplikasyondur. Bu darlıklar cerrahi veya perkütan yolla tedavi edilebilir. Elli dört yaşında erkek hastaya son evre dilate kardiyomyopati tedavisi için ortotopik kalp transplantasyonu uygulandı. Alıcı ile verici arasındaki uyumsuzluklar bikaval anastomozun gerginleşmesine neden oldu. Ameliyattan sonra yedinci günde hastada iki taraflı ciddi bacak ödemi gelişti. Onuncu günde sağ kalp kateterizasyonu yapıldı ve kontrast madde injeksiyonu ile birlikte, inferior vena kava ile sağ atriyum arasında anastomoz bölgesinde darlık gözlemlendi. Darlık alanında ortalama basınç gradiyenti 8 mmHg idi. Lezyon bölgesi Tyshak II perkütan valvuloplasti kateteriyle genişletildi. İşlem sonunda ortalama basınç gradiyenti 2 mmHg'ye geriledi ve genişleme venografiyle kontrol edildi. Girişimden birkaç gün sonra hastanın bacaklarındaki ödem geriledi. Böylece, inferior vena kava ile sağ atriyum arasında anastomoz bölgesinde görülen darlığın giderilmesinde pulmoner balon kateteri kullanılarak istenen sonuç elde edilmiş oldu.

**Anahtar sözcükler:** Anjiyoplasti, balon; anastomoz, cerrahi/ komplikasyon; konstriksiyon, patolojik; kalp nakli; vena kava, inferior.

have been reported such as caval stenosis at the anastomosis site.<sup>[2-5]</sup> These stenotic segments may be successfully treated either percutaneously or surgically.<sup>[2-6]</sup>

### CASE REPORT

A 54-year-old man was hospitalized with end-stage dilated cardiomyopathy after several previous admis-

Received: February 21, 2007 Accepted: April 5, 2007

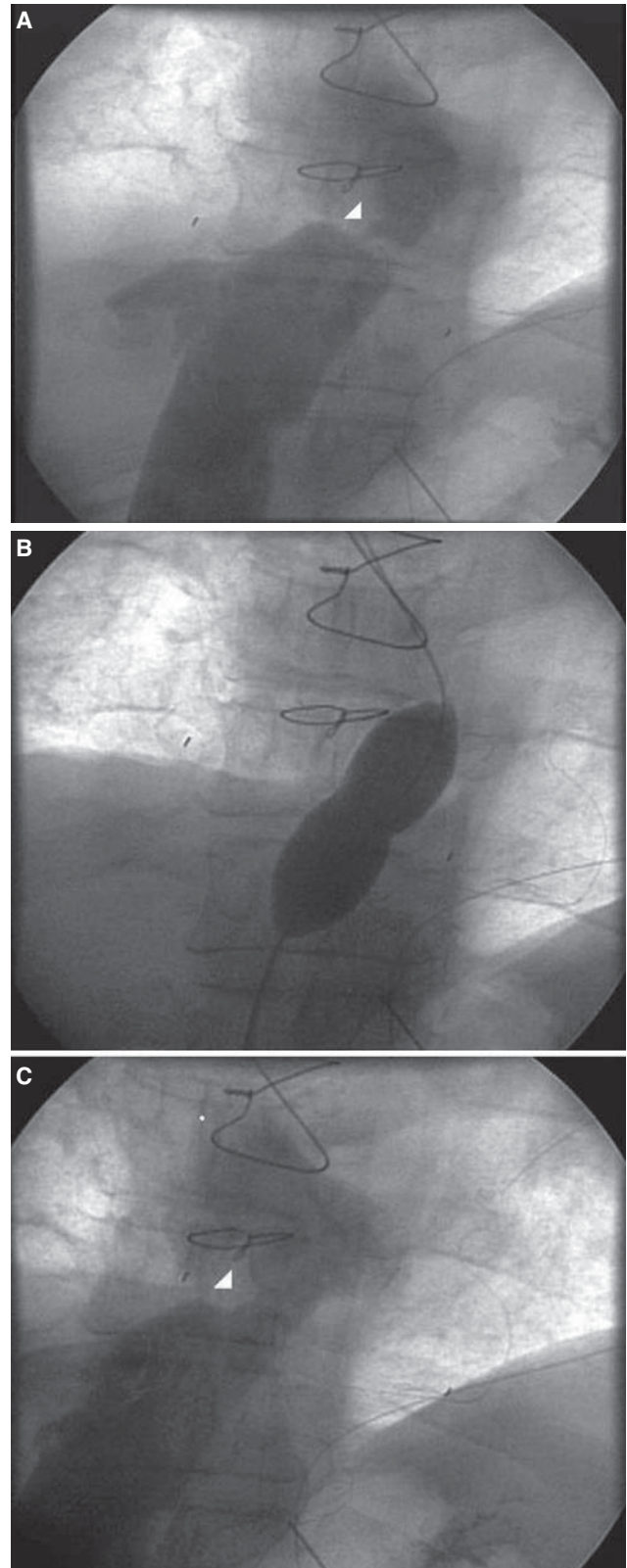
Correspondence: Dr. Serkan Çay, Oba Sok., Hürriyet Apt., No: 11/6, 06480 Cebeci, Ankara.  
Tel: 0312 - 319 65 68 Fax: 0312 - 287 23 90 e-mail: cayserkan@yahoo.com

sions for the treatment of congestive heart failure. The patient was listed for total cardiac transplantation and he underwent orthotopic heart transplantation with total removal of the atria, bicaval end-to-end anastomosis, and anastomosis of the pulmonary veins. Due to size mismatch between the recipient and the donor, bicaval anastomosis became tight operatively. The early postoperative course was uneventful. After seven days postoperatively, the patient developed significant bilateral leg edema. On the tenth postoperative day, he underwent right heart catheterization and endomyocardial biopsy for a possible rejection. With the injection of contrast material, a stricture was seen at the anastomotic line located between the inferior vena cava and the right atrium (Fig. 1a). The mean pressure gradient at the level of the stenosis was 8 mmHg (mean inferior vena cava pressure 11 mmHg, and mean right atrial pressure 3 mmHg). An 8 Fr sheath was placed from the right femoral vein, through which a 0.035" guide wire was advanced. The stenotic segment was dilated using a Tyshak II percutaneous valvuloplasty catheter (NuMED Inc., Canada), 18 mm x 3.0 cm in size. At the end of the procedure, the mean pressure gradient decreased to 2 mmHg (mean inferior vena cava pressure 5 mmHg, mean right atrial pressure 3 mmHg). Venography showed a larger diameter in the stenotic segment (Fig. 1b, c). Leg edema diminished a few days after the procedure.

## DISCUSSION

Despite progressive improvements in surgical techniques of cardiac transplantation, some operative and postoperative complications may develop. Stenosis of the caval system, especially inferior vena cava anastomosis is a rare complication. Stenosis may develop at any time ranging from the early postoperative period to even several years following surgery. Some mechanisms might be responsible for stenosis, including inappropriate vessel size, inadequate surgical technique (suture, etc.), intimal hyperplasia, and hypercoagulable states. In our case, inappropriate vessel size most probably resulted in a stricture at the site of anastomosis. Due to shorter caval parts of the donor heart, end-to-end anastomosis was possible only after applying a tension.

Stenotic lesions related to anastomotic sites may be treated either percutaneously or surgically.<sup>[2-6]</sup> Surgical techniques include aortic allografting, autologous saphenous vein grafting, and polytetrafluoroethylene graft replacement.<sup>[4]</sup> Stenting and balloon angioplasty may be performed for percutaneous treatment. The use of stents, especially Wallstent placement was



**Figure 1.** (A) Venography showing the stenotic segment between the inferior vena cava and the right atrium (arrow head). (B) The stenotic segment was dilated by balloon angioplasty. (C) After dilatation, the diameter of the segment increased and the pressure gradient decreased (arrow head).

described previously.<sup>[3,7]</sup> It has been demonstrated that stenting is superior to balloon angioplasty for long-term patency of venous stenosis.<sup>[8]</sup> However, balloon angioplasty is also useful for the treatment of such strictures. Several types of balloon catheters can be used for dilatation.<sup>[2]</sup> To our knowledge, the use of a pulmonary balloon catheter for the treatment of stenosis in the inferior vena cava-right atrial anastomosis has not been reported previously. The use of stents may result in stent thrombosis, requiring repeat dilatation of the stenotic segment. In our patient, angioplasty with a pulmonary balloon was successful; therefore, the need for repeat dilatation or deployment of a stent was eliminated.

In conclusion, the use of a pulmonary balloon catheter for stenotic lesions at the level of anastomosis line between the inferior vena cava and the right atrium may be considered an alternative treatment modality.

## REFERENCES

1. Dreyfus G, Jebara V, Mihaileanu S, Carpentier AF. Total orthotopic heart transplantation: an alternative to the standard technique. *Ann Thorac Surg* 1991;52:1181-4.
2. Bleasdale RA, Partridge J, Banner NR. Obstruction of the inferior vena cava following total heart lung transplantation: successful treatment by balloon angioplasty. *J Heart Lung Transplant* 2000;19:488-91.
3. Shah M, Anderson AS, Jayakar D, Jeevanandam V, Feldman T. Balloon-expandable stent placement for superior vena cava-right atrial stenosis after heart transplantation. *J Heart Lung Transplant* 2000;19:705-9.
4. Blanche C, Tsai TP, Czer LS, Valenza M, Aleksic I, Trento A. Superior vena cava stenosis after orthotopic heart transplantation: complication of an alternative surgical technique. *Cardiovasc Surg* 1995;3:549-52.
5. Jayakumar A, Hsu DT, Hellenbrand WE, Pass RH. Endovascular stent placement for venous obstruction after cardiac transplantation in children and young adults. *Catheter Cardiovasc Interv* 2002;56:383-6.
6. Koyanagi T, Minami K, Tenderich G, Reiss N, Morshius M, Mirow N, et al. Thoracic and cardiovascular interventions after orthotopic heart transplantation. *Ann Thorac Surg* 1999;67:1350-4.
7. Hennequin LM, Fade O, Fays JG, Bic JF, Jaafar S, Bertal A, et al. Superior vena cava stent placement: results with the Wallstent endoprosthesis. *Radiology* 1995;196:353-61.
8. Shoenfeld R, Hermans H, Novick A, Brener B, Cordero P, Eisenbud D, et al. Stenting of proximal venous obstructions to maintain hemodialysis access. *J Vasc Surg* 1994;19:532-8.