

Successful Bronchial Artery Embolization after Stabilization with Nitric Oxide for the Treatment of Haemoptysis in a Patient with Eisenmenger Syndrome

Eisenmenger Sendromlu Bir Hastada Hemoptizi Tedavisinde Nitrik Oksit ile Stabilizasyon Sonrası Başarılı Bronşiyal Arter Embolizasyonu

CASE REPORT OLGU SUNUMU

ABSTRACT

Hemoptysis, accompanying various chronic lung diseases, some systemic diseases, infections, structural heart diseases, or syndromes is a clinical condition that is quite mortal when it is massive. Hemoptysis is a common complication of Eisenmenger syndrome. Its frequency increases with age. It is an important cause of mortality in patients with Eisenmenger syndrome. Embolization of systemic-pulmonary collateral arteries is an effective method in the treatment of hemoptysis in eligible patients with Eisenmenger syndrome. In this case report, a patient with Eisenmenger syndrome, developed due to large patent ductus arteriosus, received dual pulmonary arterial hypertension-specific treatment, after the development of hemoptysis, medical stabilization was provided with initial inhaled nitric oxide therapy and then treated with bronchial artery embolization without complications is presented.

Keywords: Eisenmenger syndrome, embolization, hemoptysis, nitric oxide

ÖZET

Çeşitli kronik akciğer hastalıklarına, bazı sistemik hastalıklara, enfeksiyonlara, yapısal kalp hastalıklarına veya sendromlara eşlik eden hemoptizi, masif olduğunda oldukça ölümcül olan bir klinik durumdur. Hemoptizi, Eisenmenger sendromunun sık görülen bir komplikasyonudur. Yaşla birlikte sıklığı artar. Eisenmenger sendromlu hastalarda önemli bir mortalite nedenidir. Sistemik-pulmoner kollateral arterlerin embolizasyonu, Eisenmenger sendromlu uygun hastalarda hemoptizi tedavisinde etkili bir yöntemdir. Bu olgu sunumunda, geniş patent duktus arteriyozusa bağlı gelişen ve ikili pulmoner arteriyel hipertansiyona spesifik tedavi alan, Eisenmenger sendromlu bir hastada, hemoptizi gelişmesinden sonra, ilk olarak inhale nitrik oksit tedavisi ile medikal stabilizasyon sağlandıktan sonra komplikasyonsuz şekilde bronşiyal arter embolizasyonu ile tedavi ettiğimiz olgu sunulmaktadır.

Anahtar Kelimeler: Eisenmenger sendromu, embolizasyon, hemoptizi, nitrik oksit

Patients with Eisenmenger syndrome (ES) have a high risk of bleeding, especially pulmonary hemorrhage and hemoptysis, due to both thrombosis risk and platelet and factor deficiency.¹ Hemoptysis in patients with ES occurs due to neovascularization, hilar intercostal collateral arteries, or pulmonary infarction secondary to thrombosis.^{1,2} If the patient has multiple systemic-pulmonary collaterals, embolization can be performed by determining the potential anatomical site. Embolization may be the only treatment for life-threatening severe hemoptysis.³

The annual incidence of hemoptysis in patients with pulmonary arterial hypertension (PAH) due to congenital heart disease and idiopathic PAH is 9.9%.^{4,5} The mortality rate due to hemoptysis of patients with Eisenmenger syndrome is between 11% and 29%.^{4,5} We herein describe a case of a 49-year-old man with ES caused by patent ductus arteriosus (PDA) in whom recurrent hemoptysis was successfully treated with bronchial artery embolization.

Zeynep Ulutaş, M.D. 

Hüseyin Emre Kuloğlu, M.D. 

Ramazan Kutlu, M.D. 

Necip Ermiş, M.D. 

Department of Cardiology, İnönü
University Faculty of Medicine, Malatya,
Turkey

Corresponding author:

Zeynep Ulutaş

✉ drzeynepulutas@gmail.com

Received: December 11, 2021

Accepted: April 21, 2022

Cite this article as: Ulutaş Z, Kuloğlu HE, Kutlu R, Ermiş N. Successful bronchial artery embolization after stabilization with nitric oxide for the treatment of haemoptysis in a patient with Eisenmenger syndrome. *Türk Kardiyol Dern Ars.* 2022;50(6):459-462.

DOI:10.5543/tkda.2022.21304



Available online at archivestsc.com.
Content of this journal is licensed under a
Creative Commons Attribution –
NonCommercial-NoDerivatives 4.0
International License.

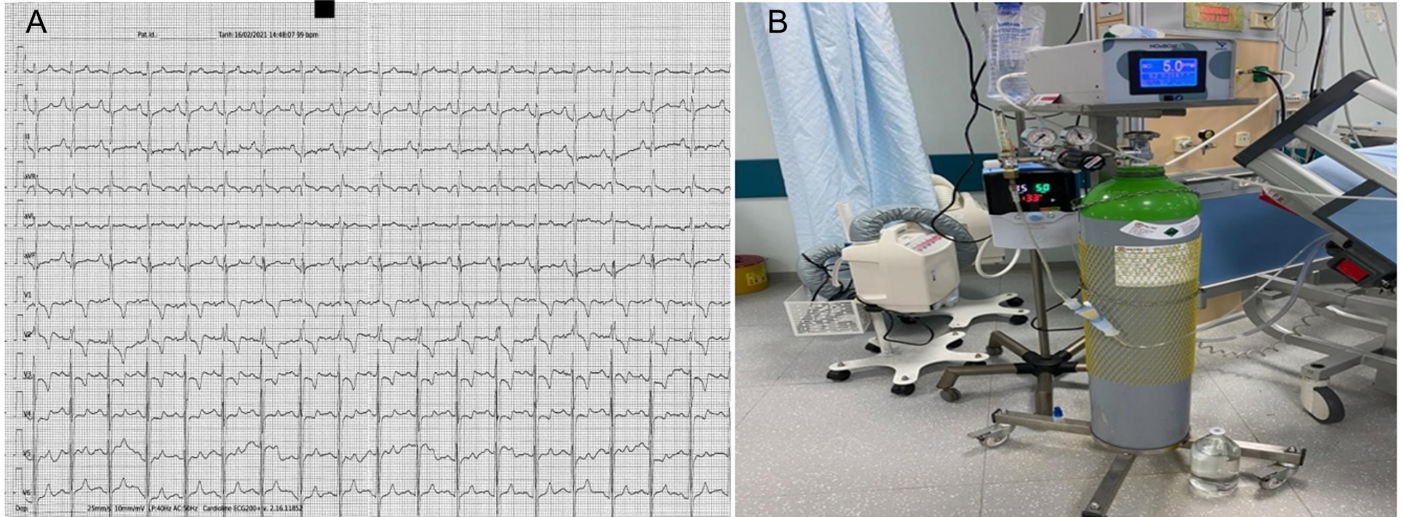


Figure 1. A-B. The ECG on admission to the emergency room: Incomplete RBBB, inverted T waves in leads V1-V2, biphasic T waves in leads V3-V4. There is a negative T wave in D3 (A), inhaled NO therapy is given by a high flow device (B). ECG, electrocardiography; RBBB, right bundle branch block; NO, nitric oxide.

Case Report

A 49-year-old male patient was admitted to the emergency department with the complaint of coughing and bleeding from the mouth, which had been continuing intermittently for a week. The patient had a clinical history of ES associated with a large PDA, which had been followed for 10 years. The clinical course of the patient was stable. He was not using an anticoagulant or antiplatelet drug, and he was on combination of Bosentan 2 × 125 mg/day and Tadalafil 1 × 40 g/day. The amount of his hemoptysis was approximately 400 cm³. On presentation, his blood pressure was 118/87 mmHg, heart rate was 98/min, respiratory rate was 21/min, and oxygen saturation was 89%. He had cyanosis, clubbing, jugular vein distension, pretibial edema, and parasternal lift. His first heart sound was normal, pulmonary component of the second heart sound was augmented, and a pansystolic murmur over the tricuspid focus was detected. Electrocardiography showed sinus tachycardia, incomplete right bundle branch block, and right axis deviation (Figure 1A). Laboratory tests were consistent with secondary erythrocytosis (hemoglobin: 19.9 mg/dL, hematocrit: 61.2%) His N-terminal prohormone brain natriuretic peptide (NT-proBNP) level was 869 pg/mL. Platelets were 139000 µL, and prothrombin time was normal. Arterial blood gas analysis revealed hypoxia (pO₂ 51.8 mmHg), and in the room air, his O₂ saturation was 86%. Thorax computed tomography (CT) on admission showed dilated pulmonary arteries (Figure 2A) and mosaic perfusion appearances in lower lobes (Figure 2B).

Two- and three-dimensional thorax CT showed a large PDA (Figure 3A and B). Aminocaproic acid 250 mg IV treatment was

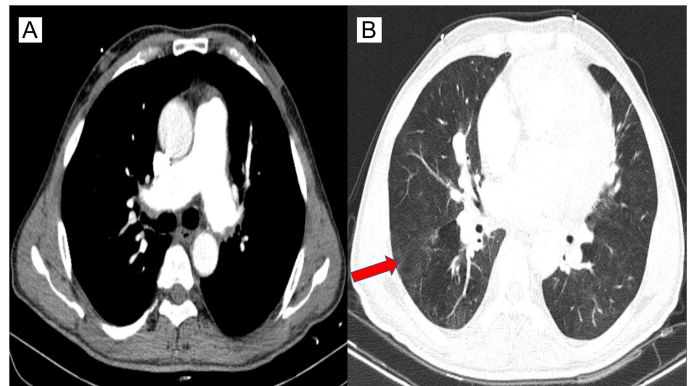


Figure 2. Thorax CT on admission shows dilated pulmonary arteries (A), mosaic perfusion pattern in lower lobes (B). CT, computed tomography.

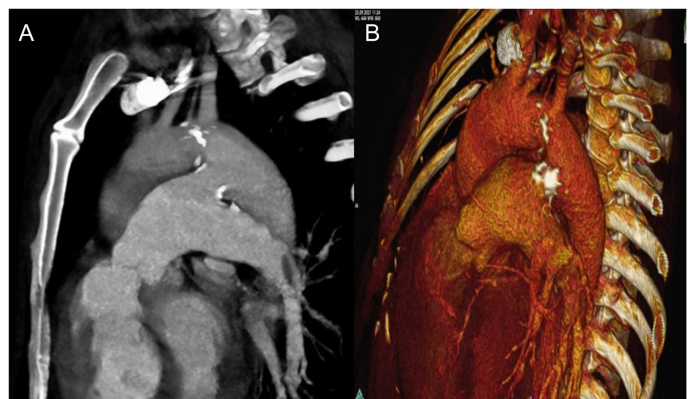


Figure 3. Two- and three-dimensional thorax CT shows a large PDA. CT, computed tomography; PDA, patent ductus arteriosus.

ABBREVIATIONS

CT	Computed tomography
ES	Eisenmenger syndrome
NO	Nitric oxide
NT-proBNP	N-terminal prohormone brain natriuretic peptide
PAH	Pulmonary arterial hypertension
PDA	Patent ductus arteriosus
PVR	Pulmonary vascular resistance
NBCA	N-butyl cyanoacrylate

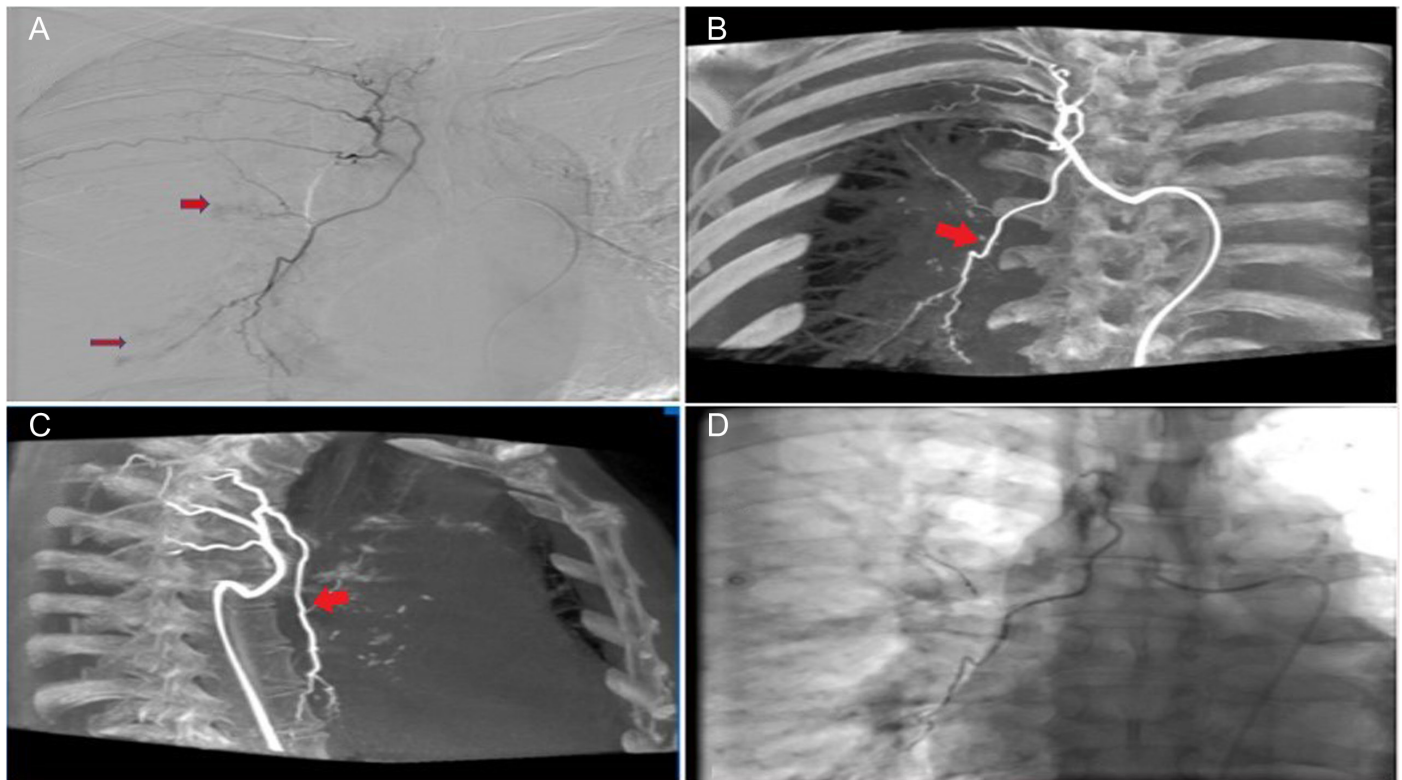


Figure 4. A-D. 4 (A) Selective right costobronchial angiogram with microcatheter shows slightly hypertrophied right bronchial artery and parenchymal stainings. (B, C) Corresponding anteroposterior and lateral maximum intensity projection reconstructions of cone-beam CT images demonstrate the anatomy of right bronchial artery. (D). Angiogram after selective embolization of right bronchial artery with NBCA and lipiodol mixture shows embolized bronchial artery. CT, computed tomography.

administered to the patient in the emergency department. In the coronary intensive care unit, 2 L/min O₂ support was provided, and aminocaproic acid treatment was continued. Inhaled nitric oxide (NO) administration was planned since a rapid effect was desired and augmentation of vasodilator therapy was thought to contribute to clinical stabilization. High flow NO inhalation treatment was started at a concentration of 15 ppm (Figure 1B). After 48 hours of uninterrupted inhalation, it was discontinued at a reduction of 2 ppm per hour. Hemoptysis was not observed during follow-up. Right heart catheterization performed after stabilization revealed a mean pulmonary artery pressure of 110 mmHg, a QP/QS of 1.1, and pulmonary vascular resistance (PVR) was 22.44 Wood U. Inhaled iloprost was added to the medical treatment. Upon development of a massive hemoptysis under medical therapy, bronchial artery embolization was planned. The bronchial arteries of the patient were successfully catheterized with microcatheters (Figure 4A and B). His right bronchial artery was dilated and tortuous. After contrast injection, opaque substance uptake in the parenchyma was noted. The right bronchial artery was considered as the lesion responsible for hemoptysis (Figure 4C). It was successfully embolized under continuous fluoroscopy with a mixture of lipiodol and N-butyl cyanoacrylate (NBCA) (Figure 4D). During in-hospital follow-up, the patient did not develop recurrent hemoptysis and was discharged with inhaled Iloprost. Currently, he is under triple combination therapy with bosentan, iloprost, and tadalafil with normal NT-proBNP levels and a good functional capacity of

NYHA II. His 6-minute walking test was 480 m. Hemoptysis did not recur during the follow-up period of 6 months.

Discussion

Hemoptysis is a common health problem in PAH patients with ES. It is more common in specific types like connective tissue disease-associated pulmonary arterial hypertension, PAH associated with congenital heart disease, and chronic thromboembolic pulmonary hypertension. The severity of hemoptysis changes from mild to fatally severe. The development of recurrent massive hemoptysis can be life-threatening. It often causes a generalized anxiety disorder in patients.

In the multicenter, prospective, observational THALES study involving 1034 patients, the prevalence of ES among congenital heart diseases was 49.2%.⁶ Hemoptysis was observed in 5.2% of ES patients. The chronic bronchial artery hypertrophy in PH causes an increase in the number of bronchial arteries and morphological deterioration. At the same time, the fragility of the pulmonary vascular structure increases. Hemoptysis may also occur due to the effect of excessive volume and pressure overload.⁶ The main factor in the development of hemoptysis in these patients is high pulmonary arterial pressure. There are 3 main goals of managing hemoptysis: prevention of aspiration, interception of bleeding, and treatment of the underlying disease cause.^{7,8} Surgical treatment is considered as the primary treatment option in patients with massive hemoptysis.⁷ Endovascular

embolization treatment is used as a very effective and minimally invasive procedure in selected patients.^{7,8} Around 90% of severe hemoptysis that requires treatment is from bronchial artery, 5% from pulmonary artery, and the remaining 5% of hemorrhages originate from nonbronchial systemic artery.⁹ Bronchial artery embolization is a commonly used endovascular embolization procedure, as bronchial arteries are responsible for massive hemoptysis requiring treatment.^{7,8} Despite the extensive literature on bronchial artery embolization, there are few data on specific efficacy for the treatment of hemoptysis in PH. A study showed that bronchial artery embolization can be an effective and safe procedure for the treatment of acute hemoptysis in PH patients. Bronchial artery embolization in PH is more complex than procedures in patients without PH as there are more anatomical and morphological variabilities in patients with PH. Therefore, a more careful evaluation is required before the procedure. Bronchial artery embolization may be useful for improving hemoptysis control and quality of life in patients with PH who are likely to develop recurrent hemoptysis.¹⁰

The annual incidence of hemoptysis in patients with congenital PAH and idiopathic PAH is 9.9%.¹¹ Vasodilator therapy to reduce pulmonary artery pressure is the most popular treatment modality in patients with PAH.¹² Small clinical studies have shown that inhaled NO can improve hemodynamics by lowering pulmonary artery pressure and increasing cardiac index.¹³ Another study showed that the flow efficiency in the right ventricle is significantly improved on inhaled NO administration.¹⁴ In patients whose symptoms persist or who develop recurrent hemoptysis under medical treatment, inhaled NO therapy can be applied for bridging treatment in the process leading to coil embolization. Nitric oxide shows benefits with its pressure-reducing effect by vasodilation in the pulmonary artery. Its rare side effect is headache. In our patient, it was initiated because hemoptysis had developed despite medical treatment. Bronchial artery coil embolization was performed as a result of recurrence in the period between adding a new drug.

Conclusion

Hemoptysis is an important problem in PAH, especially in patients with ES. Increasing the medical vasodilator therapy is helpful for the initial stabilization of those patients. Inhaled NO is an effective agent that can be used in this situation. Interventional treatment options such as bronchial artery embolization should also be considered in recurrent cases.

Informed Consent: Written informed consent was obtained from the patient who participated in this study.

Peer-review: Externally peer-reviewed.

Author Contributions: Concept – N.E., R.K.; Design – N.E., R.K.; Supervision – N.E., Z.U.; Funding – H.E.K., Z.U.; Materials – Z.U., H.E.K.; Data Collection and/or Processing – N.E., Z.U.; Analysis and/or Interpretation – Z.U., H.E.K.; Literature Review – Z.U., H.E.K.; Writing – Z.U., H.E.K.; Critical Review – Z.U., H.E.K.

Declaration of Interests: The authors declare that they have no competing interest.

Funding: This study received no funding.

References

- Mamas MA, Clarke B, Mahadevan VS. Embolisation of systemic-to-pulmonary collaterals in patients with the Eisenmenger reaction presenting with haemoptysis. *Cardiol Young*. 2008;18(5):528-531. [\[CrossRef\]](#)
- Tamada N, Nakayama K, Shinkura Y, et al. Successful pulmonary artery embolization for the management of hemoptysis in a patient with Eisenmenger syndrome caused by patent ductus arteriosus. *Intern Med*. 2017;56(24):3299-3304. [\[CrossRef\]](#)
- Taçoy G, Başer HD, Türkoğlu S, Cengel A. The management of adult female patients with Eisenmenger syndrome and advanced pulmonary arterial hypertension treatment: single center experience and follow-up for 5 years. *Turk Kardiyol Dern Ars*. 2014;42(6):531-541. [\[CrossRef\]](#)
- Lordan JL, Gascoigne A, Corris PA. The pulmonary physician in critical care * Illustrative case 7: assessment and management of massive haemoptysis. *Thorax*. 2003;58(9):814-819. [\[CrossRef\]](#)
- Chun JY, Morgan R, Belli AM. Radiological management of hemoptysis: a comprehensive review of diagnostic imaging and bronchial arterial embolization. *Cardiovasc Intervent Radiol*. 2010;33(2):240-250. [\[CrossRef\]](#)
- Kücükoglu SM, Kaymaz C, Alehan D, et al. Pulmonary arterial hypertension associated with congenital heart disease: lessons learnt from the large Turkish Nationwide Registry (Thales). *Pulm Circ*. 2021;11(3):20458940211024206. [\[CrossRef\]](#)
- Jean-Baptiste E. Clinical assessment and management of massive hemoptysis. *Crit Care Med*. 2000;28(5):1642-1647. [\[CrossRef\]](#)
- Andersen PE. Imaging and interventional radiological treatment of hemoptysis. *Acta Radiol*. 2006;47(8):780-792. [\[CrossRef\]](#)
- Özkan M, Göl H. Hemoptizi ve Tedavi Stratejileri. *Göğüs Cerrahisi*. Ankara: Sim Matbaacılık; 2003:1123-1139.
- Rasciti E, Sverzellati N, Silva M, et al. Bronchial artery embolization for the treatment of haemoptysis in pulmonary hypertension. *Radiol Med*. 2017;122(4):257-264. [\[CrossRef\]](#)
- Diller GP, Gatzoulis MA. Pulmonary vascular disease in adults with congenital heart disease. *Circulation*. 2007; 115(8): 1039-1050. [\[CrossRef\]](#)
- Cantor WJ, Harrison DA, Moussadji JS, et al. Determinants of survival and length of survival in adults with Eisenmenger syndrome. *Am J Cardiol*. 1999; 84(6): 677-681. [\[CrossRef\]](#)
- Chodakowski JD, Courtney DM. Pulmonary embolism critical care update: prognosis, treatment, and research gaps. *Curr Opin Crit Care*. 2018;24(6):540-546. [\[CrossRef\]](#)
- Schäfer M, Frank BS, Ivy DD, et al. Short-term effects of inhaled nitric oxide on right ventricular flow hemodynamics by 4-dimensional-flow magnetic resonance imaging in children With pulmonary arterial hypertension. *J Am Heart Assoc*. 2021;10(8):e020548. [\[CrossRef\]](#)