

Successful management of left main coronary artery thrombus with intracoronary thrombolysis

Ana koroner arter trombüsünün koroner içi trombolitik uygulaması ile başarılı tedavisi

Ufuk Gürkan, M.D., Mustafa Adem Tatlısu, M.D., Emre Aruğaslan, M.D., Osman Bolca, M.D.

Department of Cardiology, Dr. Siyami Ersek Cardiovascular Surgery Hospital, İstanbul

Summary– The management of valvular heart diseases with mechanical valves has been performed for several years. Warfarin has been used in patients with mechanical heart valves to protect against thromboembolic complications; nevertheless, in these patients, thromboembolic event rates range from 0.5% to 1.7%. Acute occlusive embolism to the coronary arteries due to a mechanical valve is an uncommon occurrence. In this report, we present a case of a left coronary system occlusion due to thrombus embolization from a prosthetic aortic valve, which was successfully treated by thrombolytic therapy.

The management of valvular heart diseases with mechanical valves has been performed for several years. Acute occlusive embolism to the coronary arteries due to mechanical valve continues to be seen in our clinical practice despite the use of warfarin therapy.

In this case report, we present a case of a left coronary system occlusion due to thrombus embolization from a prosthetic aortic valve, which was successfully treated with thrombolytic therapy.

CASE REPORT

A 47-year-old man, who had undergone aortic valve replacement for rheumatic disease 11 years before, was admitted with shortness of breath and angina lasting about 10 hours. He underwent invasive coronary angiography due to positive electrocardiographic exercise stress testing, and epicardial coronary

Özet– Yapısal kapak hastalıklarının tedavisinde yapay mekanik kapaklar yıllardır kullanılmaktadır. Varfarin tromboembolik komplikasyonlara karşı korumak için mekanik kalp kapağı olan hastalarda kullanılmaktadır, buna rağmen bu hastalarda %0.5-1.7 oranında tromboembolik olaylar görülmektedir. Yapay mekanik kapağa bağlı akut tıkaçıcı koroner embolisi de nadir olarak görülmektedir. Bu yazıda, düzensiz varfarin kullanım öyküsü olan bir hastada yapay mekanik aort kapaktan kaynaklanan emboli sonucu gelişen yaygın sol koroner sistem trombozu saptanan ve başarılı trombolitik uygulaması ile tedavi edilen olgu sunuldu.

arteries were angiographically normal. On presentation, his blood pressure was 75/55 mmHg in the right arm and 70/50 mmHg in the left arm. On physi-

cal examination, widespread fine crepitant rales were heard over both lungs. The 12-lead electrocardiogram showed ventricular tachycardia, and then sinus rhythm was obtained after synchronized electrical cardioversion with 50 joules. The second 12-lead electrocardiogram showed ST-segment elevation in leads aVR and V1 through V6. The transthoracic echocardiogram (TTE) showed impaired anterior and anterolateral wall motion and impaired left ventricular systolic function (ejection fraction <25%). TTE also showed a normally functioning

Abbreviations:

IABP	Intra-aortic balloon pump
INR	International normalized ratio
LAD	Left anterior descending
LMCA	Left main coronary artery
PCI	Percutaneous coronary intervention
TEE	Transesophageal echocardiogram
tPA	Tissue plasminogen activator
TTE	Transthoracic echocardiogram

Received: November 16, 2013 Accepted: February 27, 2014

Correspondence: Dr. Ufuk Gürkan. Dr. Siyami Ersek Göğüs Kalp ve Damar Cerrahisi Eğitim ve Araştırma Hastanesi, Tıbbiye Cad., No: 13, Haydarpaşa, 34668 İstanbul.

Tel: +90 216 - 542 44 44 e-mail: drufukgurkan@gmail.com

© 2014 Turkish Society of Cardiology



prosthetic aortic valve. Transaortic peak and mean gradients were 18 mmHg and 9 mmHg, respectively. Notwithstanding the high sensitivity of transesophageal echocardiogram (TEE) to evaluate prosthetic heart valve function, TEE could not be used in this case due to hemodynamic instability and the need for urgent revascularization. The international normalized ratio (INR) was 0.98 at admission. He was transferred to the catheterization laboratory immediately for primary percutaneous coronary intervention (PCI). Intra-aortic balloon pump (IABP) was inserted for hemodynamic support. The coronary angiography revealed a massive thrombus not only in the distal left main coronary artery (LMCA) but also at the ostium of the left circumflex coronary artery and intermediate branch with totally occluded left anterior descending (LAD) coronary artery (Figure 1). Slow flow was seen in the right coronary artery. Fluoroscopy confirmed normal motion of the prosthetic valve leaflets. Due to the widespread thrombus, we preferred intracoronary fibrinolysis (tissue plasminogen activator, tPA) to aspiration thrombectomy. He had no contraindication to fibrinolysis. First, 15 mg tPA was administered into the coronary artery; then, 50 mg tPA was administered intravenously over 30 minutes; and finally, 35 mg tPA was administered intravenously over the next 60 minutes. Heparin was administered simultaneously with tPA infusion. After 10 minutes, TIMI (Thrombolysis in Myocardial Infarction) flow grade 3 in the LAD was seen during the second coronary angiography (Figure 2a).

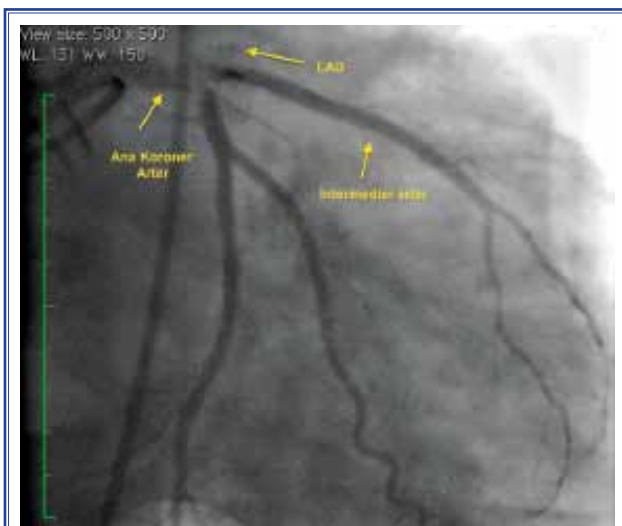


Figure 1. Intracoronary thrombus in the LMCA and totally occluded LAD with absent flow.

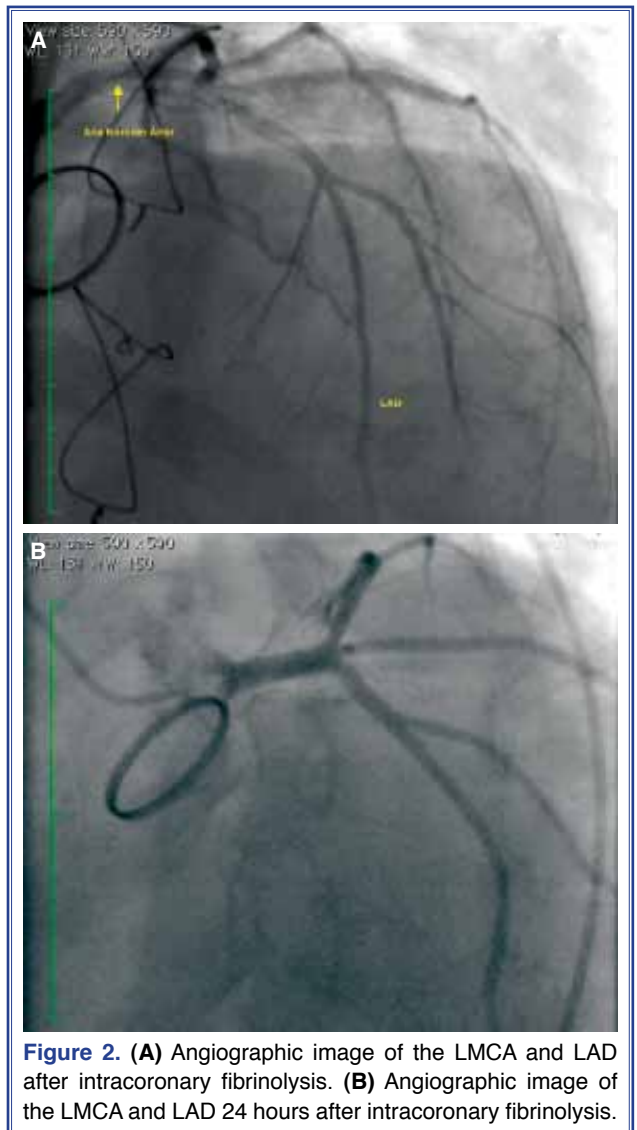


Figure 2. (A) Angiographic image of the LMCA and LAD after intracoronary fibrinolysis. (B) Angiographic image of the LMCA and LAD 24 hours after intracoronary fibrinolysis.

Reperfusion led to rapid hemodynamic improvement and reduction in the symptoms of angina, and he was then transferred to the coronary care unit. Resolution of ST-segment elevation was seen 90 minutes after thrombolysis. TEE confirmed normal prosthetic aortic valve function. IABP support was stopped, and the third coronary angiography was performed 24 hours after admission. Coronary angiography revealed normal coronary arteries (Figure 2b). The therapeutic INR range (2.5-3) was achieved, and the patient was discharged. The patient was seen one month after discharge, and TTE revealed impaired anterior wall motion and left ventricular systolic function (ejection fraction: 35%) and normally functioning prosthetic aortic valve.

DISCUSSION

Incidence of acute myocardial infarction due to a thrombotic occlusion of the unprotected LMCA is approximately 0.8-1.7%.^[1] Cardiogenic shock most commonly occurs as a complication of LMCA thrombus. The usual cause of LMCA obstruction is atherosclerotic occlusion resulting from plaque rupture and subsequent thrombus formation. Other causes reported are embolism, aortic dissection, pulmonary artery compression, and vasospasm.^[2] Our patient had no risk factors for coronary artery disease. Due to irregular warfarin use and ineffective INR values, we considered embolism to the coronary artery from the prosthetic aortic valve thrombus. Even with the use of warfarin, incidence of major systemic embolism was found as 2% in patients with heart valve replacement.^[3] Moreover, embolus to the LMCA can be seen in patients with prosthetic heart valve without evidence of thrombus.^[1-4] Aspiration thrombectomy was used effectively in these cases. Due to the distal left main stem thrombus extending into the ostium of the LAD and the intermediate vessel, we preferred intracoronary tPA to aspiration thrombectomy. With the advances in PCI, clinical use of intracoronary thrombolytic therapy has declined steadily. However, some publications still suggest intracoronary thrombolysis for widespread thrombus in the LMCA.^[6] In addition to the success of thrombolytic therapy in prosthetic heart valve thrombosis, this therapy can be chosen in patients with left main stem thrombus.^[4,7-9] In this case, subsequent diagnostic coronary angiography demonstrated normal coronary arteries.

In conclusion, in the case of left main stem thrombosis, intracoronary fibrinolysis can be preferred to aspiration thrombectomy due to the high risk of distal embolization.

Conflict-of-interest issues regarding the authorship or article: None declared.

REFERENCES

1. Prasad SB, Whitbourn R, Malaiapan Y, Ahmar W, MacIsaac A, Meredith IT. Primary percutaneous coronary intervention for acute myocardial infarction caused by unprotected left main stem thrombosis. *Catheter Cardiovasc Interv* 2009;73:301-7.
2. Patel M, Bhangoo M, Prasad A. Successful percutaneous treatment of suspected embolic left main thrombosis in a patient with a mechanical aortic valve. *J Invasive Cardiol* 2011;23:E263-6.
3. Cannegieter SC, Rosendaal FR, Briët E. Thromboembolic and bleeding complications in patients with mechanical heart valve prostheses. *Circulation* 1994;89:635-41. [CrossRef](#)
4. Yazici M, Kayrak M, Turan Y, Koc F, Ulgen MS. Acute coronary embolism without valve thrombosis in a patient with a prosthetic mitral valve--successful percutaneous coronary intervention: a case report. *Heart Surg Forum* 2007;10:228-30.
5. Jaffe R, Shiran A, Rubinshtein R. Left main coronary artery occlusion due to thrombus embolization from a prosthetic mitral valve. *JACC Cardiovasc Interv* 2013;6:43-4. [CrossRef](#)
6. Seth A. "Once upon a time there was ... intracoronary thrombolysis". *Catheter Cardiovasc Interv* 2011;78:76-7. [CrossRef](#)
7. Ozkan M, Kaymaz C, Kirma C, Sönmez K, Ozdemir N, Balkanay M, et al. Intravenous thrombolytic treatment of mechanical prosthetic valve thrombosis: a study using serial transesophageal echocardiography. *J Am Coll Cardiol* 2000;35:1881-9. [CrossRef](#)
8. Özkan M, Gündüz S, Biteker M, Astarcioglu MA, Çevik C, Kaynak E, et al. Comparison of different TEE-guided thrombolytic regimens for prosthetic valve thrombosis: the TROIA trial. *JACC Cardiovasc Imaging* 2013;6:206-16. [CrossRef](#)
9. Özkan M, Çakal B, Karakoyun S, Gürsoy OM, Çevik C, Kalçık M, et al. Thrombolytic therapy for the treatment of prosthetic heart valve thrombosis in pregnancy with low-dose, slow infusion of tissue-type plasminogen activator. *Circulation* 2013;128:532-40. [CrossRef](#)

Key words: Acute myocardial infarction; aortic valve, mechanical; thrombolytic therapy/methods.

Anahtar sözcükler: Akut miyokart enfarktüsü; aort kapağı, mekanik; trombolitik tedavi/yöntem.