

CASE REPORT

Pheochromocytoma: An overlooked reversible cause of heart failure with reduced ejection fraction

Feokromasitoma: Düşük ejeksiyon fraksiyonlu kalp yetmezliğinin gözden kaçan geri döndürülebilir bir nedeni

Ali Çoner, M.D.¹ , Ali Gökhan Özyıldız, M.D.² 

¹Department of Cardiology, Başkent University Hospital Alanya Application and Research Center, Antalya, Turkey

²Department of Cardiology, Recep Tayyip Erdoğan University Training and Research Hospital, Rize, Turkey

Summary– Pheochromocytoma is a rare, benign tumor of adrenal medulla, and its clinical symptoms are related to catecholamine production. Clinical presentation may vary in a broad spectrum. Dilated or hypertrophied cardiomyopathies are the possible clinical outcomes of pheochromocytoma. Pheochromocytoma should be kept in mind in the differential diagnosis where resistant hypertension, palpitations, headache, and sweating accompany cardiomyopathy. Excessive adrenergic stimulation causing catecholamine discharge can trigger hypertension crisis, pulmonary edema, and myocardial necrosis. Here in this report, we aimed to present the case of a patient with pheochromocytoma related cardiomyopathy who was totally recovered after surgical excision of the tumor.

Özet– Feokromasitoma benign karakterde olup katekolamin salınımı ile klinik semptomlar oluşturan adrenal medulla ile ilişkili nadir görülen bir tümördür. Hastaların klinik prezentasyonları oldukça değişken bir spektrum gösterebilir. Dilate veya hipertrofik kardiyomiyopati feokromasitomanın olası klinik sonuçlarından biridir. Kalıcı hipertansiyon, çarpıntı, baş ağrısı ve terleme kardiyomiyopatiye eşlik ediyorsa, ayırıcı tanıda feokromasitoma akılda bulundurulmalıdır. Katekolamin deşarjına neden olan aşırı adrenerjik uyarı, hipertansif krizi, pulmoner ödemi ve miyokardiyal hasarı tetikleyebilir. Bu yazıda cerrahi tedavi sonrasında kardiyomiyopatının tamamen gerilediği feokromasitoma hastasının sunumunu yapmayı amaçladık.

Pheochromocytoma is a rare neuroendocrine tumor, and its symptoms are related to excess and abrupt increase in catecholamine levels. The classical triad is palpitation, excess sweating, and headache; however, this triad is observed in only 24% of all patients with pheochromocytoma.^[1] A small proportion of patients may admit with catecholamine related cardiomyopathy. Cardiogenic shock, circulatory collapse, and multiorgan failure are the worse clinical presentations of this context, and mortality is expected at these stages.^[2] In the present case, we aimed to present a pheochromocytoma related moderate cardiomyopathy patient recovered after surgical excision of adrenal mass.

CASE REPORT

A 60-year-old female patient was admitted to the emergency department with uncontrolled blood pressure (220/110 mmHg) and flushed pulmonary edema.

Her electrocardiography (ECG) revealed sinus rhythm with T wave inversions at V3 to V6 (Figure 1) and high sensitive troponin level of 212.3 pg/mL (reference level was 0-16.0 pg/mL). On transthoracic echocardiography (TTE), left ventricular ejection fraction (LVEF) was calculated as 43%, with a hypokinesis at lateral wall apical segment, apex, and posterior wall ½ basal segments (Video 1 and 2*). Posterolateral wall hypertrophy was also detected with a 14-mm thickness of involved segments in parasternal long-axis and 4-chamber views. No apical ballooning similar to that in Takotsubo syndrome was detected. Coronary angiography was performed after compensation of heart failure, and no significant coronary artery lesion was determined. For differential diagnosis of secondary hypertension, renal ultrasonography was performed,

Abbreviations:

ECG	Electrocardiography
LVEF	Left ventricular ejection fraction
MRI	Magnetic resonance imaging
TTE	Transthoracic echocardiography

Received: December 1, 2020 Accepted: February 16, 2021

Correspondence: Ali Çoner, M.D., Department of Cardiology,

Başkent University Hospital Alanya Application and Research Center, Antalya, Turkey

Tel: +90 553 978 94 00 e-mail: conerali@hotmail.com

© 2021 Turkish Society of Cardiology



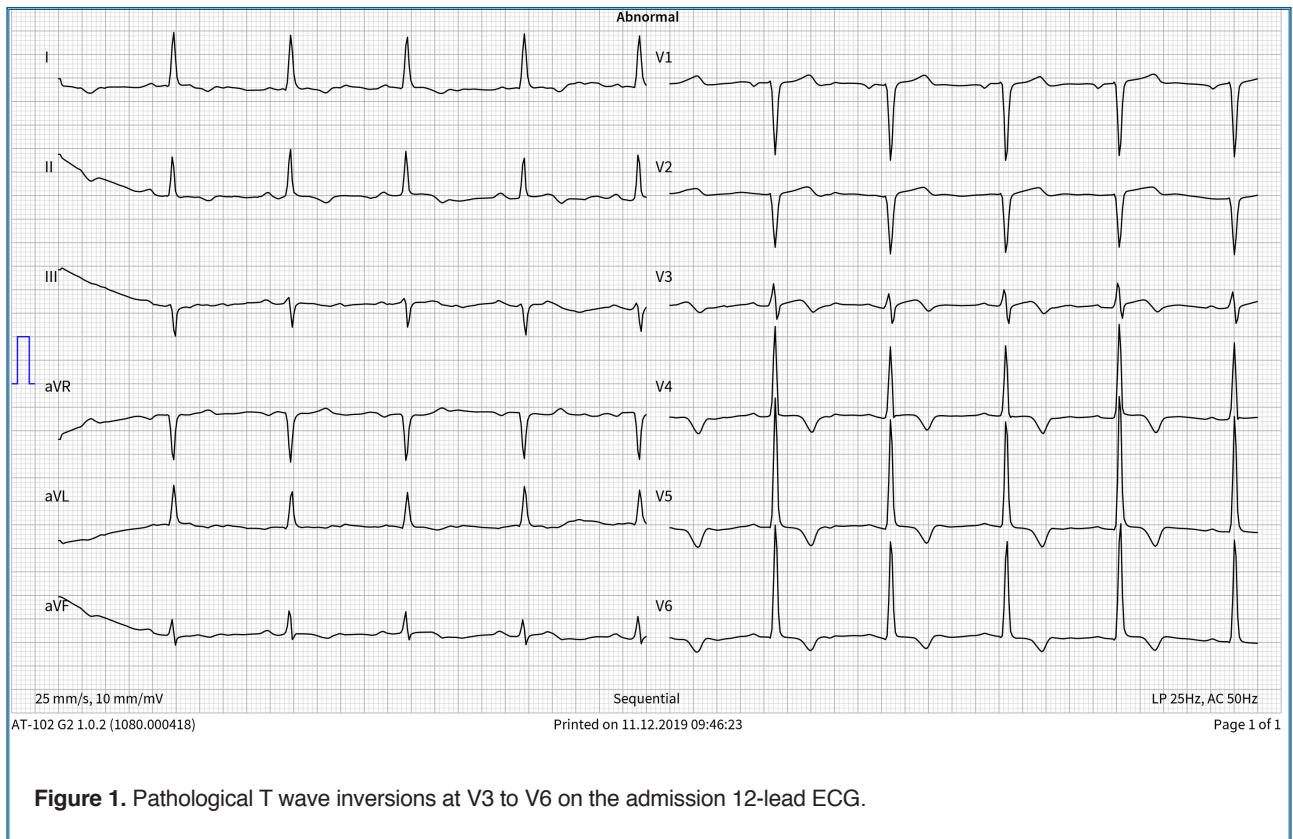


Figure 1. Pathological T wave inversions at V3 to V6 on the admission 12-lead ECG.

and an adrenal mass in the left kidney lodge was detected. A detailed hormonal analysis was performed to evaluate the metabolic activity of the adrenal mass. The patient's aldosterone level while standing and cortisol level in the morning were normal. Plasma 3-metoxytiramine and free metanephrine levels were within the reference range. Plasma free normetanephrine level was 6.28 nmol/L, and it was higher than normal reference limits (0.12-1.18 nmol/L). Urine daily metanephrine and its ratio to creatinine in 24 hours were 546.1 $\mu\text{g}/\text{day}$ and 712.7 $\mu\text{g}/\text{g}$, respectively (reference limits; 30-180 μg , 29-158 $\mu\text{g}/\text{g}$). Magnetic resonance imaging (MRI) confirmed a 30-mm mass in the left adrenal gland. Surgical excision was planned; 10 days before surgery, doxazosin 2 mg per day was started, and 3 days later, propranolol 20 mg thrice per day was added to treatment. Pathological evaluation confirmed the diagnosis of pheochromocytoma. Medical treatment was planned as ramipril 2.5 mg per day and metoprolol 50 mg per day.

At third month control postoperatively, the patient's ECG revealed mild T wave inversions in chest leads, and LVEF was calculated as 51% on echocardiography. The patient was asymptomatic, and ramipril and metoprolol medication was continued in the

third-month follow-up. At the end of her first year postoperatively, the patient was still asymptomatic with class-I exercise capacity. Patient's ECG revealed recovery of previous T wave inversions with a normal R wave progression in chest leads (Figure 2). On echocardiography, LVEF was calculated as 63% with a LV end-diastolic diameter of 49 mm. Posterolateral ventricular wall thickness was 12 mm (Video 3 and 4*). Ramipril and metoprolol medication was stopped because of the recovery of LVEF.

DISCUSSION

Pheochromocytoma is also known as the great imitator because of its broad spectrum of symptoms. Despite the introduction of advanced diagnostic tools in clinical practice, patients with pheochromocytoma have an average delay of 3 years from the start of symptoms to the time of diagnosis.^[3]

Catecholamine metabolism is summarized in Figure 3. Plasma fractionated metanephrine level and urine fractionated metanephrine excretion in 24-hour urine collection have a high sensitivity and specificity for diagnosis.^[4] More than 2 times increase in plasma or urinary 24-hour metanephrine is con-

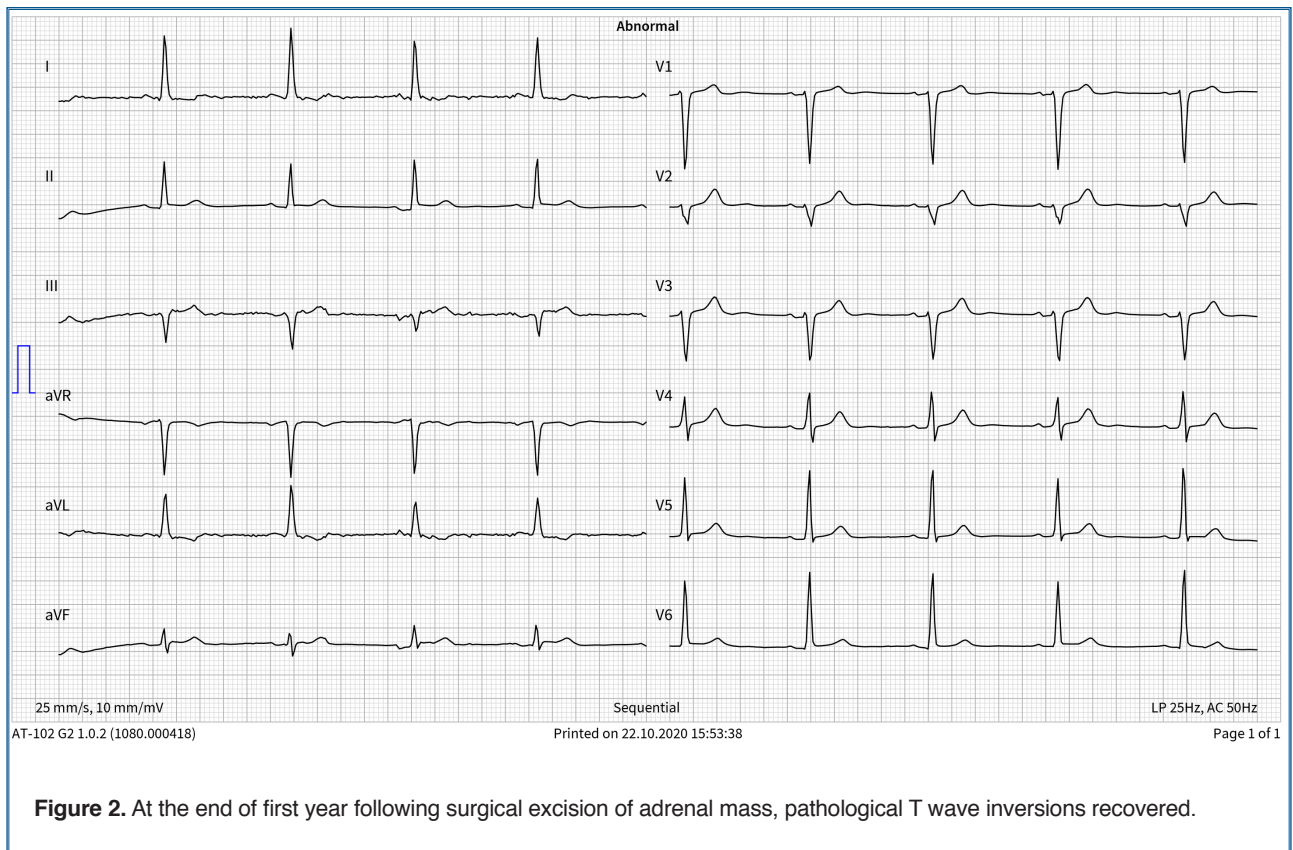
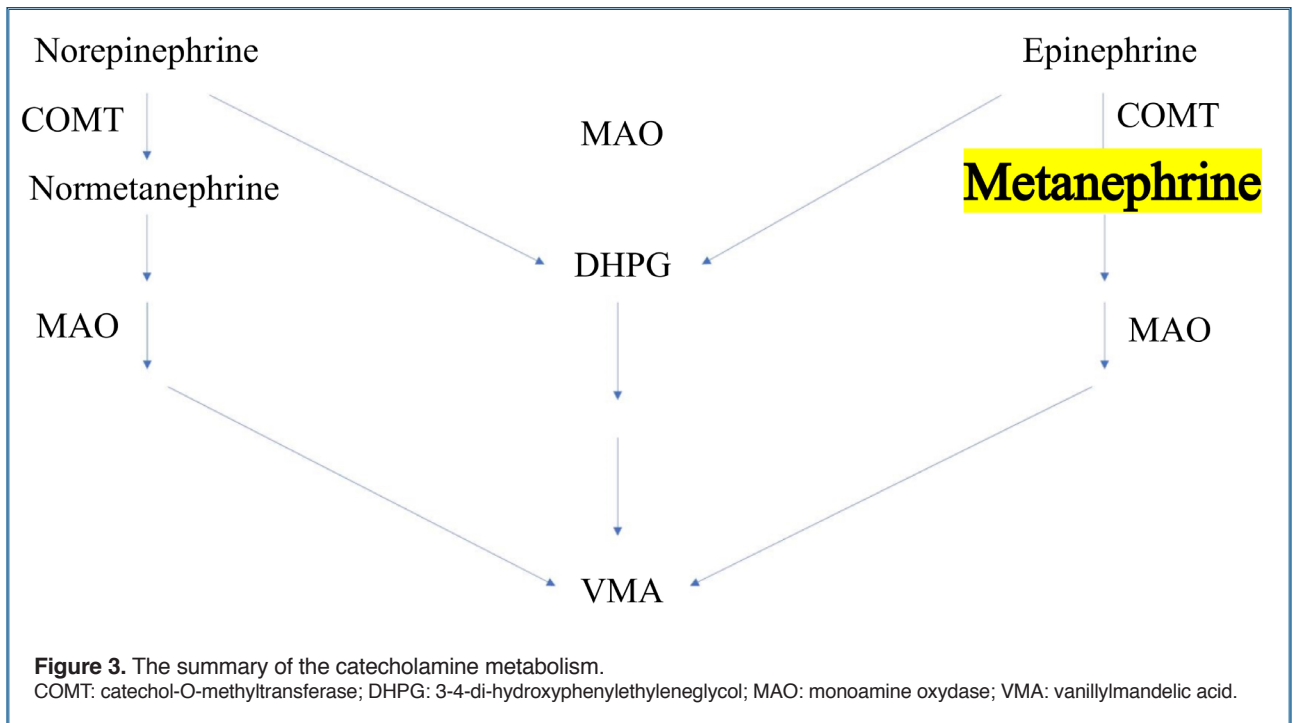


Figure 2. At the end of first year following surgical excision of adrenal mass, pathological T wave inversions recovered.

sistent with a metabolically active adrenal mass; therefore, further imaging modalities should be undertaken in these circumstances. In the current case, urinary metanephrine excretion in 24 hours was more than 2 times the upper limits, and MRI confirmed the diagnosis.

Surgical excision is the recommended treatment option for patients with pheochromocytoma. However, there are various medical treatment recommendations regarding the preoperative preparation of patients in the current guidelines.^[5] Preoperative blockade of hormonally functional pheochromocytoma is essential in the prevention of cardiovascular complications. Blood pressure and heart rate should be controlled preoperatively. An alpha-blocker should be started 10 to 14 days before the operation, and a beta-blocker should be added after 2 to 3 days. It should be kept in mind that premature start of beta-blocker may trigger unopposed alpha receptor stimulation and hypertensive crisis. The last doses of oral alpha-blocker and beta-blocker should be given on the morning of the operation. Additionally, for the prevention of postoperative hypotension, salt consumption should be encouraged to increase blood volume in the preoperative period.

Excess catecholamine level in pheochromocytoma is related to different cardiomyopathies, including hypertrophied, dilated, or Takotsubo syndrome.^[6] Catecholamine-related secondary Takotsubo syndrome is a rare clinical presentation of pheochromocytoma, and its incidence was less than 3% in metabolically active patients.^[7] In the present case, we detected a hypertrophied cardiomyopathy with a posterolateral wall involvement. Pheochromocytoma should be kept in mind in miscellaneous cardiomyopathies if symptoms such as resistant hypertension, palpitation attacks, headache, and abnormal sweating coexist.^[8] Excess adrenergic stimulation in these patients is related to hypertension crisis, pulmonary edema, and myocardial involvement.^[9] Catecholamine increase can be responsible for myocardial injury through several mechanisms. The direct toxic effect of catecholamines on myocytes and the triggering of imbalance between myocardial oxygen demand and supply are the leading ones. Catecholamine-related vasospasm and increased platelet aggregation are the primary mechanisms in reducing myocardial oxygen supply.^[10] Ventricular hypertrophy and myocarditis are less pronounced mechanisms of catecholamine related myocardi-



al injury. We observed a reversible left ventricular hypertrophy and systolic dysfunction in the current case. The possible reason was that the chronic catecholamine discharge and the adrenochrome, developed by oxidation of epinephrine with tyrosine, had a reduced contractile force and necrotic effect on the myocardium by inhibiting calcium-binding.

In conclusion, because complications are reversible with treatment, pheochromocytoma should be kept in mind in patients with cardiomyopathy if additional symptoms such as excess sweating, resistant hypertensive crisis, and headache coexist. Surgical excision is the recommended approach in these patients ending with an excellent clinical follow-up.

*Supplementary video files associated with this article can be found in the online version of the journal.

Informed consent: Informed consent was obtained from the patient for the publication of the case report and the accompanying images.

Peer-review: Externally peer-reviewed.

Authorship contributions: Concept - A.Ç.; Design - A.Ç., A.G.Ö.; Supervision - A.G.Ö.; Materials - A.Ç.; Data - A.Ç.; Literature search - A.Ç., A.G.Ö.; Writing - A.Ç.; Critical revision - A.G.Ö.

Conflict-of-interest: None.

REFERENCES

1. Gu YW, Poste J, Kunal M, Schwarcz M, Weiss I. Cardiovascular manifestations of pheochromocytoma. *Cardiology Rev* 2017;25:215-222. [\[Crossref\]](#)
2. Chen X, Liu X, Tian S, Wang X, Tang H, Yu Y, et al. Cardiac arrest and catecholamine cardiomyopathy secondary to a misdiagnosed ectopic pheochromocytoma. *Endokrynol Pol* 2020;71:479-80. [\[Crossref\]](#)
3. Galetta F, Franzoni F, Bernini G, Poupak F, Carpi A, Cini G, et al. Cardiovascular complications in patients with pheochromocytoma: a mini-review. *Biomed Pharmacother* 2010;64:505-9. [\[Crossref\]](#)
4. Perry CG, Sawka AM, Singh R, Thabane L, Bajnarek J, Young Jr WF. The diagnostic efficacy of urinary fractionated metanephrines measured by tandem mass spectrometry in detection of pheochromocytoma. *Clin Endocrinol (Oxf)* 2007;66:703-8. [\[Crossref\]](#)
5. Lenders JW, Duh QY, Eisenhofer G, Gimenez-Roqueplo AP, Grebe SK, Murad MH, et al. Pheochromocytoma and paraganglioma: an endocrine society clinical practice guideline. *J Clin Endocrinol Metab* 2014;99:1915-42. [\[Crossref\]](#)
6. Batisse-Lignier M, Pereira B, Motreff P, Pierrard R, Burnot C, Vorillon C, et al. Acute and chronic pheochromocytoma-induced cardiomyopathies: different prognoses? A systematic analytical review. *Medicine (Baltimore)* 2015;94:e2198. [\[Crossref\]](#)
7. Gagnon N, Mansour S, Bitton Y, Bourdeau I. Takotsubo-like cardiomyopathy in a large cohort of patients with pheochromocytoma and paraganglioma. *Endocr Pract* 2017;23:1178-92. [\[Crossref\]](#)
8. Rostoff P, Krawczyk K, Krupinski M, Majda A, Golinska-Grzybala K, Kiecana J, et al. Catecholamine-induced

- secondary Takotsubo syndrome in a patient with pheochromocytoma and synchronous papillary renal cell carcinoma. *Kardiologia Polska* 2020;78:784-5. [\[Crossref\]](#)
9. Rostoff P, Nessler B, Pikul P, Golinska-Grzybala K, Miszalski-Jamka T, Nessler J. Fulminant adrenergic myocarditis complicated by pulmonary edema, cardiogenic shock and cardiac arrest. *Am J Emerg Med* 2018;36:344.e1-344.e4. [\[Crossref\]](#)
10. Prejbisz A, Lenders JWM, Eisenhofer G, Januszewicz A. Cardiovascular manifestations of phaeochromocytoma. *J Hypertens* 2011;29:2049-60. [\[Crossref\]](#)

Keywords: Pheochromocytoma; cardiomyopathies; adrenal gland neoplasms

Anahtar Kelimeler: Feokromasitoma; kardiyomiyopatiler; adrenal bezi tümörleri