

Catheter Ablation of Anteroseptal, Midseptal and Para-Hisian Accessory Pathways: How Risky?

Prof. Dr. Kâmil ADALET, Doç. Dr. Fehmi MERCANOĞLU, Uzm. Dr. Alpay SEZER, Dr. Kerem ÖZER, Prof. Dr. Mehmet MERİÇ, Prof. Dr. Faruk ERZENGIN

Istanbul Faculty of Medicine, Department of Cardiology, Istanbul, Turkey

ANTEROSEPTAL, MİDSEPTAL VE PARAHİSİAN AKSESUAR YOLLARIN ABLASYONU: NE KADAR RİSKLİ?

ÖZET

AV düğüme yakın aksesuar yolların radyofrekans kateter ablasyonu (RFA) AV tam bloka yol açabilir ve kalıcı pacemaker implantasyonu gerekebilir. Bu komplikasyondan kaçınmak için muhtelif metodlar (juguler yaklaşım, güç ya da ısının tedrici artırılması gibi) önerilmiştir. Bu çalışmada, femoral veya vena kava superior yaklaşımı ve tedrici ısı arttırımı metodu ile RFA yapılan anteroseptal (AS), midseptal (MS) veya Parahisian (PH) aksesuar yolu 36 hasta (Grup I: 11 kadın, 25 erkek; ort. yaş. 30.1±11.7 yıl) ile diğer bölgelerde aksesuar yolları bulunan 215 hastadaki (Grup II: 87 kadın, 128 erkek; ort. yaş. 37.3±13.9 yıl) ablasyon sonuçları karşılaştırıldı. Multipl aksesuar yollu hastalar çalışma kapsamı dışında tutuldu. Her iki grubun yaş ortalaması, cinsiyet dağılımı, semptom süresi, daha önce kullanılan ve etkisiz kalan antiaritmik ilaçların sayısı farklı değildi. RFA süresi, fluoroskopi süresi, verilen akım sayısı ve ortalama ısı da benzerlik gösterdi. Grup I'deki başarı oranı (%94) ve Grup II'deki başarı oranı (%96) istatistiki olarak farklı bulunmadı. Senkop ya da presenkop tanımlayan hastaların oranı Grup I'de (%100), Grup II'ye (%45) nispetle çok daha fazla idi ($p<0.001$). Grup I'de daha çok komplikasyon gözlemlendi (sırası ile %11 ve %2.7, $p<0.05$). Parahisian aksesuar yollu bir hastada AV tam blok (%2.7) ve anteroseptal aksesuar yollu başka bir hastada geçici PR uzaması (% 2.7) gözlemlendi. Bu tür komplikasyon Grup II'de hiçbir hastada oluşmadı. Grup I'de hiçbir hastada nüks gelişmesine karşın, Grup II'deki 17 hastada (%8) nüks oluştu. Sonuç olarak, düşük, ancak kayda değer oranda AV tam blok riski olduğu için, AS, MS veya PH aksesuar yolu bulunan hastalarda ani ölüm riski yüksek olduğunda ya da ciddi semptomlar varsa RFA ablasyonunun uygulanması gerektiği kanısına varıldı.

Anahtar kelimeler: Ablasyon, septal aksesuar yol, WPW sendromu

Radiofrequency catheter ablation (RFA) therapy is commonly used for the curative treatment of symptomatic patients with atrioventricular (AV) accessory pathways (1-5). The location of accessory

pathways (APs) may be anywhere at the septum, the right free wall or the left free wall along the AV annulus except the mitral annular area between the left and right fibrous trigones (6). The treatment of septal APs with RFA has been recognized to be more difficult because these pathways may be located in close proximity to the AV node-His bundle conduction system. The procedure carries a significant risk of complete AV block when the ablation of anteroseptal, midseptal and para-Hisian pathways is attempted (3, 7-10). The efforts to protect AV conduction may prolong the procedure and influence the immediate and long-term success of RFA. In this prospective study, we compare the results of RFA in our patients with anteroseptal, midseptal and para-Hisian APs to those of patients with APs in other locations.

PATIENTS and METHODS

Patients: Two hundred fifty-one consecutive patients (98 female, 153 male; mean age 34.3±12.1 years) with only one atrioventricular AP treated with RFA were included in the study between May 1992 and April 2000. There were 3 patients with hypertrophic obstructive cardiomyopathy and 2 patients with Ebstein's anomaly. The patients were symptomatic for several years and recurrent episodes of AV reentrant tachycardia and/or atrial fibrillation were documented. The tachyarrhythmias could not be controlled with drug therapy. A written or verbal informed consent was obtained from all patients before invasive procedures were performed. The study protocol was approved by the Ethics Committee of our institution.

Electrophysiologic study: All antiarrhythmic drugs were discontinued for at least 5 half-lives. Amiodarone was stopped for at least 2 weeks. Electrophysiologic studies were performed using standard catheterization techniques. From the right and left femoral vein, multipolar electrode catheters were positioned in the right atrium, right ventricular apex, coronary sinus and across the tricuspid valve for recording the His bundle potential. Anterograde and retrograde conduction and refractory properties of the atrioventricular node and the accessory pathway were measured. The presence and location of the accessory pathway and the presence of AV reentrant tachycardias involving accessory pathways were determined.

Radiofrequency catheter ablation: A temperature controlled, 7F quadripolar steerable catheter with a 4 mm distal electrode (EPT Blazer-T or Medtronic Marinr) was used for RFA. Transvenous atrial approach through the femoral vein was preferred for the ablation of right-sided pathways including antero-septal and midseptal pathways. If successful ablation could not be performed through this route, basilic or subclavian veins were used to reach the right atrium. The ablation of left-sided pathways including left posteroseptal pathways were performed with retrograde arterial approach via the femoral artery. In case of failure with this technique, the AP was ablated using antegrade transeptal approach. Some epicardial APs required application of RF energy inside the coronary sinus including the middle cardiac veins.

Mapping with the ablation catheter around the mitral and tricuspid annuli was performed during sinus rhythm or atrial pacing and during orthodromic AV reentrant tachycardia or ventricular pacing. A stable local electrogram showing the AP potential, continuous activity, or an A-V interval shorter than 40 ms with a V wave at least 5 ms earlier than the delta wave during sinus rhythm or atrial pacing indicated a good site for energy delivery. During orthodromic AV reentrant tachycardia or ventricular pacing, the site of ablation was determined by recording the AP potential or continuous activity or the presence of a V-A interval shorter than 40 ms. Normalization of the surface ECG, prolongation of AV and VA intervals to normal limits, disappearance of AP potential indicated successful ablation of the AP. The electrophysiologic study was repeated after 30 minutes to confirm the absence of antegrade and retrograde AP conduction: The programmed stimulation failed to induce orthodromic or antidromic tachycardia even after isoproterenol challenging.

The power of the radiofrequency generator (Atackr, Medtronic or EP System) was adjusted to 40-50 Watts to produce a maximal temperature of 70°C at the tip of the catheter for the ablation of right and left free wall and posteroseptal pathways. On the contrary, a strategy consisting of stepwise increase of radiofrequency energy and short periods (5-10 seconds) of energy delivery was preferred for the ablation of antero-septal, midseptal and para-Hisian pathways to avoid AV block. The temperature was limited to 40°C at the beginning of the procedure followed by stepwise increments of 10°C after every failed attempt up to 70°C. The RF current delivery was immediately terminated if sustained atrioventricular dissociation was observed or the tip of the ablation catheter was displaced. In some cases, Schwartz or Mullins sheaths were used for catheter stabilization. The energy delivery was prolonged up to 60 seconds at the successful ablation site.

Location of the accessory pathway: The position of the ablation catheter at the successful ablation site was recorded in posteroanterior, 30 degrees right anterior oblique and 45 degrees left anterior oblique projections. The successful ablation sites, which show the locations of the APs, were grouped into eight anatomical zones around the mitral and tricuspid annuli (Figure 1). Pathways ablated on the right side of the heart were localized to five regions (anteroseptal, midseptal, right posteroseptal, right anterolateral and right posterolateral), and left-sided pathways

were localized to three regions (left posteroseptal, left anterolateral, left posterolateral).

Accessory pathways that were located at the right anterior portion of the ventricular septum anterior to the catheter recording the His bundle potential were defined as antero-septal pathways. A midseptal pathway was identified when the successful ablation site was along the septal portion bounded by the tip of the His bundle catheter anteriorly and the coronary sinus ostium posteriorly marked by the coronary sinus catheter. Pathways located in the His bundle area were defined as para-Hisian pathways. A para-Hisian pathway was considered when a prominent His bundle potential (>0.1 mV) was recorded at the site of earliest retrograde atrial activation during orthodromic AV reentrant tachycardia (8-11). Accessory pathways situated around or posterior to the orifice of the coronary sinus were defined as right posteroseptal pathways. A left posteroseptal pathway was identified when the site of ablation was within 1-1.5 cm of the coronary sinus ostium marked by the poles of the coronary sinus catheter. The right and left free wall pathways were separated in two groups as anterolateral and posterolateral pathways. The boundary separating these regions was defined as the midpoint of the respective annulus in the 45 degrees left anterior oblique projection (9 o'clock position for the tricuspid annulus, 3 o'clock position for the mitral annulus) (Figure 1).

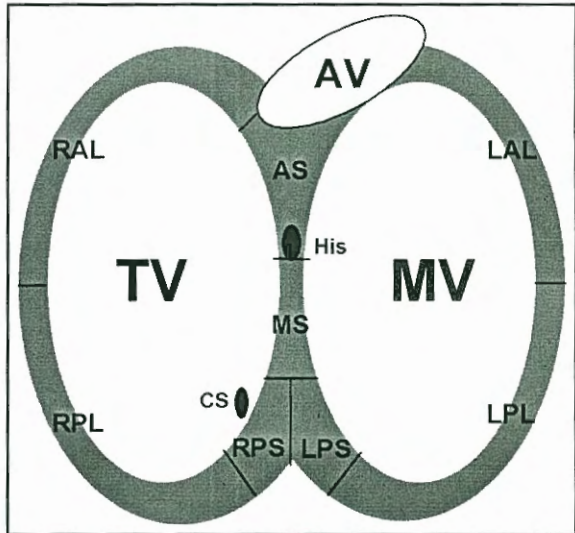


Figure 1. Anatomic localisation of accessory pathways

Statistical analysis. Results are expressed as mean + SD. The data were compared using Student's t test and chi-square test. A p value <0.05 was considered statistically significant.

RESULTS

Clinical characteristics: The clinical characteristics of the patients in Group I and Group II are shown in Table 1. A slight, but statistically significant difference exists between the ages of the patients in Gro-

up I and II (30.1±11.7 years vs 37.3±13.9 years, respectively; p=0.02). In addition, significantly more patients presented with syncope or presyncope in Group I compared to Group II (100% vs 45%, respectively, p<0.001). There were no significant differences between Group I and Group II with respect to sex distribution, symptom duration, and number of administered drugs.

Table 1. Clinical characteristics of the patients in Group I and Group II

	Group I (n=36)	Group II (n=215)	P
Age (years)	30.1±11.7	37.3±13.9	0.024
Female/Male	11/25	87/128	NS
Symptom duration (months)	78.6±93.6	115±123.5	NS
Syncope/Presyncope	36/36 (100%)	98/215 (45%)	<0.001
# of administered drugs	2±1.2	1.2±1.3	NS

NS: not significant, #: number

Location of the accessory pathways: In group I, there were 27 (75%) patients with anteroseptal pathways, 5 (13.9%) patients with midseptal pathways and 4 (11.1%) patients with para-Hisian pathways. In group II, the APs were located to the right anterolateral region in 8 (3.7%) patients, to the right posterolateral region in 20 (9.3%) patients, to the right posteroseptal region in 45 (20.9%) patients, to the left posteroseptal region in 20 (9.3%) patients, to the left posterolateral region in 27 (12.5%) patients, and to left anterolateral region in 95 (44.1%) patients.

Radiofrequency catheter ablation data: The data about the duration and technical aspects of the procedure are listed in Table 2. Total duration of the procedure, RFA duration, and fluroscopy duration were similar in both groups. In addition, a significant difference was also not observed in the parameters of radiofrequency energy application, namely number of energy deliveries, total time of energy delivery, total power, mean power, maximal temperature, and mean temperature.

The success rate of RFA was similar in both groups. The procedure was successful in 94% of the patients in Group I and in 96% of the patients in Group II. Two pathways (1 para-Hisian, 1 anteroseptal) in Group I and 9 pathways (1 right posterolateral, 2 right posteroseptal, 2 left posteroseptal, and 4 left

Table 2. Radiofrequency catheter ablation data: Procedure duration and technical aspects

	Group I (n=36)	Group II (n=215)	P
RFA duration (min)	55.4±55.3	63.8±64.9	NS
Total procedure duration (min)	132.1±63.6	137±75.2	NS
Fluroscopy duration (min)	32.2±22.1	35.4±31.1	NS
# of energy deliveries	9.5±11.2	12.1±15.4	NS
Mean temperature (°C)	51.5±4.7	55.9±7.1	NS

NS: not significant, min: minutes, sec: seconds, #: number

anterolateral) in Group II could not be ablated although different approaches and techniques were tried. Retrograde arterial approach via the femoral artery was successful in 121 (85.2%) of 142 left-sided pathways in Group II. In 8 (5.6%) patients with left-sided pathways transeptal puncture was performed to reach the left atrium, and all of these left-sided pathways could be successfully ablated with this approach. Epicardial APs in 7 (4.9%) patients required application of RF energy inside the coronary sinus including the middle cardiac veins. Thirty (83.3%) of 36 patients with para-Hisian, anteroseptal and midseptal pathways in Group I could be ablated with the femoral approach, and the switch to the vena cava superior approach in 6 patients with unsuccessful procedures increased the success of RFA to 94.4% without causing any complications.

Complications: The complications of RFA that have occurred in our patients include permanent complete AV block, transient prolongation of PR interval, right bundle branch block, pericardial effusion and ventricular fibrillation, thrombus formation in left ventricle and small haematoma (Table 3). The left ventricular thrombus resolved 3 months after anticoagulant therapy. Significantly more complications were observed in Group I compared to Group II (11% vs 2.7%, respectively, p<0.05). Impairment of AV node-His bundle conduction was present only in Group I: Permanent complete AV block occurred in one case with a para-Hisian pathway, and transient prolongation of PR interval lasting for 10 minutes was observed in another case with a anteroseptal pathway. A permanent pacemaker was implanted to the patient with complete heart block.

The intracardiac recording and radiosopic views of catheters in a patient with Parahisian accessory pathway were shown in Figure 2 and 3, respectively.

Table 3. Complications of radiofrequency catheter ablation therapy

Complications	Group I (n=36)	Group II (n=215)	p
Permanent AV block	1 (2.7%)	0 (0%)	
Transient long PR interval	1 (2.7%)	0 (0%)	
Right bundle branch block	1 (2.7%)	2 (0.9%)	
Pericardial effusion, VF	0 (0%)	1 (0.4%)	
Left ventricular thrombus	0 (0%)	1 (0.4%)	
Small haematoma	1 (2.7%)	2 (0.8%)	
TOTAL	4 (11%)	6 (2.7%)	<0.05

AV: atrioventricular, VF: ventricular fibrillation

Follow-up: The patients in Group I were followed for a mean period of 32.7±24.1 months and those in Group II for 29.9±23.3 months (p>0.05). Recurrence

of AP conduction was not observed in any patient in Group I. On the contrary, recurrence was diagnosed in 17 (8.2%) of 207 successfully ablated patients in Group II. All of them were successfully reablated in a second session.

DISCUSSION

The results of this study indicate that RFA of antero-septal, midseptal and para-Hisian pathways can be performed with similar success rates and similar procedure duration as observed in APs located to other sites. Radiation exposure and number of energy deliveries were also similar in both groups of our study. The close anatomic relation of antero-septal, midseptal and para-Hisian pathways with the AV node- His bundle conduction system did not influence the success or the duration of the procedure. On the other

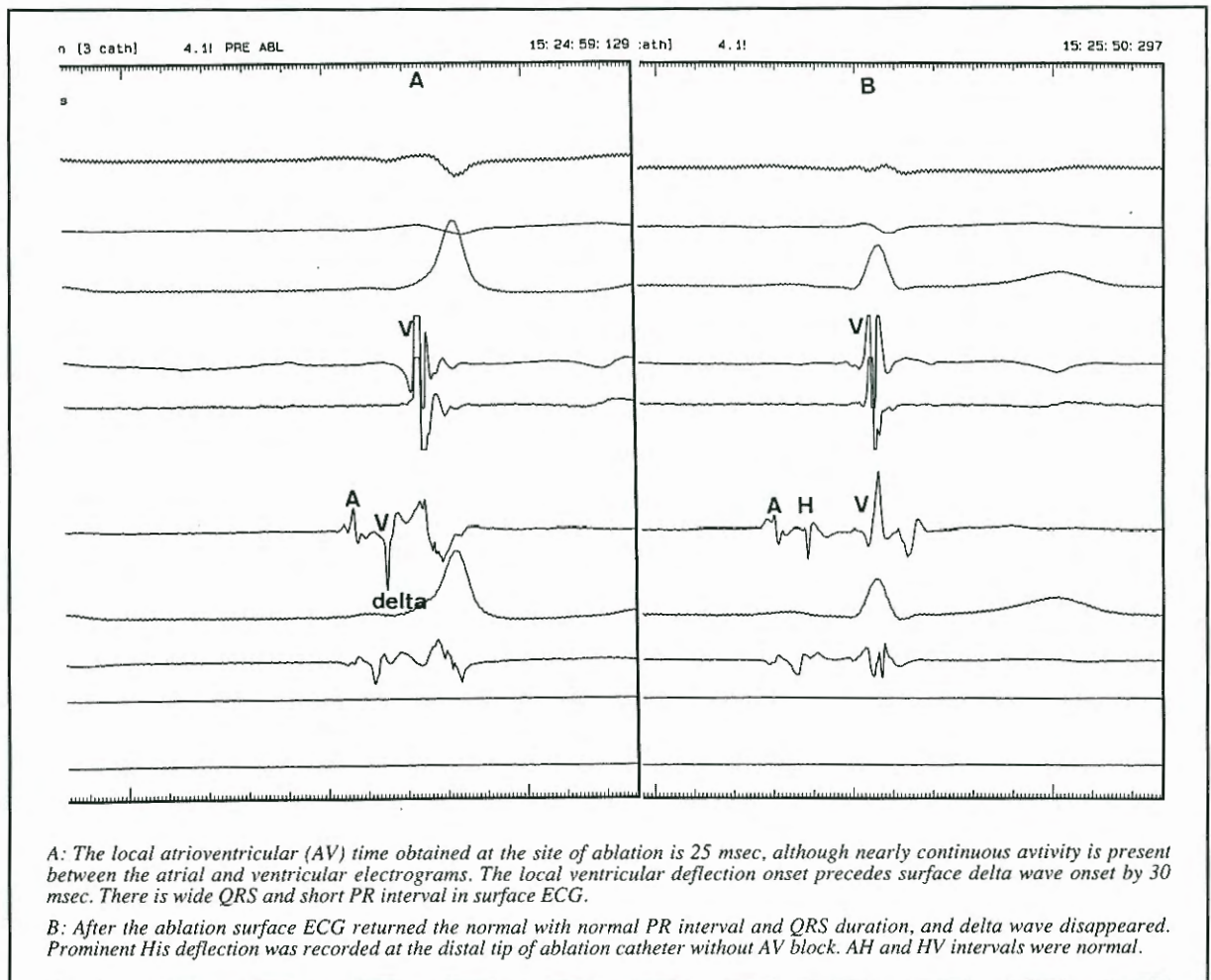


Figure 2. The simultaneous recordings of surface electrogram and intracardiac deflections before (A) and after (B) ablation in a patient with parahisian accessory pathway during sinus rhythm. Abbreviations: A: Atrial deflection, H: His deflection, V: Ventricular deflection.

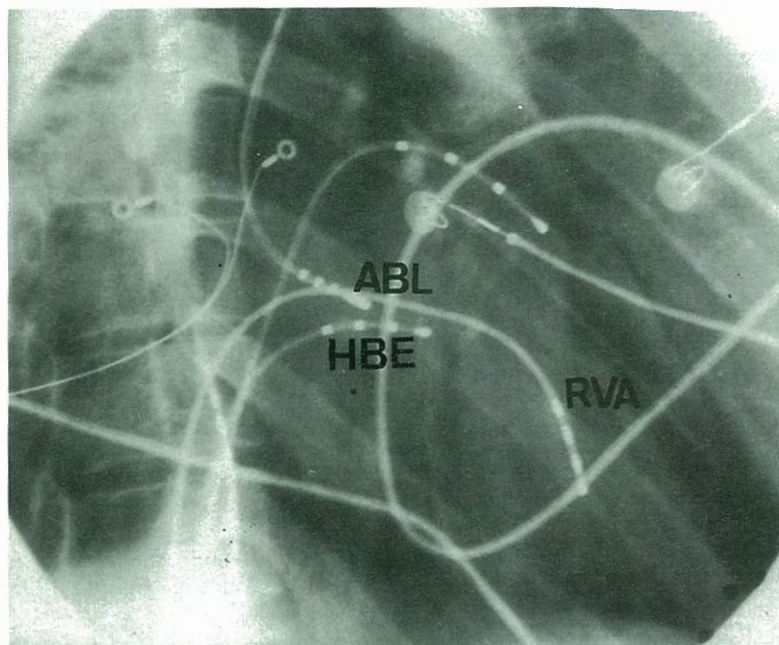


Figure 3. An ablation catheter descends from the superior vena cava is positioned in close proximity to the His bundle in posteroanterior view. HBE: His bundle, RVA: right ventricular apex, ABL: Ablation catheter.

hand, the anatomic position of these pathways had an obvious impact on the occurrence of complications during RFA. Impairment of the AV conduction system including complete AV block was observed only in patients with para-Hisian or anteroseptal accessory pathways. Consequently, a significantly higher complications rate was observed in patients with anteroseptal, midseptal and para-Hisian pathways (11% vs 2.7%). Thus, our experience suggests that ablation of anteroseptal, midseptal and para-Hisian pathways carries a greater risk compared to APs in other locations. Therefore, RFA of these pathways should be considered in patients with a high risk of sudden death or with severe symptoms. The occurrence of syncope or presyncope in all patients in Group I reflects the selection of such high risk patients for interventional therapy.

Some of the earlier studies demonstrated relatively low success rates (71-80%) for the ablation of anteroseptal and midseptal pathways accompanied with a very high incidence of AV conduction disturbances (3,8). In a series of 14 patients with midseptal pathways, the incidence of complete AV block was 36% (8). In another study, complete AV block developed in 2 (20%) of 10 patients with anteroseptal pathways (3). However, other investigators reported

that RFA of APs located in the anteroseptal, midseptal and para-Hisian regions could be performed as effectively as APs in other locations with preservation of the AV conduction system in the majority of the patients (7,9-12). The success rate of RFA for the anteroseptal-midseptal area exceeded 90% in most of the series, and complete AV block occurred in up to 4.3% of the patients (Table 4). We obtained similar results in our study group: The procedure was successful in 94% of patients with anteroseptal, midseptal and para-Hisian pathways and complete AV block developed in only one patient (2.7%).

Various techniques including the use of jugular approach, stepwise increase of power or temperature, and

early termination of energy delivery after failed attempts have been proposed to avoid AV conduction impairment during RFA of anteroseptal, midseptal and para-Hisian pathways (9-11). In our laboratory we use the following techniques and precautions: First we insert Mullins or Schwartz sheaths if catheter stabilization could not be obtained with conventional sheaths during femoral approach. Second, we switch to superior vena cava approach if catheter stability and good contact with safe ablation sites could not be achieved with the femoral approach even after using long sheaths. Eighty-three percent of the pathways in Group I could be ablated with the femoral approach, and the switch to the superior vena cava approach increased the success of the procedure to 94% without causing any complications. Third, we use continuous temperature monitoring with stepwise increase of the temperature from 40°C to 70°C, and we limit the duration of energy application to 10 seconds for each step (9,11). This method reduces the amount of tissue damaged with RF energy and provides protection from irreversible AV block until the best place for safe energy delivery is found. In addition, the RF current delivery is terminated immediately if sustained atrioventricular dissociation is observed. Fourth, continuous fluoroscopic monitoring of catheter position during energy delivery in poste-

Table 4. Comparison of reported data about radiofrequency catheter ablation of anteroseptal, midseptal and para-Hisian accessory pathways

	Publication year	Number of patients	Accessory pathway location	Success of the procedure (%)	Complete AV block (%)
Calkins (3)	1992	10	AS	80	20
Kuck (12)	1992	6	MS	100	0
Yeh (8)	1994	14	MS	71	36
Xie (7)	1994	26	AS,MS	77	3.8
Haissaguerre (11)	1994	8	PH	100	0
Tai (10)	1996	46	AS,MS,PH	100	4.3
Brugada (9)	1998	97	AS,MS,PH	91	2
Adalet (Present study)	2001	36	AS,MS,PH	94	2.7

AS: anteroseptal, MS: midseptal, PH: para-Hisian

ro-anterior projection is a part of our practice so that the application of RF current can be stopped immediately if displacement of the ablation catheter is observed. Finally, it is our practice to start the ablation attempts at sites which are relatively not close to the compact AV node and His bundle, and to get closer to these structures after failed attempts. All these efforts seems to reduce AV block in patients with anteroseptal, midseptal and para-Hisian pathways, but complete prevention of this complication is not possible. The experience of the operator is an important factor for the outcome of the procedure (13).

CONCLUSION

Radiofrequency catheter ablation therapy should be considered in patients with anteroseptal, midseptal or para-Hisian accessory pathways if there is a high risk of sudden death or there are severe symptoms since the procedure itself carries a low (2.7%), although significant risk of complete AV block.

REFERENCES

1. Jackman WM, Wang XZ, Friday KJ, et al: Catheter ablation of accessory atrioventricular pathways (Wolff-Parkinson-White syndrome) by radiofrequency current. *N Engl J Med* 1991; 324:1605-11
2. Kuck KH, Schlüter M, Geiger M, Siebels J, Duckeck W: Radiofrequency current catheter ablation of accessory atrioventricular pathways. *Lancet* 1991; 337:1557-61
3. Calkins H, Langberg J, Sousa J, et al: Radiofrequency catheter ablation of accessory atrioventricular connections in 250 patients. Abbreviated therapeutic approach to Wolff-Parkinson-White Syndrome. *Circulation* 1992; 85:1337-46

4. Lesh MD, Van Hare GF, Schamp DJ, et al: Curative percutaneous catheter ablation using radiofrequency energy for accessory pathways in all locations: results in 100 consecutive patients. *J Am Coll Cardiol* 1992; 19:1303-9

5. Adalet K, Mercanoğlu F, Bilge AK, et al: Radyofrekans kateter ablasyonu uygulanan supraventriküler taşikardili hastalarda erken ve uzun süreli takip sonuçlarının karşılaştırılması. XV. Ulusal Kardioloji Kongresi, October 9-12, İzmir, Turkey, Abstract Book 1999, p 225.

6. Cox JL, Gallagher JJ, Cain ME: Experience with 118 consecutive patients undergoing operation for the Wolff-Parkinson-White syndrome. *J Thorac Cardiovasc Surg* 1985; 90:490-501

7. Xie B, Heald SC, Bashir Y, Camm AJ, Ward DE: Radiofrequency catheter ablation of septal accessory atrioventricular pathways. *Br Heart J* 1994; 72:281-4

8. Yeh SJ, Wang CC, Wen MS, et al: Characteristics and radiofrequency ablation therapy of intermediate septal accessory pathway. *Am J Cardiol* 1994; 73:50-6

9. Brugada J, Puigfel M, Mont L, et al: Radiofrequency ablation of anteroseptal, para-hisian, and mid-septal accessory pathways using a simplified femoral approach. *PACE* 1998; 21[Pt. I]:735-41

10. Tai CT, Chen SA, Chiang CE, Lee SH, Chang MS: Electrocardiographic and electrophysiologic characteristics of anteroseptal, midseptal and para-hisian accessory pathways. Implications for radiofrequency catheter ablation. *Chest* 1996; 109:730-40

11. Haissaguerre M, Marcus F, Poquet F, et al: Electrocardiographic characteristics and catheter ablation of parahisian accessory pathways. *Circulation* 1994; 90:1124-28

12. Kuck KH, Schlüter M, Gürsoy S: Preservation of atrioventricular nodal conduction during radiofrequency current catheter ablation of midseptal accessory pathways. *Circulation* 1992; 86:1743-52

13. Calkins H, El-Atassi R, Kalbfleisch SJ, Langberg JJ, Morady F: Effect of operator experience on outcome of radiofrequency catheter ablation of accessory pathways. *Am J Cardiol* 1993; 71:1104-5