

CASE REPORT

Is the use of low molecular weight heparin a rational choice during pregnancy in patients with a mechanical heart valve: a report of three cases

Mekanik kalp kapaklı hastalarda gebelik sırasında düşük molekül ağırlıklı heparin kullanımı akılcı seçim mi?: Üç olgu sunumu

Ahmet Güner, M.D., Emrah Bayam, M.D., Semih Kalkan, M.D., Sabahattin Gündüz, M.D., Mehmet Özkan, M.D.

Department of Cardiology, Kartal Koşuyolu High Speciality Training and Research Hospital, İstanbul, Turkey

Summary—Pregnancy is associated with an increased risk of valve thrombosis in patients with a mechanical prosthetic heart valve. The administration of low molecular weight heparin (LMWH) with regular anti-factor Xa assessment is a recommended treatment modality for these patients. Presently described are 3 cases of therapy with LMWH during pregnancy. Despite frequent anti-factor Xa monitoring, not surprisingly, all of them developed prosthetic valve thrombosis.

Özet—Gebelik, mekanik protez kalp kapak trombozu riski ile ilişkilidir. Düşük molekül ağırlıklı heparin (LMWH) kullanan hastalar için düzenli anti-faktör Xa değerlendirmesi önerilmektedir. Burada, gebelik sırasında LMWH ile tedavide üç olgu sunmaktayız. Düzenli anti-faktör Xa monitörizasyonu altında şaşırtıcı olmayan bir şekilde hepsinde protez kapak trombozu gelişti.

Mechanical heart valves (MHVs) are highly thrombogenic, and a pregnancy-induced procoagulant status increases the risk of MHV thrombosis up to 10%. Hence, optimal anticoagulation

Abbreviations:

AVR	Aortic valve replacement
INR	International normalized ratio
LMWH	Low molecular weight heparin
MHV	Mechanical heart valve
PVT	Prosthetic valve thrombosis
TEE	Transesophageal echocardiography
T-PA	Tissue plasminogen activator
TTE	Transthoracic echocardiography
UFH	Unfractionated heparin
VKA	Vitamin-K antagonist

is of particular importance in pregnant women with a MHV. The optimal type, dose, and route of anticoagulation therapy, however, remains unclear. Some of the proposed regimens include unfractionated heparin (UFH), low molecular weight heparin (LMWH), and vitamin-K antagonists (VKA). Each of these may be used either alone throughout the pregnancy, or in combination, with 1 regimen administered in the first trimester and another for the remainder of the pregnancy. Regardless of the therapy used, both the mother

and the fetus remain at risk of adverse outcomes.^[1] Although the most recent guidelines recommend the use of LMWH with anti-factor Xa follow-up in the first trimester, the risk of prosthetic valve thrombosis (PVT) is still a concern, as described in the following case series.

CASE REPORT

Case 1 – A 36-year-old female who was 27 weeks pregnant presented at the emergency department with recently progressive dyspnea and fatigue. She had undergone aortic valve replacement (AVR) (No.19; St. Jude Medical, Inc., St. Paul, MN, USA) for a bicuspid aortic valve 8 years prior and did not have any other known disease. Following the surgical intervention, the patient self-administered VKA, but since becoming pregnant (5 weeks), the warfarin dosage had been discontinued for the first trimester and enoxaparin sodium (60 mg; 6000 anti-Xa IU-60

Received: November 03, 2017 Accepted: February 07, 2018

Correspondence: Dr. Ahmet Güner. Kartal Koşuyolu Yüksek İhtisas Eğitim ve Araştırma Hastanesi, Kardiyoloji Kliniği, Kartal, İstanbul, Turkey.

Tel: +90 216 - 500 15 00 e-mail: ahmetguner488@gmail.com

© 2019 Turkish Society of Cardiology



mg/0.6 mL) twice daily for the first trimester was prescribed by her gynecologist. Before the pregnancy, transthoracic echocardiography (TTE) imaging had indicated a normal transaortic pressure gradient of 62 mm Hg (peak)/34 mm Hg (mean). The level of anti-factor Xa remained in the range of 0.8 to 0.96 IU/mL over the course of LMWH administration (Table 1). TTE revealed normal left and right ventricular dimensions and function with intravalvular aortic regurgitation (Video 1). The pressure gradient across the aortic prosthesis was 135 mm Hg (peak)/87 mm Hg (mean) (Fig. 1a). After transesophageal echocardiography (TEE) disclosed an obstructive prosthetic valve thrombosis (PVT) with a mobile portion of 8 mm and a total area of 0.83 cm² (Fig. 1b and Video 2), an ultra-slow infusion (25 hours) of low-dose (25 mg)

tissue plasminogen activator (t-PA) was administered. Repeat TTE and TEE revealed that the thrombus had been eliminated and there was a normalization of the transaortic gradient (65 mm Hg (peak)/38 mm Hg (mean) (Fig. 1c, d and Video 3, 4). The patient underwent anticoagulation with VKA with a target international normalized ratio (INR) of between 2.5 and 4 for the rest of the pregnancy. At the 37th week of pregnancy, the use of warfarin was again eliminated and replaced with UFH until the day of a planned caesarean section. The patient gave birth to a healthy infant and both the mother and the baby continued to do well at monthly follow-ups.

Case 2 – A 27-year-old female in the first trimester of her pregnancy (6 weeks) visited the clinic for a regular

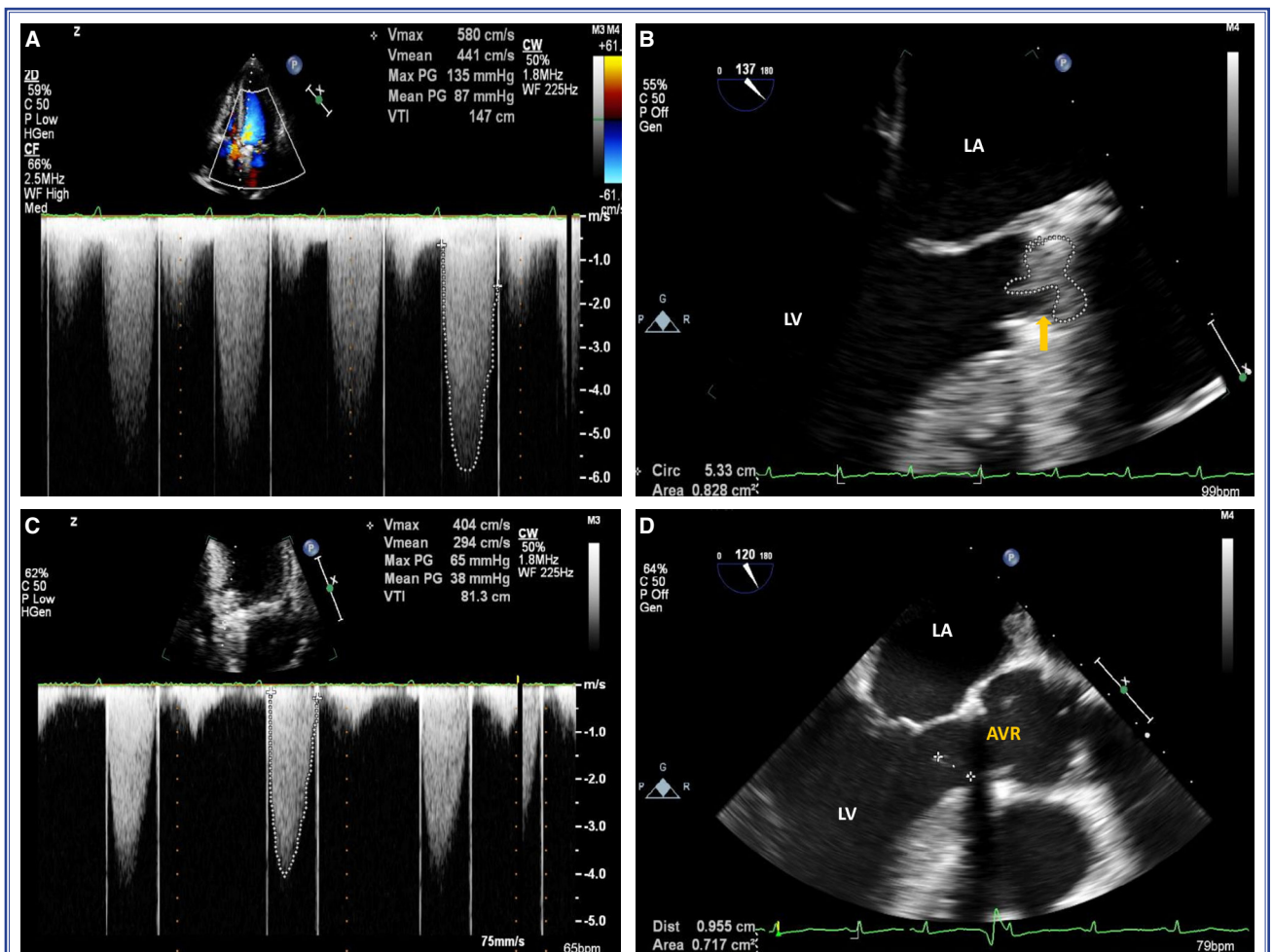


Figure 1. (A) A transthoracic echocardiography image in the apical 5-chamber view demonstrates that the pressure gradient across the aortic valve reached 135 mm Hg (peak)/87 mm Hg (mean). (B) A 2-dimensional transesophageal echocardiography (TEE) image shows an obstructive aortic prosthetic valve thrombus with a total area of 0.83 cm². (C) A TTE image in the apical 5-chamber view illustrates a pressure gradient across the aortic valve of 65 mm Hg (peak)/38 mm Hg (mean). (D) Two-dimensional TEE imaging reveals a small residual nonobstructive aortic prosthetic valve thrombus with a mobile portion of 9 mm.

Table 1. Anti-factor Xa levels in pregnancy

Case no	Anti-factor Xa levels according to pregnancy week (IU/mL)									
	4 th week	5 th week	6 th week	7 th week	8 th week	9 th week	10 th week	11 th week	12 th week	
1	–	0.92	0.85	0.92	0.93	–	0.86	0.94	0.96	
2	0.84	0.88	0.80	0.90	–	0.96	0.94	–	0.97	
3	0.81	0.80	0.85	0.89	0.90	0.93	0.92	0.91	–	

check-up. The patient's medical history revealed mitral valve replacement (No.27; St. Jude Medical Inc., Minneapolis, MN, USA) for rheumatic heart disease 5 years earlier. Following surgery, the patient continued regular warfarin use with an INR of between 2.5 and 3.5. Immediately after recognition of the pregnancy, warfarin was discontinued for the first trimester and

enoxaparin sodium (60 mg; enoxaparin 6000 anti-Xa IU-60 mg/0.6 mL) twice daily was prescribed by her primary care physician. TTE and TEE were performed at the sixth week of pregnancy (as per the routine follow-up protocol at the institution for pregnant women with prosthetic valves, baseline TTE and TEE were performed and repeated after the completion of

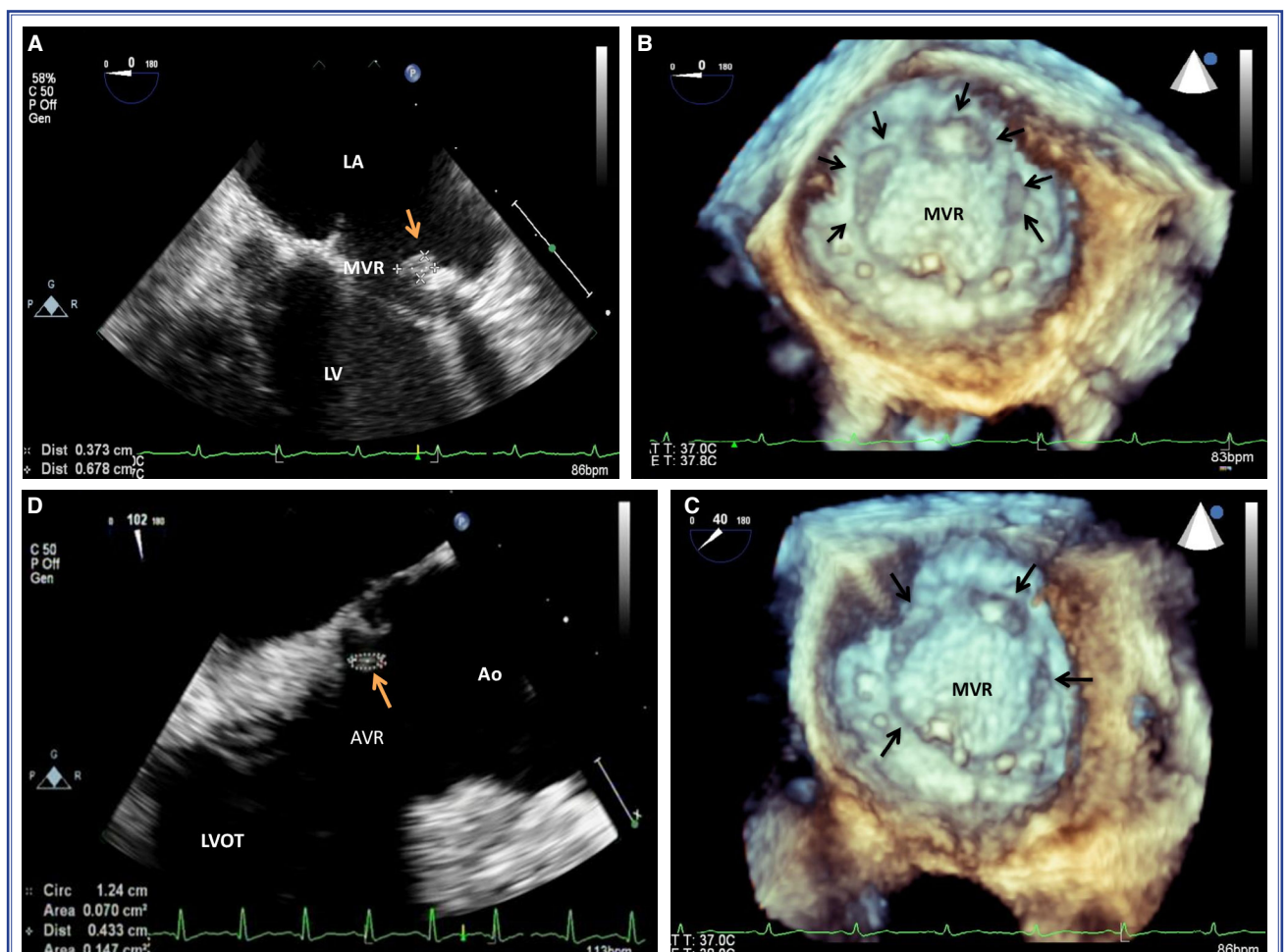


Figure 2. (A) Two-dimensional transesophageal echocardiography (TEE) imaging shows a nonobstructive aortic prosthetic valve thrombus with a total area of 0.25 cm². (B) Real-time 3-dimensional TEE shows a nonobstructive mitral prosthetic valve thrombus with a total area of 0.67 cm² (0.25 cm²+0.30 cm²+0.12 cm²). (C) Three-dimensional TEE image demonstrating a nonobstructive mitral prosthetic valve thrombus. (D) Two-dimensional TEE image of a nonobstructive aortic prosthetic valve thrombus with a total area of 0.07 cm².

every trimester to assess asymptomatic PVT). TEE indicated a normally functioning mitral prosthesis (max/mean gradient: 11/6 mm Hg). Over the course of the first trimester, the anti-factor Xa level remained in the range of 0.8 to 0.97 IU/mL (Table 1). The patient presented at the clinic as a result of experiencing palpitations at 9 weeks of gestation. Since oscillation of a fibrous mass on the mitral prosthetic valve was seen using TTE, TEE was also performed. Although the transmitral gradient was normal, a nonobstructive PVT with a mobile portion of 2 mm and a total area of 0.67 cm² (0.25 cm²+0.30 cm²+0.12 cm²) (Fig. 2a-c and video 5, 6) was noted. Due to the large thrombus border (0.67 cm²), an ultra-slow infusion of t-PA (25 hours) was provided at a low dose (25 mg). After the thrombolytic therapy, TEE was performed once more, and a detailed evaluation of the mitral mechanical valve showed near-complete lysis of the thrombus. At the 37th week of pregnancy, warfarin was replaced with UFH. At 39th week, the patient delivered a healthy baby via planned cesarean section.

Case 3 – A 26-year-old woman who was 8 weeks pregnant with a history of an ischemic cerebrovascular event 1 week prior was referred to the clinic for further examination. She had undergone AVR (No. 23; St. Jude Medical Inc., St. Paul, MN, USA) for rheumatic aortic regurgitation 8 years earlier. Immediately after detection of beta-human chorionic gonadotropin in the blood, warfarin use was discontinued and enoxaparin sodium (60 mg; 6000 anti-Xa IU-60 mg/0.6 mL) twice daily was prescribed by her gynecologist for the first trimester. She had anti-factor Xa levels of between 0.80 and 0.93 IU/mL (Table 1). A bedside TTE demonstrated normal transaortic gradients of 38 mm Hg (peak)/27 mm Hg (mean). TEE was performed and a nonobstructive PVT on the aortic side with mobile sections of 7 mm and 11 mm in diameter and a total area of 0.45 cm² was noted. Intensive anticoagulation therapy with UFH was initiated with a target activated partial thromboplastin time of between 50 and 70 seconds with weekly TEE reassessment. After 2 weeks, the TEE showed a significant decrease in thrombus burden with a residual small thrombus of 0.07 cm² (Fig. 2d). At the fourth week of UFH treatment, no residual thrombus was observed. Warfarin use was reinstated (10 mg/day) once the patient reached the 12th week of pregnancy, with a target INR of 2.5 to 4. At the 37th week of gestation, the warfarin was replaced with UFH until the

day of a planned caesarean section. After a successful delivery, warfarin therapy was re-initiated. Both the patient and the baby remained well during more than 2 years of follow-up.

DISCUSSION

We report 3 cases of PVT occurring despite treatment with LMWH and regular anti-factor Xa follow-up. One of these patients had an obstructive PVT, while 2 were cases of a relatively large, nonobstructive PVT. Two were treated with low-dose ultra-slow thrombolytic therapy, a novel treatment method according to recent studies in the literature.^[2,3] The patient in case 3 developed nonobstructive PVT, which was treated with UFH therapy. In such cases, administration of anticoagulants other than a VKA, such as UFH and LMWH, has long been recommended due to concerns about fetotoxicity. Of note, all 3 of these patients were followed with optimal monitoring for anti-factor Xa during pregnancy. Current evidence indicates that the administration of a VKA throughout pregnancy is the most favorable approach, with a PVT risk as low as 3.9%. However, a VKA crosses the placental barrier, and at high doses (i.e., >5 mg) can cause embryopathy when used in the first trimester, as well as other adverse fetal outcomes beyond the first trimester.^[1,4] But this risk has been reported to be as low as 0% to 2.6% at low doses. Therefore, it is reasonable to continue VKA treatment throughout a pregnancy if the required dose before pregnancy is low, as per up-to-date guideline recommendations. The most recent meta-analysis examining maternal and fetal outcomes of anticoagulated pregnant women with a MHV included 800 pregnancies and 18 publications, and a warfarin dose of <5 mg did not significantly impact fetal risk.^[1,5] On the other hand, although UFH during the first trimester is safe for the fetus, it is associated with an unacceptable PVT risk. The highest risk strategy in terms of PVT should be noted, which is as much as 33% when pregnant patients are continuously administered with adjusted-dose or low-dose UFH.^[6] LMWHs may display more potent anticoagulation in comparison with UFH since they inhibit both factor II and Xa. LMWHs are more bioavailable when administered subcutaneously. Moreover, although LMWHs are also safe in terms of fetal outcomes, the risk of PVT without anti-factor Xa monitoring is still high.^[7,8] Current guidelines^[9] and most recent expert opinions^[10-12] recommend the

use of LMWH with a target peak anti-factor Xa of between 0.8 and 1.2 IU/mL as the most favorable approach in terms of risk-benefit ratio. For LMWH administration over the course of a pregnancy, the risk of valve thrombus is about 7.1% to 12.3%, according to research with sample groups and including examination of anti-factor Xa levels.^[13,14] However, there is ongoing debate about whether peak or trough levels should be used. A recent study by Goland et al.^[15] demonstrated that routine measurement of the trough anti-factor Xa level may be necessary in women with MHVs treated with LMWH during pregnancy to assure an adequate level of anticoagulation. Although recent reports and guidelines recommend LMWH in terms of fetal safety, this case series demonstrates that LMWH with adequate peak anti-factor Xa follow-up is not devoid of PVT risk. Furthermore, the predictors of PVT risk despite anticoagulation with LMWH are unclear. The so-called risk factors are a history of previous valve thrombosis/embolism, atrial fibrillation, spontaneous echo contrast, left atrial enlargement, and left ventricular dysfunction. For instance, in a pregnant woman with an initial TEE assessment of nonobstructive PVT, complete discontinuation of VKA may be quite unsafe and may predispose the mother to severe adverse events, including valve obstruction and/or cerebral embolism. Even in a patient who is initially thrombus-free but has a history of previous thromboembolism, it can be argued that discontinuation of VKA and switching the therapy to LMWH does not inspire confidence. Based on this series, considering the development of new PVT in patients without any initial evidence of thrombus, LMWH seems to have the risk of potentially adverse maternal outcomes. Given these rationales, we believe that safer treatment methods other than LMWH with anti-factor Xa follow-up should be developed for pregnant women with a MHV. For such patients, a low dose of VKA can be used in combination with LMWH as a treatment option in order to provide a slight increase in INR and adequate anti-coagulation. The efficacy and safety of such a strategy compared with standard LMWH should be confirmed with findings from large series.

Conclusion

In conclusion, despite the use of LMWH with frequent monitoring of anti-factor Xa activity during the first trimester or throughout pregnancy, the PVT risk is not completely avoidable and more potent antico-

agulation regimens without detrimental effects to the fetus should be developed.

Peer-review: Externally peer-reviewed.

Conflict-of-interest: None.

Informed Consent: Written informed consent was obtained from the patient for the publication of the case report and the accompanying images.

Authorship contributions: Concept: A.G., S.G.; Design: A.G.; Supervision: M.Ö.; Materials: A.G., M.Ö.; Data collection: S.K., E.B.; Literature search: A.G.; Writing: A.G., S.G.

REFERENCES

- Steinberg ZL, Dominguez-Islas CP, Otto CM, Stout KK, Krieger EV. Maternal and Fetal Outcomes of Anticoagulation in Pregnant Women With Mechanical Heart Valves. *J Am Coll Cardiol* 2017;69:2681–91. [\[CrossRef\]](#)
- Özkan M, Çakal B, Karakoyun S, Gürsoy OM, Çevik C, Kalçık M, et al. Thrombolytic therapy for the treatment of prosthetic heart valve thrombosis in pregnancy with low dose, slow infusion of tissue-type plasminogen activator. *Circulation* 2013;128:532–40. [\[CrossRef\]](#)
- Özkan M, Gündüz S, Gürsoy OM, Karakoyun S, Astarcioglu MA, Kalçık M, et al. Ultraslow thrombolytic therapy: A novel strategy in the management of PROstheticMEchanical valve Thrombosis and the prEdictors of outcome: Ultraslow PROMETEE trial. *Am Heart J* 2015;170:409–18. [\[CrossRef\]](#)
- Hüttel E, Padberg S, Meister R, Beck E, Schaefer C. Pregnancy outcome of first trimester exposure to the vitamin K antagonist phenprocoumon depends on duration of treatment. *Thromb Haemost* 2017;117:870–9. [\[CrossRef\]](#)
- Fogerty AE. Challenges of Anticoagulation Therapy in Pregnancy. *Curr Treat Options Cardiovasc Med* 2017;19:76. [\[CrossRef\]](#)
- Chan WS, Anand S, Ginsberg JS. Anticoagulation of pregnant women with mechanical heart valves: a systematic review of the literature. *Arch Intern Med* 2000;160:191–6. [\[CrossRef\]](#)
- Vause S, Clarke B, Tower CL, Hay C, Knight M; (on behalf of UKOSS). Pregnancy outcomes in women with mechanical prosthetic heart valves: a prospective descriptive population based study using the United Kingdom Obstetric Surveillance System(UKOSS) data collection system. *BJOG* 2017;124:1411–9. [\[CrossRef\]](#)
- Şenol U, Ulus T, Birdane A, Çavuşoğlu Y. The use of low molecular weight heparin during pregnancy in patients with mechanical heart valves carries potential risk for valve thrombosis: a report of three cases. *Turk Kardiyol Dern Ars* 2014;42:294–8. [\[CrossRef\]](#)
- Nishimura RA, Otto CM, Bonow RO, Carabello BA, Erwin JP 3rd, Guyton RA, et al; American College of Cardiology/American Heart Association Task Force on Practice Guide-

- lines. 2014 AHA/ACC guideline for the management of patients with valvular heart disease: executive summary: a report of the American College of Cardiology/American Heart Association Task Force on Practice Guidelines. *J Am Coll Cardiol* 2014;63:2438–88. [CrossRef]
10. Berresheim M, Wilkie J, Nerenberg KA, Ibrahim Q, Bungard TJ. A case series of LMWH use in pregnancy: should trough anti-Xa levels guide dosing? *Thromb Res* 2014;134:1234–40. [CrossRef]
 11. Saeed CR, Frank JB, Pravin M, Aziz RH, Serasheini M, Dominique TG. A prospective trial showing the safety of adjusted dose enoxaparin for thromboprophylaxis of pregnant women with mechanical prosthetic heart valves. *Clin Appl Thromb Hemost* 2011;17:313–9. [CrossRef]
 12. Elkayam U. Anticoagulation Therapy for Pregnant Women With Mechanical Prosthetic Heart Valves: How to Improve Safety? *J Am Coll Cardiol*. 2017;69:2692–5. [CrossRef]
 13. Oran B, Lee-Parritz A, Ansell J. Low molecular weight heparin for the prophylaxis of thromboembolism in women with prosthetic mechanical heart valves during pregnancy. *Thromb Haemost* 2004;92:747–51. [CrossRef]
 14. McLintock C, McCowan LM, North RA. Maternal complications and pregnancy outcome in women with mechanical prosthetic heart valves treated with enoxaparin. *BJOG* 2009;116:1585–92. [CrossRef]
 15. Goland S, Schwartzberg S, Fan J, Kozak N, Khatri N, Elkayam U. Monitoring of anti-Xa in pregnant patients with mechanical prosthetic valves receiving low-molecular-weight heparin: peak or trough levels? *J Cardiovasc Pharmacol Ther* 2014;19:451–6. [CrossRef]
-
- Keywords:** Low molecular weight heparin; mechanical heart valve; prosthetic valve thrombosis.
- Anahtar sözcükler:** Düşük molekül ağırlıklı heparin; mekanik kalp kapağı; protez kapak trombozu.