

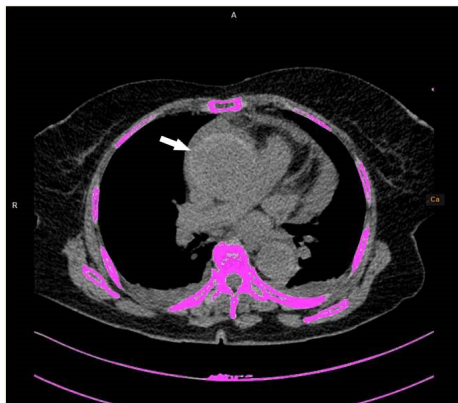
## A frequently overlooked cause of chest pain: Acute aortic intramural hematoma

### Göğüs ağrısının sıklıkla gözden kaçan bir nedeni: Akut aortik intramural hematom

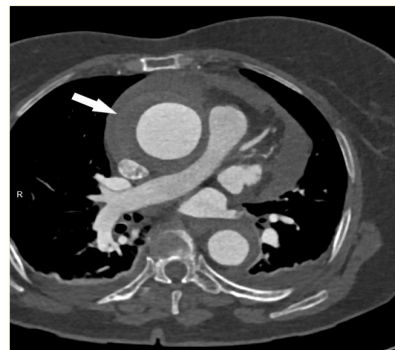
A 72-year-old female, with a history of hypertension and smoking, presented to our emergency department with severe chest pain radiating to the left shoulder and the back. Her electrocardiogram was normal and high-sensitive cardiac troponin T levels were observed at 21 pg/mL (Roche Diagnostics GmbH, Mannheim, Germany). An echocardiogram revealed a dilated ascending aorta, an asymmetric aortic wall thickening with a hypoechoic texture, an eccentric aortic lumen, and pericardial effusion (Video 1\*). For further investigation, a cardiac computed tomography was ordered, and it revealed an acute aortic intramural hematoma (IMH). Focal, crescentic, high-attenuating regions of the eccentrically thickened aortic wall (high-attenuation crescent sign) appeared on noncontrast computerized tomography (CT) (Figure 1). An enlarged aorta with thickened aortic wall, but without an intimal flap, was observed in contrast-enhanced CT images (Figure 2, Video 2\*). IMH extended from the root to the abdominal segment of the aorta and coronary arteries were observed to be normal. After the diagnosis of acute intramural hematoma, the patient underwent successful aortic surgery and was discharged a week later. This case demonstrates the importance of high level of suspicion and prompt evaluation, and noncontrast imaging, which is essential for the diagnosis of IMH.

Informed consent was obtained from the patient for the publication of the case image and the accompanying images.

\*Supplementary video files associated with this article can be found in the online version of the journal.



**Figure 1.** Unenhanced axial image showing a crescentic, hyperattenuating intramural fluid collection (arrow).



**Figure 2.** Contrast, material-enhanced axial image depicting a smooth, nonenhancing, crescentic region of aortic wall thickening (arrow) without an intimal flap.

### CASE IMAGE OLGU GÖRÜNTÜSÜ

**İbrahim Altun, M.D.<sup>1</sup>**   
**Özcan Başaran, M.D.<sup>1</sup>**   
**Oğuzhan Çelik, M.D.<sup>1</sup>**   
**İlknur Altun, M.D.<sup>2</sup>**   
**Neşat Çullu, M.D.<sup>2</sup>**

<sup>1</sup>Department of Cardiology, Muğla Sıtkı Koçman University School of Medicine, Muğla, Turkey

<sup>2</sup>Department of Radiology, Muğla Sıtkı Koçman University School of Medicine, Muğla, Turkey

#### Corresponding Author:

İbrahim Altun  
✉ ibrahim\_altun@yahoo.com

**Received:** January 23, 2021

**Accepted:** February 1, 2021

**Cite this article as:** Altun İ, Başaran Ö, Çelik O, Altun İ, Çullu N. A frequently overlooked cause of chest pain: Acute aortic intramural hematoma. *Türk Kardiyol Dern Ars* 2022;50:85.

DOI: 10.5543/tkda.2022.81317



Content of this journal is licensed under a Creative Commons Attribution – NonCommercial–NoDerivatives 4.0 International License.