

CASE REPORT

## Tricuspid valve chordal rupture after a motorbike accident

### Motorsiklet kazası sonrası triküspit kapağında korda rüptürü

Oğuz Karaca, M.D., Günhan Demir, M.D., Arda Özyüksel, M.D.,# Atıf Akçevin, M.D.#

Department of Cardiology, Medipol University Faculty of Medicine, İstanbul, Turkey

#Department of Cardiovascular Surgery, Medipol University Faculty of Medicine, İstanbul, Turkey

**Summary**– Cardiac valve injury, a condition that can follow blunt thoracic trauma, has a wide range of clinical presentations, depending on the structures involved. Post-traumatic tricuspid regurgitation is relatively rare, caused by increase in intrathoracic pressure when the tricuspid valve leaflets close, leading to rupture of the chordae tendineae. A case of severe tricuspid regurgitation due to chordal rupture presenting with atrial flutter following a motorbike accident is described in the present report.

A wide range of clinical presentations, depending on the structures involved, should lead clinicians to suspect cardiac valve injury, which may occur secondary to blunt thoracic trauma. Post-traumatic tricuspid regurgitation is relatively rare, and occurs when the chordae tendineae are ruptured as a result of increased intrathoracic pressure caused by closure of the tricuspid valve leaflets.<sup>[1,2]</sup>

Presently described is a case of severe tricuspid regurgitation caused by chordae rupture and presenting with atrial flutter, the result of a motorbike accident.

#### CASE REPORT

A previously healthy 19-year-old presented with palpitations and fatigue in orthopedics clinic. He had been in a motorbike accident a week earlier that had caused a displaced left clavicle fracture, treated with open reduction and plate screw. Chest x-ray showed enlarged right heart chambers, and electrocardiogram showed typical atrial flutter (Figure 1a). Transthoracic echocardiography revealed an enlarged right atrium and right ventricle with severe tricuspid regurgitation caused by chordal rupture of the anterior leaf-

**Özet**– Künt toraks travmaları sonrası gelişen kalp travması olguları, etkilenen yapılara bağlı olarak çeşitli klinik sunumlar göstermektedir. Travma sonrası triküspit yetersizliği literatürde nadirdir, triküspit kapak yapraklarının kapalı olduğu sırada travmaya sekonder toraks içi basıncı artışı sonucu triküspit kapak kordalarının rüptürüne bağlı olarak geliştiği düşünülmektedir. Bu yazıda, motorsiklet kazası sonrası atriyum flutteri ve ileri triküspit yetersizliği ile karşımıza çıkan hastanın triküspit kapaktaki korda rüptürü olgusu tartışıldı.

let, requiring surgery (Figure 1b, c; Video 1\*). Atrial flutter persisted after antiarrhythmic therapy, requiring electrical cardioversion to achieve normal sinus rhythm. Surgery involved primary repair of the tricuspid anterior leaflet by neochordae implantation and annuloplasty with a 34-mm rigid ring (Figure 2a, b). Tricuspid valve leaflets had adequate coaptation with acceptable mild regurgitation following surgery, demonstrated by transthoracic echocardiography (Figure 3a, b; Video 2\*) and cardiac magnetic resonance imaging (Figure 3c; Video 3\*). During follow-up the patient was free of symptoms or arrhythmic episodes and was discharged uneventfully.

#### DISCUSSION

Although post-traumatic tricuspid valve chordal rupture is extremely rare, physicians working in emergency departments should be aware of the possibility of patients presenting with it following non-penetrating chest trauma. Tricuspid regurgitation caused by rupture of the chordae tendineae has been shown to be associated with anterior chest wall blunt trauma.<sup>[1,2]</sup> While some cases are reported to have been as-

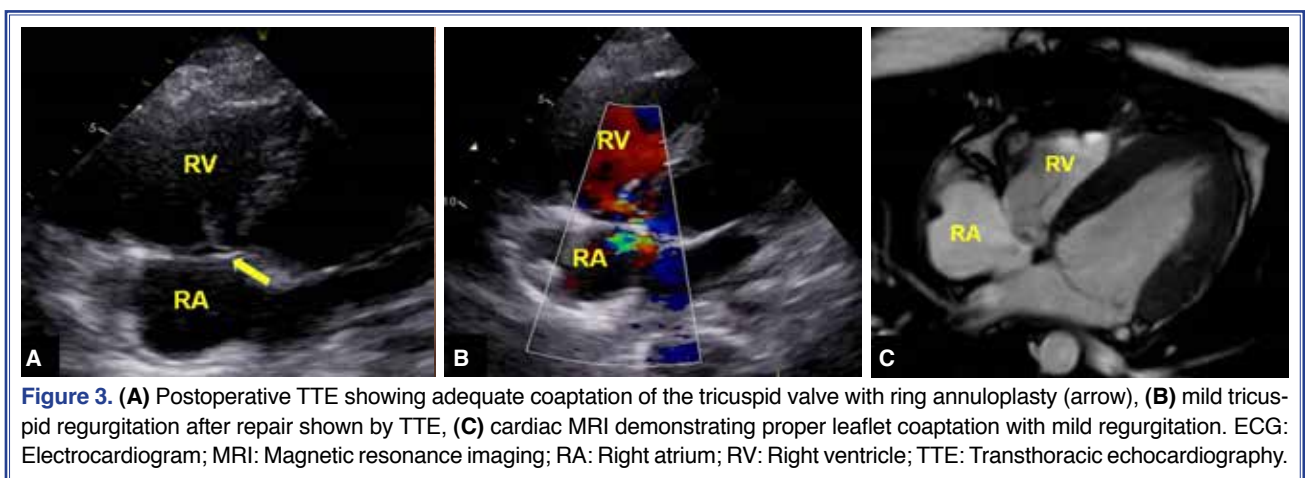
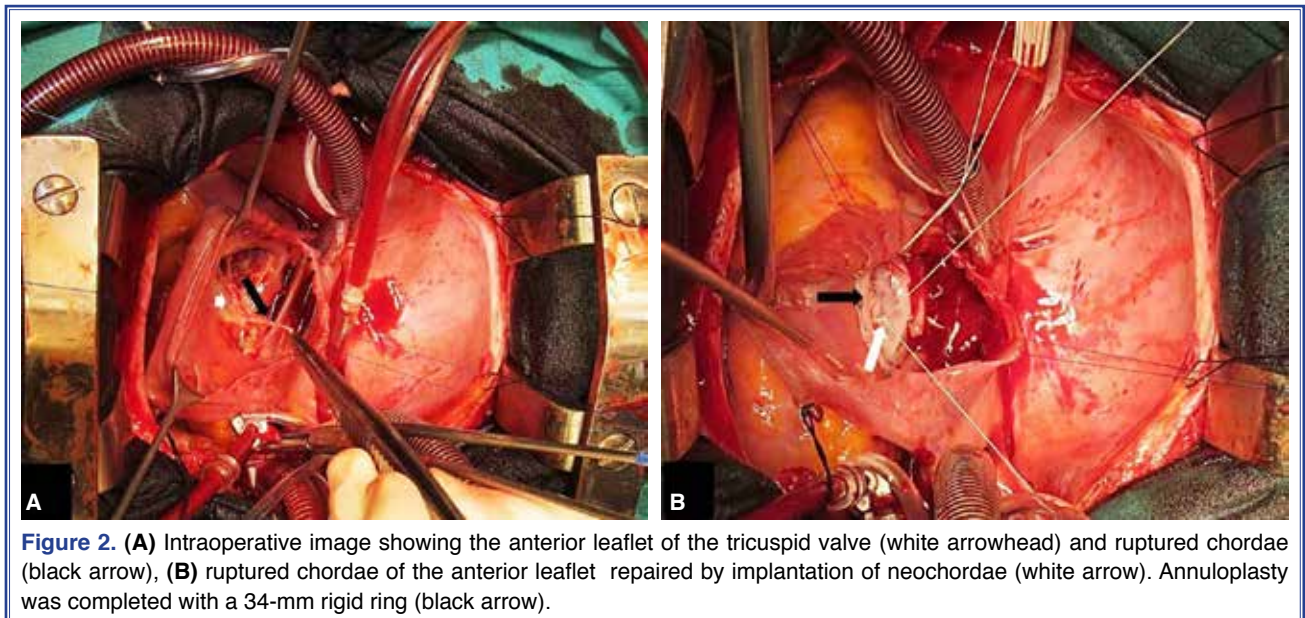
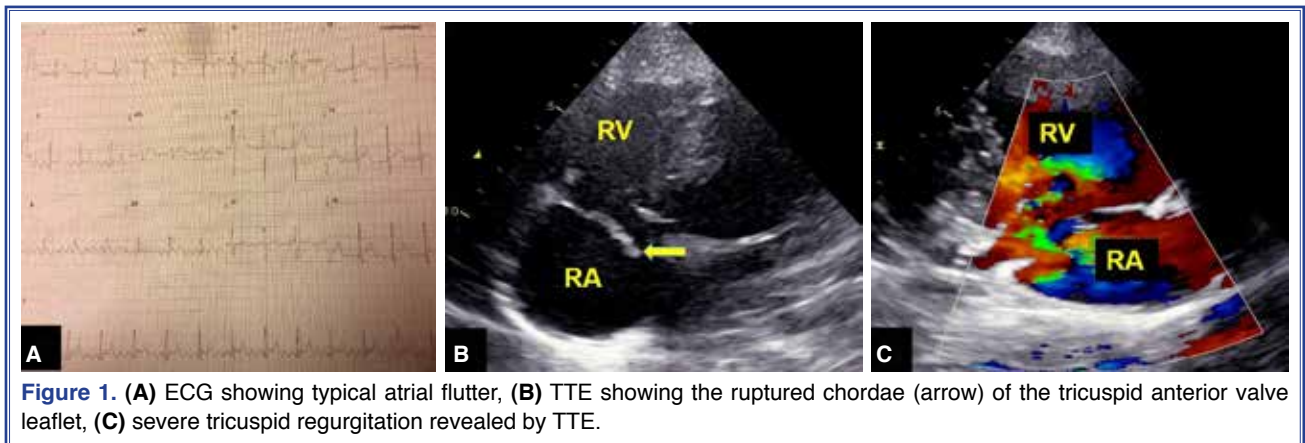
Received: July 26, 2015 Accepted: October 07, 2015

Correspondence: Dr. Oğuz Karaca. Medipol Mega Hastaneler Kompleksi, Tem Otoyolu Göztepe Çıkışı, No: 1, İstanbul, Turkey.

Tel: +90 216 - 459 40 41 e-mail: oguzkaraca@hotmail.com

© 2016 Turkish Society of Cardiology





ymptomatic and diagnosed incidentally,<sup>[3]</sup> injury to the cardiac conduction system may result in arrhythmic disturbances.<sup>[4]</sup> To our knowledge, the present

report is the first to describe trauma-induced atrial flutter in a patient with tricuspid valve chordal rupture.

Early assessment with echocardiography leads to accurate diagnosis. Clinical decision to use echocardiography in a case of trauma must depend on pathological findings of examination and chest x-ray. The present case calls attention to a rare clinical condition of cardiac arrhythmia and valvular insufficiency following blunt trauma to the anterior chest wall treated with electrical cardioversion and successful surgical repair.

**Conflict-of-interest issues regarding the authorship or article: None declared.**

**\*Supplementary video files associated with this article can be found in the online version of the journal.**

## REFERENCES

1. Abbasi K, Ahmadi H, Zoroufian A, Sahebjam M, Moshtaghi

N, Abbasi SH. Post-traumatic chordae rupture of tricuspid valve. Post-traumatic chordae rupture of tricuspid valve. J Tehran Heart Cent 2012;7:185–7.

2. dos Santos J Jr, de Marchi CH, Bestetti RB, Corbucci HA, Pavarino PR. Ruptured chordae tendineae of the posterior leaflet of the tricuspid valve as a cause of tricuspid regurgitation following blunt chest trauma. Cardiovasc Pathol 2001;10:97–8.
3. Furukawa N, Hakim-Meibodi K, Gummert J. Isolated latent tricuspid regurgitation caused by blunt trauma. Thorac Cardiovasc Surg 2011;59:497–9. [Crossref](#)
4. Hasdemir H, Arslan Y, Alper A, Osmonov D, Güvenç TS, Poyraz E, et al. Severe tricuspid regurgitation and atrioventricular block caused by blunt thoracic trauma in an elderly woman. J Emerg Med 2012;43:445–7. [Crossref](#)

**Keywords:** Blunt trauma; tricuspid valve; valve repair; wounds and injuries.

**Anahtar sözcükler:** Künt travma; triküspit kapak; kapak tamiri; yaralar ve yaralanmalar.