

CASE REPORT

Atrial flutter and nonconducted bigeminy premature atrial contraction in a neonate with cardiac rhabdomyoma

Kalp rabdomiyomu olan bir yenidoğanda atriyum flatteri ve iletilmeyen bigemine erken atriyal atım

Yakup Ergül, M.D., Erkut Öztürk, M.D., Alper Güzeltaş, M.D.

Department of Pediatric Cardiology, Health Sciences University İstanbul Mehmet Akif Ersoy Thoracic and Cardiovascular Surgery Training and Research Hospital, İstanbul, Turkey

Summary– During the neonatal period the majority of cardiac tumors seen are rhabdomyomas, and the clinical manifestations are notably variable. Symptoms of rhabdomyoma depend on the presence of intracardiac obstructions, myocardial involvement, or rhythm disturbances. Most cardiac rhabdomyomas regress in follow-up, but some need medical/surgical intervention during the neonatal period as a result of resistant atrial or ventricular arrhythmia. The present case study is a description of an 8-day-old neonate with atrial bigeminy that caused nonconducted premature pulse-related bradycardia, and cardiac rhabdomyoma-related resistant atrial flutter that were detected and successfully treated.

In both neonates and infants, rhabdomyomas represent the majority of cardiac tumors that occur, and they are closely associated with tuberous sclerosis. Notably, clinical manifestations of cardiac rhabdomyomas in neonates vary greatly. Symptoms of rhabdomyomas are attributed to the presence of intracardiac obstruction, myocardial involvement, or rhythm disturbances.^[1-3] Although a significant regression is usually observed during follow-up, some of these tumors may need urgent medical/surgical treatment in the neonatal period due to a resistant atrial or ventricular arrhythmia.^[3,4] The most commonly observed arrhythmias are manifested pre-excitation or concealed in an accessory pathway-related supraventricular tachycardia, ectopic atrial tachycardia, premature atrial-ventricular beats, or ventricular tachycardia.^[1-4] A rapid, transient atrial flutter^[5] (which needs urgent treatment) and blocked bigeminy, leading to early

Özet– Yenidoğan döneminde rabdomiyomlar kalp tümörlerinin çoğunluğunu oluşturur ve klinik bulguları değişkenlik gösterir. Rabdomiyom semptomları kalp içi tıkanıklıklar, miyokart tutulumu ve ritim bozukluklarına bağlıdır. Kalp rabdomiyomlarının çoğu takipte geriler. Ancak yenidoğan döneminde dirençli atriyum veya ventrikül aritmileri nedeniyle bazılarının tıbbi veya cerrahi müdahaleye ihtiyacı olmaktadır. Bu yazıda iletilmeyen atriyal erken atımlar ile ilgili bradikardi ve kalp rabdomiyomu ile ilişkili dirençli atriyum flatteri saptanan ve başarıyla tedavi edilen sekiz günlük bir yenidoğan olgusu sunuldu.

atrial arrhythmia-related bradycardia, was reported in a series of 7 consecutive cases of perinatal cardiac rhabdomyoma that needed emergency diagnosis and treatment.^[4]

In the present case report, an 8-day-old neonate was presented; 2:1 nonconducted premature atrial beat-related bradycardia and cardiac rhabdomyoma-related resistant atrial flutter were detected and successfully treated. The present study is a novel case in which rhabdomyoma and these 2 arrhythmias were seen together.

Abbreviations:

AV	Atrioventricular
ECG	Electrocardiography
PAC	Premature atrial contraction

CASE REPORT

A neonate was admitted to the emergency department of another hospital with cyanosis and decreased suck-

Received: June 02, 2017 Accepted: September 21, 2017

Correspondence: Dr. Erkut Öztürk. İstanbul Mehmet Akif Ersoy Göğüs ve Kalp Damar Cerrahisi Eğitim ve Araştırma Hastanesi, Çocuk Kardiyoloji Kliniği, İstanbul, Turkey.

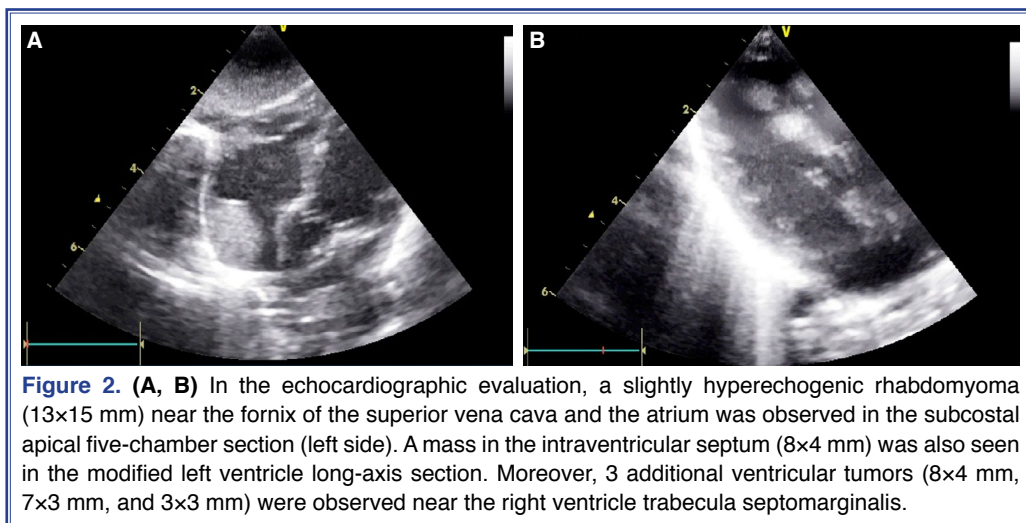
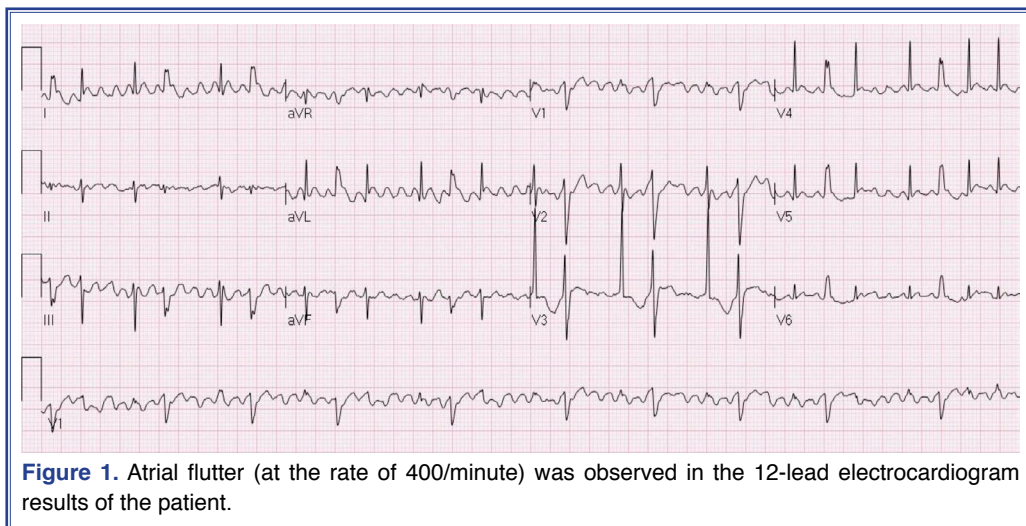
Tel: +90 212 - 616 54 14 e-mail: erkut_ozturk@yahoo.com

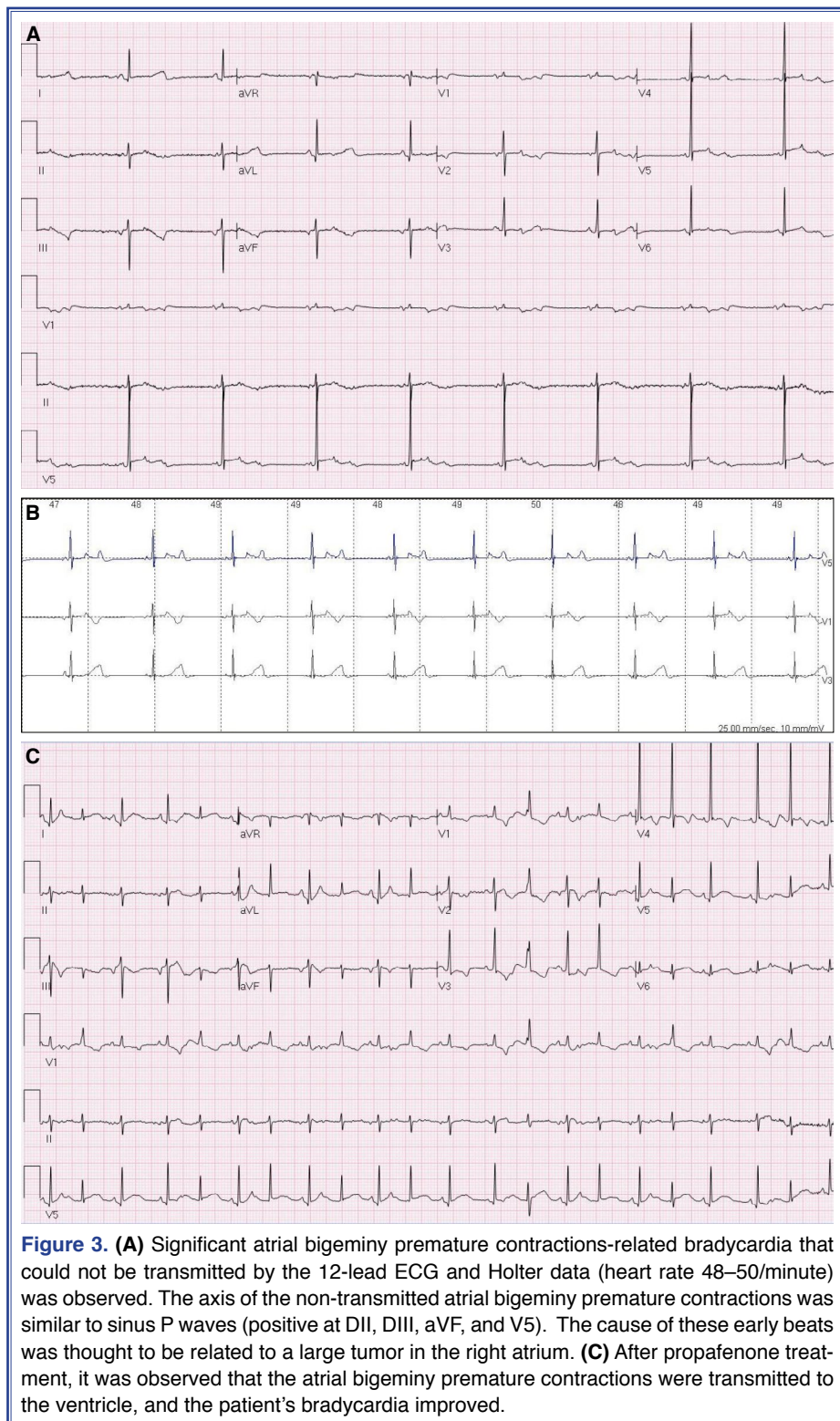
© 2018 Turkish Society of Cardiology



ing reflex. The mother had no antenatal care and the child's birth weight was 3,100 g. Upon physical examination, tachypnea, dyspnea, tachycardia, a 2/6 systolic murmur at apex, and a 3-cm hepatomegaly were detected. Electrocardiography (ECG) revealed a narrow QRS tachycardia of 200/minute and an irregular RR interval. After initial treatments were ineffective, intravenous adenosine propranolol and amiodarone therapy were initiated. Since the tachycardia did not show any regression after 72 hours of treatment, the patient was referred to our intensive care unit. At admission, his ECG was compatible with atrial flutter (atrial rate 400–430/min) with a 2:1 ventricular conduction (Fig. 1). Echocardiography demonstrated a slightly hyperechogenic mass that was compliant with rhabdomyoma, measuring 13×15 mm and localized at the junction of the superior vena cava and the

right atrium in subcostal 5-chamber view. Additional masses localized at the interventricular septum (8×4 mm) and next to the moderator band (8×4 mm, 7×3 mm, and 3×3 mm) were also detected (Fig. 2). The tumors did not cause any obstruction in either the inflow or the outflow, and left ventricle contraction was preserved (shortening fraction: 36%). No thrombus was observed in echocardiography. Low-molecular-weight heparin treatment was started, and an intravenous amiodarone infusion was administered at a dose of 10 $\mu\text{g}/\text{kg}/\text{minute}$. Despite these medical treatments, the atrial flutter continued; therefore, synchronized cardioversion was performed. Frequent premature atrial contractions (PACs) with aberrant conduction were detected after cardioversion. The treatment was continued with 3 mg/kg/day of oral amiodarone. On the fifth day of treatment, significant bradycardia devel-





oped (48–50/minute), and concomitantly, the sucking reflex decreased. There was no pathological finding in the complete blood count, biochemical analysis, arterial blood gas analysis, or levels of C-reactive protein,

procalcitonin, and thyroid hormones. ECG revealed nonconducted bigeminy PACs (Fig. 3). Since the axis of the nonconducted early atrial bigeminy beats was similar to sinus P waves, the cause of the early beats

was thought to be related to a tumor mass in the right atrium-superior vena cava junction. Administration of oral propafenone (150 mg/m²/day, in 2 doses) was started. Three days after the initiation of propafenone, the PACs began to conduct to the ventricle. Moreover, the heart rate of the patient reached 120/minute (Fig. 3). The atrial flutter and bradycardia never repeated during the 3-month follow-up period. The patient continued to receive low-dose amiodarone and propafenone treatment.

DISCUSSION

In children, at least 60% to 65% of primary tumors in the heart are rhabdomyomas. Although rhabdomyomas may be asymptomatic, they can also cause arrhythmias, inflow-outflow obstructions, cardiac failure, and sudden cardiac death.^[1-3] Depending on the anatomical location, rhabdomyoma can induce various cardiac arrhythmias, including PACs, supraventricular tachycardia, multifocal premature ventricular contractions, second- or third-degree atrioventricular (AV) block, sinus nodal dysfunction, and pre-excitation (Wolff-Parkinson-White pattern) syndrome.^[1-3,6]

Almost 75% of rhabdomyomas are diagnosed in infants younger than 1 year of age and one-third of these cases are recognized during the neonatal stage. Most of these tumors are asymptomatic and they regress over the years without leading to any hemodynamic problem.^[1] Although very rare, resistant tumor-related tachycardia can be life-threatening during the neonatal period.^[1-4] Some cases of rhabdomyoma-related resistant tachyarrhythmia during the neonatal period have been reported.^[2,5,7] Notably, in 2011, De Rosa et al.^[4] published a remarkable summary of their experience with cardiac rhabdomyoma over 18 years. In this study, they reported the details of 18 fetal and postnatal rhabdomyoma cases, and stated that 7 of these cases involved life-threatening conditions in the neonatal period (5 because of arrhythmia and 2 because of blood flow obstruction). The life-threatening arrhythmias in this study were ectopic atrial tachycardia, ventricular tachycardia, and Wolff-Parkinson-White pattern-related supraventricular tachycardia with bradycardia due to blocked atrial bigeminy. The patients' tachyarrhythmia was controlled with drugs, including propranolol, sotalol, and amiodarone, and the tumor regressed spontaneously most of the time.

Macroreentrant atrial tachycardia is the atrial flut-

ter more commonly seen during the neonatal period and other stages of childhood, and it is not dependent on the AV node. If no accompanying structural heart disease is present, atrial flutter usually shows a stable progression and it can be treated with either tachycardia cardioversion or overdrive pacing.^[8] The co-occurrence of atrial flutter and rhabdomyoma has been reported in only 1 case (a neonate with a right ventricular rhabdomyoma), and was treated with a combination of digoxin and amiodarone.^[5] In the present case, the atrial flutter was amiodarone-resistant and was stopped with cardioversion.

Bradycardia (resting rate <100 bpm) in the neonatal stage can develop based on 3 different mechanisms: sinus bradycardia, complete heart block, or functional AV block (bigeminy nonconducted PAC and 2:1 AV block).^[4] A nonconducted PAC is characterized by a premature P wave deflection that is not followed by a QRS complex. Since the sinus node pacemaker is suppressed by the PACs, the sinus cycle resets, and this results in a relatively long pause, which may cause functional bradycardia, and sometimes misdiagnosis. This condition, which is usually accepted as benign in both the fetal and neonatal periods, can sometimes be the reason for significant bradycardia.^[4,8,9] In the neonatal period, the co-occurrence of bigeminy nonconducted PAC and rhabdomyoma has been reported in only 1 case, which was a patient with a ventricular mass.^[4] Propafenone was administered to the patient in the present case because a previous study had reported the successful use of class 1C antiarrhythmic propafenone in bigeminy nonconducted PAC cases leading to hemodynamic bradycardia. The atrial bigeminy premature contractions were transmitted to the ventricle, and the patient's bradycardia improved.

Conclusion

In neonates, rhabdomyoma with an atrial location can lead to problems both by causing atrial flutter with fast ventricle transmission and by leading to bigeminy nonconducted PAC-related functional bradycardia. Medical treatment and synchronized cardioversion are usually enough to treat this kind of arrhythmia.

Informed consent: Written informed consent was obtained from the patients family during for academical usage of the patients records.

Peer-review: Externally peer-reviewed.

Conflict-of-interest: None declared.

Authorship contributions: Data collection &/or processing – E.O., Y.E.; Supervision – Y.E., A.G.; Interpretation: E.O., Y.E., A.G.; Writing – EO, YE; Critical revisions – Y.E., A.G.

REFERENCES

1. Isaacs H Jr. Fetal and neonatal cardiac tumors. *Pediatr Cardiol* 2004;25:252–73. [\[CrossRef\]](#)
2. Miyake CY, Del Nido PJ, Alexander ME, Cecchin F, Berul CI, Triedman JK, et al. Cardiac tumors and associated arrhythmias in pediatric patients, with observations on surgical therapy for ventricular tachycardia. *J Am Coll Cardiol* 2011;58:1903–9. [\[CrossRef\]](#)
3. Mühler EG, Kienast W, Turniski-Harder V, von Bernuth G. Arrhythmias in infants and children with primary cardiac tumours. *Eur Heart J* 1994;15:915–21. [\[CrossRef\]](#)
4. De Rosa G, De Carolis MP, Pardeo M, Bersani I, Tempera A, De Nisco A, et al. Neonatal emergencies associated with cardiac rhabdomyomas: an 8-year experience. *Fetal Diagn Ther* 2011;29:169–77. [\[CrossRef\]](#)
5. Dilber E, Mutlu M, Dilber B, Aslan Y, Gedik Y, Celiker A. Intravenous amiodarone used alone or in combination with digoxin for life-threatening supraventricular tachyarrhythmia in neonates and small infants. *Pediatr Emerg Care* 2010;26:82–4. [\[CrossRef\]](#)
6. Shiono J, Horigome H, Yasui S, Miyamoto T, Takahashi-Igari M, Iwasaki N, et al. Electrocardiographic changes in patients with cardiac rhabdomyomas associated with tuberous sclerosis. *Cardiol Young* 2003;13:258–63.
7. Öztunç F, Atik SU, Güneş AO. Everolimus treatment of a newborn with rhabdomyoma causing severe arrhythmia. *Cardiol Young* 2015;25:1411–4. [\[CrossRef\]](#)
8. Jaeggi E, Öhman A. Fetal and Neonatal Arrhythmias. *Clin Perinatol* 2016;43:99–112. [\[CrossRef\]](#)
9. Akdeniz C, Tanidir IC, Tuzcu V. Blocked atrial bigeminy presenting with bradycardia. *Congenit Heart Dis* 2012;7:E82–4.

Keywords: Atrial flutter; bigeminy; cardiac rhabdomyoma; neonate; nonconducted; premature atrial contraction.

Anahtar sözcükler: Atriyum flutteri; bigemine; kalp rabdomyomu; yenidoğan; ileilmeyen; erken atriyal atım.