

Conduction Disturbances and Arrhythmia Risk After Septal Reduction Therapy with Alternative Agents: A Pilot Study with EVOH-DMSO and Systematic Review

Alternatif Ajanlarla Septal Redüksiyon Tedavisinden Sonra İletim Bozuklukları ve Aritmi Riski: EVOH-DMSO ile Pilot Çalışma ve Sistemik Derleme

ORIGINAL ARTICLE
KLİNİK ÇALIŞMA

ABSTRACT

Objective: Surgical septal myectomy and alcohol septal ablation are recommended treatment modalities for alleviating Left ventricular outflow tract (LVOT) gradient in obstructive HCM. Alcohol septal ablation offers advantages over surgery in many ways. However, it is associated with some life-threatening complications. For this purpose, our center used alternative agents for septal artery embolization. This study compared and evaluated conduction system defects and arrhythmia risk after EVOH-DMSO septal ablation with other alternative agents and alcohol septal ablation.

Methods: Twenty-five patients who received septal reduction therapy with EVOH-DMSO were analyzed retrospectively, and all non-alcoholic agent's septal ablation studies were systematically reviewed and compared.

Results: Twenty-five patients (52% female; mean age: 55.8 ± 17.1) with symptomatic obstructive HCM were enrolled. The Peak LVOT gradient was significantly reduced after the procedure (68 vs. 20 mmHg; $P < 0.001$). During the 12-month follow-up, no mortality occurred. The complete atrioventricular block was noted in 2 (8%) patients. The incidence of right bundle branch block (RBBB) increased after the procedure (pre-procedural 2 patients (8%), post-procedural 9 patients (36%) $P = 0.002$). On ECG and Holter monitorization, no sustained ventricular tachyarrhythmia occurred during follow-up, and no change was found in the frequency of atrial fibrillation. We systematically compared EVOH-DMSO to other non-alcohol agents, and we found that EVOH-DMSO can cause conduction system problems more commonly than other non-alcohol agents.

Conclusion: EVOH-DMSO could cause conduction system problems more common than other non-alcohol agents but less than alcohol septal ablation.

Keywords: Cardiac arrhythmias, alternative septal ablation agents, hypertrophic cardiomyopathy, septal reduction therapy

ÖZET

Amaç: Cerrahi septal miyektomi ve alkol septal ablasyonu, obstrüktif HKMP'de sol ventrikül çıkım yolu gradiyentini hafifletmek için önerilen tedavi yöntemleridir. Alkol septal ablasyonun cerrahiye göre birçok avantajı olmasına rağmen yaşamı tehdit eden bazı komplikasyonlarla da ilişkilidir. Bu nedenle merkezimiz septal arter embolizasyonu için alternatif ajanlar kullanmaktadır. Bu çalışmada, EVOH-DMSO ile septal ablasyon verilerimiz ışığında, tüm diğer alternatif ajan septal redüksiyon yöntemleri ve alkol septal ablasyonu sonrası iletim sistemi bozuklukları ve aritmi riski karşılaştırması amaçlanmıştır.

Yöntemler: EVOH-DMSO ile septal redüksiyon tedavisi alan 25 hasta retrospektif olarak, bunun yanında tüm alternatif ajan septal redüksiyon çalışmaları sistemik literatür taraması ile ince-

Serkan Asil, M.D.¹ 

Kudret Aytemir, M.D.² 

¹Department of Cardiology, Gülhane Training and Research Hospital, Ankara, Türkiye

²Department of Cardiology, Hacettepe University Hospital, Ankara, Türkiye

Corresponding Author:

Serkan Asil

✉ dr_serkanasil@hotmail.com

Received: September 09, 2022

Accepted: September 19, 2022

Cite this article as: Asil S, Aytemir K. Conduction disturbances and arrhythmia risk after septal reduction therapy with alternative agents: A pilot study with EVOH-DMSO and systematic review. *Türk Kardiyol Dern Ars* 2023;51:40-49.

DOI: 10.5543/tkda.2022.69570



Content of this journal is licensed under a Creative Commons Attribution – NonCommercial–NoDerivatives 4.0 International License.

lendi ve karşılaştırıldı.

Bulgular: Semptomatik obstrüktif HKMP'li 25 hasta (%52 kadın; ortalama yaş: 55,8±17,1) çalışmaya alındı. Pik sol ventrikül çıkım yolu gradiyenti prosedürden sonra önemli ölçüde azaldı (68'e karşı 20 mmHg; $P < 0,001$). 12 aylık takipte mortalite olmadı. 2 (%8) hastada tam atriyoventriküler blok kaydedildi. İşlem sonrası RBBB insidansı belirgin artmıştı (işlem öncesi 2 hasta (%8), işlem sonrası 9 hasta (%36) $p = 0,002$). Takipte EKG ve Holter monitörizasyonunda sürekli ventriküler taşiaritmi olmadı ve atriyal fibrilasyon sıklığında değişiklik yaşanmadı. EVOH-DMSO'yu diğer alternatif ajanlar ile sistematik literatür taraması yaparak karşılaştırdık ve EVOH-DMSO'nun diğer alternatif ajanlardan daha yaygın olarak iletim sistemi sorunlarına neden olabileceğini saptadık.

Sonuç: EVOH-DMSO, diğer alternatif ajanlardan daha yaygın, ancak alkol septal ablasyondan daha az iletim sistemi sorunlarına neden olabilmektedir.

Anahtar Kelimeler: Alternatif septal ablasyon ajanları, Hipertrofik kardiyomiyopati, kardiyak aritmiler, septal redüksiyon tedavisi

Hypertrophic cardiomyopathy (HCM) is the most common genetic heart disease seen in approximately 1:500 of the population.¹ The disease exhibits a heterogeneous clinical course, with varying clinical presentations such as sudden cardiac death, heart failure, and an asymptomatic course. Left ventricular outflow tract (LVOT) obstruction, diastolic dysfunction, mitral regurgitation (MR), myocardial ischemia, and arrhythmias are held responsible for symptoms in HCM.²

LVOT obstruction is defined as 30 mmHg or higher LVOT gradient either at resting or after provocation.^{3,4} LVOT obstruction delays ventricular relaxation by increasing left ventricular (LV) systolic pressure, increases LV diastolic pressure, myocardial ischemia, and MR, and causes symptoms by decreasing cardiac stroke volume.^{3,4} The cause of LVOT obstruction is generally explained by combining the systolic anterior motion of the anterior mitral leaflet (SAM-systolic

anterior motion) and the venturi effect in systole with the hypertrophied septum.³⁻⁵ In many studies, the LVOT gradient is the main factor in the formation of symptoms and is the primary determinant of prognosis.⁵

To control symptoms and improve survival, septal reduction therapy is recommended in patients with LVOT obstruction.^{3,4} Surgical septal myectomy is an invasive treatment approach preferred in experienced centers for appropriate patients.^{3,4} Septal ablation can be applied with similar efficacy and results as an alternative to surgical septal myectomy in percutaneous catheter-based procedures.⁶ For this purpose, alcohol septal ablation (ASA) is an invasive treatment approach that has been applied for about 25 years. Furthermore, it significantly improves symptoms with the enlargement of the outflow tract and a decrease in the gradient due to the occlusion of the septal perforator vessel.^{3,4,7} One of the biggest concerns about ASA is that the need for permanent pacemakers between 10% and 20%, due to advanced atrioventricular (AV) blocks being more common than myectomy.⁸

Alcohol-induced septal infarction differs from ischemic necrosis. Alcohol causes tissue injury by a chemical necrotizing effect, acute dehydration, and fixation of the surrounding tissues.⁹ Necrotic tissue lacks infiltration and phagocytosis by leukocytes and macrophages and does not transform into granulation tissue.⁹ The consequence of ASA is patchy necrosis and scar tissue occurring in the interventricular septum with unpredictable size and irregular border.⁹ As a result, this increases the risk of damage to the conduction system and adjacent tissues (Figure 1).

Septal reduction treatments with alternative agents have come to the fore and are in the trial phase to reduce this risk. For this purpose, many substances such as coil, polyvinyl alcohol particles, radiofrequency, endocardial ablation with cryo, gelatin particles, glue, and Ethylene-vinyl alcohol (EVOH)-dimethyl sulfoxide (DMSO) were used.¹⁰⁻¹⁵ The agents preferred for this purpose generate ischemic necrosis, whose necrosis borders, and pathophysiology are more clearly known than chemical necrosis. However, some

ABBREVIATIONS

AF/AFL	Atrial fibrillation/atrial flutter
ANOVA	Analysis of Variance
ASA	Alcohol septal ablation
AV	Atrioventricular block
DMSO	Dimethyl sulfoxide
ECG	Electrocardiogram
EVOH	Ethylene vinyl alcohol
HCM	Hypertrophic cardiomyopathy
ICD	Implantable cardioverter defibrillator
LAD	Left anterior descending
LBBB	Left bundle branch block
LV	Left ventricular
LVOT	Left ventricular outflow tract
MR	Mitral regurgitation
NSVT	Non-sustained ventricular tachycardia
PRISMA	Preferred Reporting Items for Systematic Reviews and Meta-Analyses
RBBB	Right bundle branch block
RF	Radiofrequency
SPSS	Statistical Package for Social Sciences
VT	Ventricular tachycardia

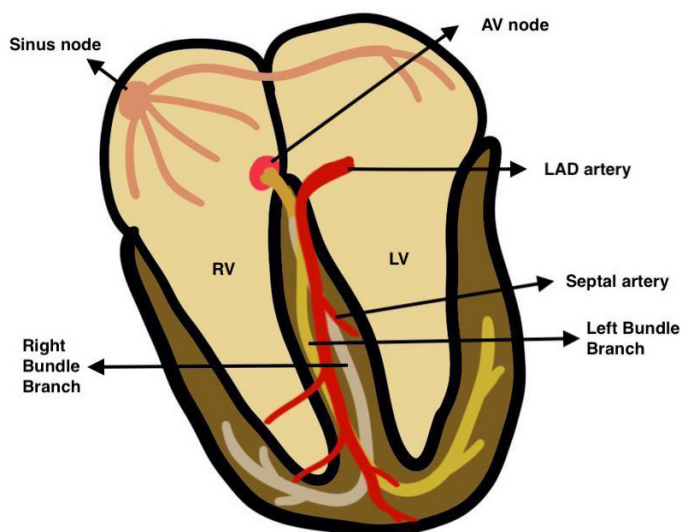


Figure 1. Schematic illustration of the septal arteries and the conduction system.

of these agents, like coils, could not occlude to arterioles and microvascular circulation; the collateral flow that develops over time may cause LVOT obstruction to recur. Causing a septal artery occlusion deep down the distal arterioles or even deeper may be promising, which may require less viscous fluid embolic agents with better penetration. N-butyl-cyanoacrylate (glue), dehydrated ethanol, and a composite of EVOH-DMSO (Onyx® and Squid®) are among such fluid agents and are mainly used for the treatment of arteriovenous malformations by neuroradiological interventions.¹⁶ Compared with acrylic agents like cyanoacrylate, EVOH-DMSO is nonadhesive, and exhibits a less viscous formulation, which can penetrate further into the arterioles.¹⁶ This property is the main reason we used it in our septal ablation procedures. This study will compare the frequency of conduction system defects with other alternative agents in the literature by using the conduction system defects data in our previous septal reduction treatment study with EVOH-DMSO.

Methods

Patients who were diagnosed with symptomatic obstructive HCM and underwent septal ablation with EVOH-DMSO between March 2013 and December 2015 were analyzed. Inclusion criteria for the study were an age of >18 years old, the presence of New York Heart Association class II or more symptoms despite optimal medical therapy, and resting, or provocation induced LVOT gradient of more than 50 mmHg. Patients with any other indication for cardiovascular surgery or with a small-sized (<2.5 French) septal artery were excluded from the study.

After the procedure, all the patients were closely monitored for at least 24 hours, and transthoracic echocardiog-

raphy, and ECG were performed in the coronary care unit. If a severe conduction block did not develop, the temporary pacemaker was withdrawn in the first 24 hours. Cardiac biomarkers were measured every 6 hr until the peak value was reached. The LVOT gradient was measured before and 24 hours after the procedure, and the patients were discharged if no complications occurred after cardiac biomarker levels decreased. Patients were assessed at 3, 6, and 12-month follow-up visits. Clinical assessment, ECG, detailed transthoracic echocardiography, and 24 hr Holter monitorization and cardiac device interrogation results were performed at each visit. All major cardiovascular adverse events, including all-cause death, were recorded during follow-up if present. Pre-procedural electrocardiograms (ECG) were obtained from the files of all patients, and comparisons were made with post-procedure and follow-up ECGs. Holter records and cardiac device interrogation data were investigated for ventricular and atrial tachycardia attacks. Next, by examining the control records before and after the procedure, the frequency of arrhythmic episodes was compared in all cases.

EVOH-DMSO Septal Ablation Procedure

All procedures were performed under local anesthesia. At first, a temporary pacemaker was introduced via the femoral vein in patients without cardiac pacemaker devices. Initially, the left main coronary artery was cannulated with 7 French (F) guiding catheters, and a 0.014-inch guidewire was advanced through the septal branch of the LAD artery. Afterwards, the septal branch was selectively cannulated with a 2.4 French (DMSO)-compatible microcatheter (Echelon or Rebar from EV3, Irvine, California, Sonic from Balt, Montmorency, France). In cases with difficult access to the target artery, a 4 F catheter (Glide Cath Vertebral, Terumo Europe NV, Leuven, Belgium) was used as a support catheter. Selective coronary angiography of the septal artery was performed to show the anatomy and collateral branches supplying the septal segment of the left ventricular myocardium. At this stage, to identify the target septal artery, myocardial contrast echocardiography was performed. Standard intra-arterial contrast agents used for coronary angiography were used as an echo contrast agent instead of a specific substance, and to identify the appropriate septal artery, myocardial staining images by the radio-opaque agent obtained with selective septal angiography were used. Once the microcatheter was positioned at the desired point, the injection of EVOH was carried out as follows: the microcatheter was flushed with 5 ml of normal saline; DMSO was injected into the microcatheter to fill the dead space; EVOH aspirated into a 1-ml syringe was slowly injected under continuous fluoroscopy. EVOH copolymer injection was initiated from the distal portion of the septal artery and continues until a proximal safe distance of 10 mm to the LAD artery.

If 1 ml of EVOH was not found to be sufficient, the injection was continued until the targeted blockage was achieved in the septal artery. The main factor determining the amount of EVOH used is the size of the septal artery; after the occlusion to the safe area was reached, the infusion was terminated. Due to the nonadhesive property of EVOH, the filling of the septal artery was checked under fluoroscopy or angiography during its injection. After the occlusion of the septal artery, the microcatheter, and the whole system were withdrawn together¹⁵ (Figure 2).

Literature Search and Data Extraction

We accomplished a computerized literature search of all English language publications in PubMed. The systematic literature review we conducted for our study aimed to examine the leading non-alcohol septal ablation studies.

Next, a search was performed using three sets of keywords in combination. The first set included "cardiomyopathy, familial" or "cardiomyopathy, hypertrophic." The second set included the terms "ASA" or "septal reduction" or "septal ablation," and the third set included the terms "non-alcohol agent" or "glue" or "coil" or "endocardial RF" or "Polyvinyl alcohol" or "Ethylene-vinyl alcohol." The search was conducted following the Preferred Reporting Items for Systematic Reviews and Meta-Analyses guidelines.

The study was organized according to the World Medical Association Declaration of Helsinki revised form in 2013, and the local ethics committee approved the study protocol (Ethics Committee Decision no: GO 15/785-20, evaluation date 16.12.2015).

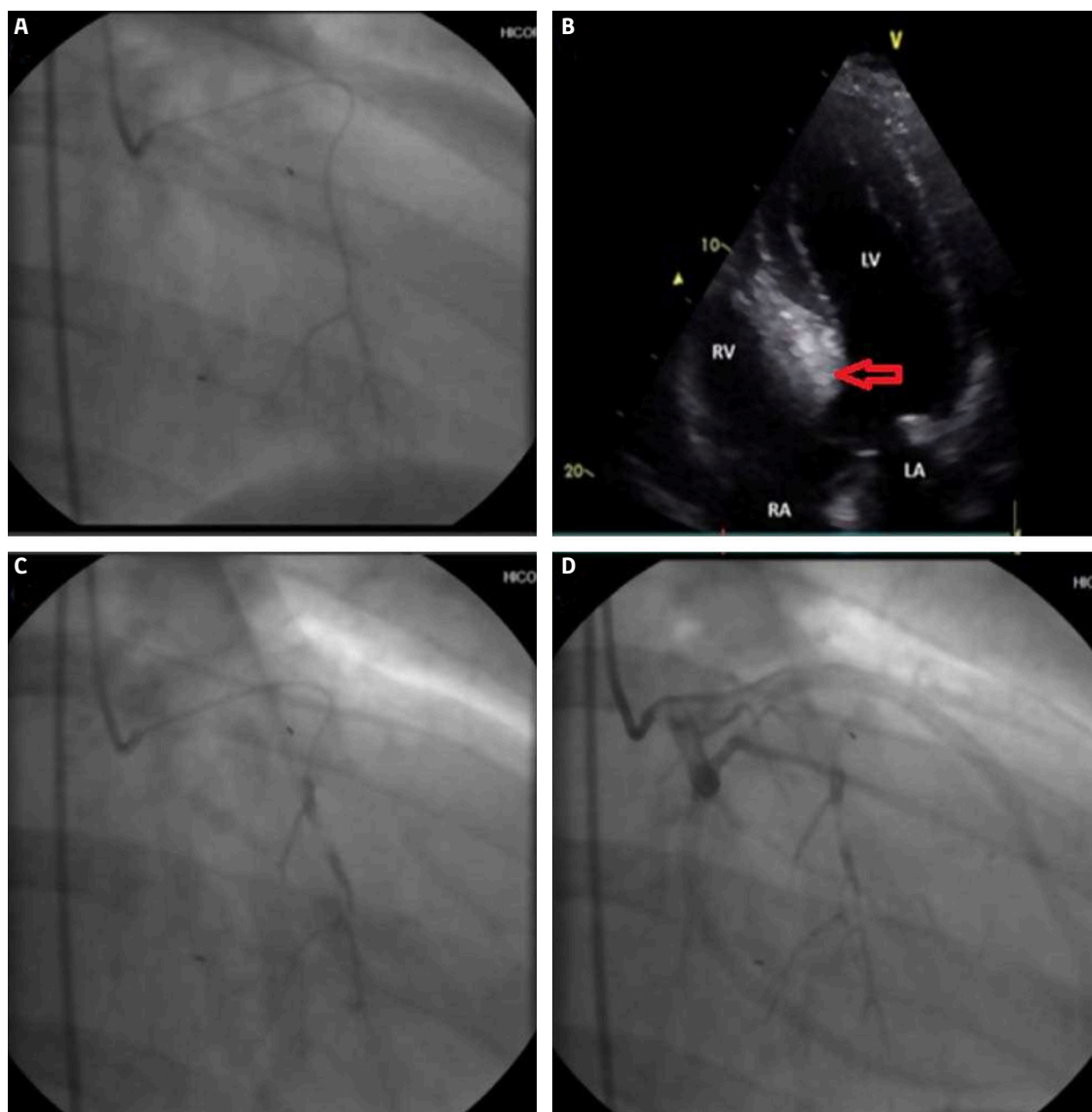


Figure 2. (A) Appropriate Septal branch was selectively cannulated with a 2.4 French (DMSO)-compatible microcatheter. (B) Basal septum images with contrast echocardiography during selective septal angiography (red arrow). (C) EVOH-DMSO injection from the distal segment to the proximal. (D) Final angiography septal artery occlusion.

Statistical Analysis

Statistical analysis was performed using the Statistical Package for Social Sciences (SPSS) for Windows 20 (IBM SPSS Inc., Chicago, IL). The normal distribution of the data was evaluated with the Kolmogorov-Smirnov test. Among the numerical variables, those with normal distribution were shown as mean ± standard deviation, and those with abnormal distribution were shown as median (min-max). Next, categorical variables were expressed as numbers and percentages. "Paired samples t-test" was used for pre-and post-process comparisons, and "Wilcoxon signed-rank test" was used for data that were not normally distributed. In comparing all follow-up periods, the "repeated samples ANOVA test" was used for normally distributed variables, and the "Friedman test" was used for non-normally distributed variables. A Bonferroni correction was made in a double comparison of the significant follow-up times. A p value of <0.05 was considered significant in statistical analyses.

Results

A total of 25 obstructive HCM patients (13 women (52%); mean age 55.8 ± 17.1 years) who underwent septal ablation with EVOH-DMSO were included in the study. Baseline characteristics of the study population are shown in Table

Table 1. Demographic characteristics of the study population

Variables	Patients (n=25)
Age (years)	55.8 ± 17.1
Gender	
Women	13 (52.0)
Men	12 (48.0)
Body mass index (kg/m ²)	30.1±4.8
Diabetes mellitus	22 (88%)
Hypertension	11 (44%)
Chronic kidney disease	1 (4%)
Chronic obstructive lung disease	1 (4%)
Coronary artery disease	1 (4%)
Disease duration (month)	36 (2-240)
Medical treatment	
Beta blockers	21 (84.0)
Calcium channel blockers	4 (16.0)
Pre-procedural pacemaker/ICD status	
No	15 (60.0)
VVI-PM	1 (4.0)
DDD-PM	-
VVI-ICD	-
DDD-ICD	9 (36.0)

Numerical variables with normal distribution were shown as mean ± standard deviation. Categorical variables were shown as numbers (%). ICD: Implantable cardioverter defibrillator.

1. The median peak-to-peak LVOT gradient measured in the catheter laboratory of the patients before the procedure decreased significantly after the procedure (68 mmHg vs. 20 mmHg; *P* <0.001). A significant decrease in the LVOT gradient continued in the follow-up, and it was found to be 23 (0-145) mmHg at the 12th-month follow-up (*P* <0.001) (Figure 3).

During the procedure, septal ablation was performed by occlusion of one septal branch in 20 patients (80%), while two septal branches were occluded in 5 patients (20%). While no mortality was detected during the procedure, complications developed in 3 (12%) patients. Of these complications, 2 (8%) are complete AV block that need to be treated with a permanent pacemaker, and 1 (4%) is EVOH-DMSO embolization. Embolization occurred to the first diagonal artery and did not result in adverse clinical outcomes. Procedural details are shown in Table 2.

ECG recordings before the procedure revealed that 23 patients (92%) were in sinus rhythm, and two patients (8%) were in AF. Three (12%) patients with sinus rhythm demonstrated left bundle branch block (LBBB), and 2 demonstrated right bundle branch block (RBBB). While the number of patients with RBBB increased to 9 (36%) after the procedure, researchers showed that the number of patients with LBBB decreased to 1, and complete AV block developed in 2 patients who demonstrated pre-procedural LBBB (*P* = 0.002). In one patient who developed a complete AV block, one septal artery ablation was performed; two septal artery ablations were performed on the other. Next, AV blocks were treated with permanent pacemakers, but in the follow-up, researchers observed that they were not pacemaker dependent and returned to LBBB again. Similarly, researchers observed that four patients who de-

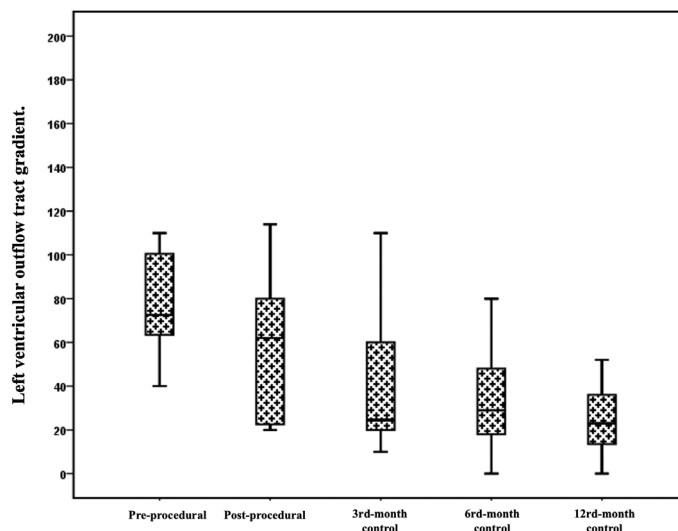


Figure 3. Echocardiographic gradient change of the left ventricular outflow tract.

veloped RBBB returned to sinus rhythm with narrow QRS. Although no significant difference was found in the average PR interval and QRS duration during the entire follow-up ($P > 0.05$), researchers determined that the average PR

interval decreased in the 12th month, and the QRS duration was at the longest level after the procedure and in the 3rd-month control. ECG change findings are summarized in Table 3.

Table 2. Procedural details

Variables	Pre-procedural	Post-procedural	P
LVOT gradient (mmHg) measurements with the catheter (mmHg)	68 (50-110)	20 (0-70)	<0.001*
Number of occluded septal branches with EVOH-DMSO			
1	20 (80.0)	-	-
2	5 (20.0)	-	-
Mortality	-	-	-
Complication			
No	-	22 (88.0)	-
Yes	-	3 (12.0)	-
Complete AV block		2 (8.0)	
EVOH-DMSO embolization		1 (4.0)	

Numerical variables with normal distribution were shown as mean \pm standard deviation.

Categorical variables were shown as numbers (%).

* $P < 0.05$ is statistically significant

LVOT: Left ventricular outflow tract; EVOH-DMSO: Ethylene-vinyl alcohol, dimethyl sulfoxide; AV: Atrioventricular.

Table 3. Changes in electrocardiography parameters in pre-procedural and follow-up periods

Variables	Pre-procedural	Post-procedural	Control visits			P
			3. Month	6. Month	12. Month	
ECG						0.002*
Sinus rhythm	23 (92.0)	21 (84.0)	22 (91.7)	22 (91.7)	22 (91.7)	
LBBB	3 (12.0)	1 (4.0)	3 (12.5)	3 (12.5)	3 (12.5)	
RBBB	2 (8.0)	9 (36.0)	8 (33.3)	6 (25.0)	5 (20.8)	
AF	2 (8.0)	2 (8.0)	2 (8.3)	2 (8.3)	2 (8.3)	
Complete AV block	-	2 (8.0)	-	-	-	
PR interval (mm)	172 \pm 40	188 \pm 43	172 \pm 22	172 \pm 32	166 \pm 18	0.108
QRS duration (mm)	107 \pm 24	121 \pm 29	120 \pm 31	111 \pm 27	115 \pm 26	0.111

Numerical variables with normal distribution were shown as mean \pm standard deviation.

Categorical variables were shown as numbers (%).

* $p < 0.05$ indicates statistical significance.

ECG: Electrocardiography, LBBB: Left bundle branch block, RBBB: Right bundle branch block, AF: Atrial fibrillation, AV: Atrioventricular.

Table 4. Arrhythmia episodes evaluation before the procedure and at the controls

Variables	Pre-procedural	Post-procedural	Control visits			P
			3. Month	6. Month	12. Month	
Holter monitorization/ Pacemaker, ICD control						
Normal	21 (84.0)	-	19 (79.2)	19 (79.2)	19 (79.2)	0.949
VT	-	-	-	-	-	
NSVT	1 (4.0)	-	-	1 (4.2)	2 (8.3)	
AF/AFL	3 (12.0)	-	5 (20.8)	4 (16.7)	3 (12.5)	
AV block	-	-	-	-	-	

Numerical variables with normal distribution were shown as mean \pm standard deviation.

Categorical variables shown as numbers (%)

* $p < 0.05$ indicates statistical significance

ICD: Implantable cardioverter defibrillator; VT: Ventricular Tachycardia; NSVT: Non-sustained ventricular tachycardia; AF/AFL: Atrial fibrillation/atrial flutter; AV: Atrioventricular block.

No change was found in AF and ventricular tachycardia frequency after the procedure and in the controls ($P = 0.949$). However, one patient suffering from frequent paroxysmal AF attacks both before and after the septal ablation procedure demonstrated a cryoballoon AF ablation performed in the follow-up period. The findings are summarized in Table 4.

Discussion

LVOT gradient is the primary determinant in developing symptoms and treatment approaches in patients with HCM.^{3,4} In cases whose symptoms persist despite medical treatment, surgical myectomy and ASA are the main treatment options applied to reduce septal thickness.^{3,4} This study highlighted successful septal reduction therapy with acceptable conduction system defect rates with an alternative septal embolization agent, EVOH-DMSO.

In our study, complete AV block developed in 2 patients (8%), and RBBB developed in 9 patients (36%). Researchers observed that the patients who developed complete AV block did not need a permanent pacemaker at the third-month follow-up and pacemaker dependency $<1\%$ in the last month. Permanent pacemaker implantation due to AV block is a fundamental problem in surgical myectomy and ASA. While the risk of complete AV block after surgical septal myectomy is around 1%–4%, the rate of development of LBBB reaches 40%.^{17,18} ASA is a treatment method in experienced centers with long-term results as effective as surgery.^{6,19} The risk of developing complete AV block after ASA varies between 7%–20%.^{4,8,19-21} Due to the high frequency of procedure-related complications with ASA, a need exists for percutaneous ablation techniques with alternative septal embolization agents.¹⁵

The most common conduction system problem after ASA is the development of RBBB, and studies showed that RBBB does not affect prognosis.²² Researchers even showed that the development of RBBB may be correlated with the necrotic area's size and the procedure's success.²³ The incidence of RBBB in our study was 36% (9 patients) and was similar with ASA studies. During the follow-up period, RBBB was ameliorated in 4 patients, like the patients with complete AV block.

The high conduction system complication rates of ASA therapy led to search for alternative treatment approaches. For these purposes, septal ablation studies were performed with the endocardial approach. Lawrenz et al.²⁴ performed septal ablation with endocardial radiofrequency (RF) energy in 19 patients, found that the method effectively reduced the LVOT gradient, and reported that four patients (21%) developed complete AV block. In the same study, research-

ers observed that patients were also pacemaker dependent when they checked after six months.²⁴ In 2016, Crossen et al.²⁵ applied RF ablation to 11 patients using the 3D mapping method and showed LVOT gradient continued decline in long-term follow-up in 10 patients. In this study, intraventricular conduction delays were developed in 5 patients after the procedure, and two patients (17%) underwent permanent pacemaker implantation due to complete AV block.²⁵ In another RF endocardial ablation study conducted with 25 patients in 2021, researchers reported that no patients demonstrated complete AV block and conduction defects.²⁶ In a recent review of septal reduction studies with the endocardial method, 91 patients were examined, and researchers reported that complete AV block developed in 8 (8.8%) patients.²⁷ In light of these data, especially in patients who are not candidates for myectomy due to comorbidities and trans coronary septal reduction therapy due to septal artery anatomy, septal reduction therapy with the endocardial method can be applied with a frequency of conduction defects similar to ASA.

In a septal reduction study with another alternative agent, Durand et al.²⁸ applied septal ablation with a coil to 20 patients with 90% success. However, in the follow-up, they determined that the decrease in the LVOT gradient and septal thickness of the patients was lower than in ASA studies, and the LVOT gradient continued to be more than 50mmHg in 25% of the patients, despite no ventricular tachycardia, and complete AV block being observed.²⁸ Guerrero et al.'s²⁹ coil septal ablation study with 24 patients gave similar results, and only one patient required permanent pacemaker implantation. Due to the incomplete occlusion of all thin branches in the septal ablation procedure with the coil, transmural infarction cannot occur. The development of collateral vessels in the follow-up is thought to be the most critical factor limiting the success of the coil method and reducing the possible complication rate.

The first of the septal reduction studies with liquid-based embolic agents instead of alcohol was performed by Gross et al.¹¹ This study applied polyvinyl ASA to 18 patients, and symptomatic benefit, and gradient reduction were achieved in all patients.¹¹ Although transient AV block developed in 3 patients during the procedure, all of them recovered in the follow-up, and no need exists for a permanent pacemaker. However, this study stated that a need exists for repeat procedures during the follow-up period in 4 patients.¹¹ Septal ablation with cyanoacrylate (glue), another liquid-based embolic agent, was successfully applied to 18 patients without complications.¹⁴ While ventricular tachycardia and complete AV block were not reported after the procedure, RBBB was reported in 3 patients (16.6%) and left axis deviation in 2 patients (11.1%). In a review, in which 17-month

Table 5. Conduction system disturbances in main septal reduction therapy studies performed with the alternative agents in the literature

Author	Patient number	Septal reduction	AV block	LBBB	RBBB
Lawrenz T et al ²⁴	19	Endocardial RF	4 (21%)	-	-
Crossen et al ²⁵	11	Endocardial RF	2 (17%)	5 patients (45.4%) developed intraventricular conduction delays	
Kong et al ²⁶	25	Endocardial RF	-	-	-
Durand E et al ²⁸	20	Coil	-	1 (5%)	1 (5%)
Guerrero et al ²⁹	24	Coil	1	-	-
Gross et al ¹¹	18	Polyvinyl alcohol	3 (16.6%) (Early phase transient)	-	-
Oto et al ¹⁴	18	Cyanoacrylate (glue)	-	-	3
Asil et al ¹⁵	25	Ethylene-vinyl alcohol	2 (8%) (Late phase transient)	-	7 (28%) (4 patients returned to sinus in long term)

RF: Radiofrequency; AV: Atrioventricular; LBBB: Left bundle branch block; RBBB: Right bundle branch block.

mean follow-up data were published, researchers reported that hemodynamic and symptomatic benefits continued. No late ventricular tachycardia and complete AV block were detected.³⁰ Conduction system defects in primary septal reduction therapy studies performed with the alternative agents in the literature are summarized in Table 5.

Further, the chemical necrosis in ASA patients is like tissue melting, with unpredictable size, and irregular borders.⁹ However, alternative septal ablation agents usually cause ischemic necrosis, tissue viability may be regenerated with distal collateral flows over time, and conduction defects may recover, but this may create the risk of recurrence of LVOT obstruction.¹⁴ Here, the main factor determining the effectiveness of non-alcoholic septal ablation agents is the extent of ischemic necrosis that a particular agent causes and how far it penetrates further into the distal vascular bed and arterioles. Next, EVOH-DMSO could be the most effective non-alcoholic agent because of the penetration capability to the distal arterioles. In addition, ischemic necrosis with a demarcation line and the collateral flow that develops over time in the distal arteries protects the patient against conduction system problems, but it brings a recurrence risk of the gradient. In our series, recurrence of LVOT gradient occurred in 3 (12%) patients at a 6-month follow-up visit.

Due to the possibility of conduction system recovery, pacemaker implantation time is critical. Intraprocedural or early post-procedural transient complete AV block may be related to septal ablation, causing inflammation, and edema. Generally, in ASA trials, pacemakers are implanted within 2-4 days of ASA if complete AV block persists; however, some authors reported that AV nodal recovery may still occur beyond this period, suggesting to defer pacemaker implantation may be appropriate.³¹⁻³³ In septal ablation with

non-alcoholic agents, AV node recovery may occur more extended. Therefore, although it seems reasonable to wait longer, no recommendation for this exists. Pacemaker implantation time should be determined with an individual approach and decided according to patient clinical characteristics and conduction defect characteristics.

No statistically significant change was found in arrhythmic episodes during the follow-up in our study. Studies are found on the increase in the frequency of arrhythmias due to scar tissue after ASA, and the frequency of sudden cardiac death after ASA is reported to be 3%-10%.³⁴ In published studies, the frequency of ventricular tachycardia in the first 30 days after the procedure varies between 1%-4%.^{35,36} In our study, non-sustained ventricular tachycardia runs were observed in 2 patients (8%) at the 12th-month follow-up in Holter records, but no general increase was found in arrhythmic episode frequency.

AF risk is increased 4-6 times in patients with HCM, and it is the most common arrhythmia.^{3,4} In a review published in 2013, the frequency of AF was 22.5%, and the incidence was 3.1%.³⁷ Researchers reported that the frequency of AF can reach 37% from the data obtained by examining the post-ASA records of patients with permanent pacemakers.³⁸ In this study, 2 (8%) patients demonstrated permanent AF, and one patient demonstrated paroxysmal AF before the procedure. Also, no statistically significant increase was found in the frequency of AF during the follow-up ($P > 0.05$). Cryo-AF ablation was performed in 1 patient due to frequent paroxysmal AF attacks after six months of follow-up, and a significant benefit was observed.

Since septal ablation methods with alternative agents act with ischemic necrosis rather than chemical necrosis, ne-

crisis occurs in a more limited area, and the risk of complications is lower.^{14,28,30} The liquid embolic agents, glue, EVOH-DMSO, and dehydrated alcohol result in some differences. Penetration of glue particles into vessels and tissues is successful.³⁹ However, the most significant disadvantage is that it can polymerize very quickly when in contact with liquid or blood, causing adhesion, and avulsion in the microcatheter.³⁹ For this reason, a swift, and continuous injection is required.³⁹ Because EVOH-DMSO is less adhesive and exhibits better deep vessel penetration than other agents, it penetrates up to the distal bed of the septal vessel and causes extensive ischemic necrosis. Thus, while EVOH-DMSO septal ablation provides a gradient decrease similar to ASA, it is thought that the risk of AV block may be lower than ASA and higher than other trans coronary alternative agents.

Conclusion

EVOH-DMSO can cause conduction system problems less than alcohol but more frequently than other alternative agents in septal reduction therapy. Considering the correlation of post-ASA conduction system problems with efficacy, EVOH-DMSO could be an alternative agent closest to ASA because of its alcohol content and less viscous formulation, which can penetrate further into the arterioles. However, comparative studies are needed to identify the best non-alcoholic septal ablation agent.

Ethics Committee Approval: This study was approved by the Hacettepe University Ethics Committee (Decision no: GO 15/785-20; Evaluation date: 16.12.2015).

Informed Consent: Written informed consent was obtained from the participants of this study.

Peer-review: Externally peer-reviewed.

Author Contributions: Concept – S.A., K.A.; Design – S.A., K.A.; Supervision – K.A.; Resources – S.A., K.A.; Materials – S.A.; Data Collection and/or Processing – S.A.; Analysis and/or Interpretation – S.A., K.A.; Literature Search – S.A.; Writing Manuscript – S.A.; Critical Review – K.A.

Declaration of Interests: The authors declare that they have no competing interest.

Funding: This study received no funding.

References

1. Maron BJ, Gardin JM, Flack JM, et al. Prevalence of hypertrophic cardiomyopathy in a general population of young adults. Echocardiographic analysis of 4111 subjects in the CARDIA Study. Coronary artery risk development in (young) adults. *Circulation*. 1995;92(4):785–789. [\[CrossRef\]](#)
2. Wigle ED, Rakowski H, Kimball BP, et al. Hypertrophic cardiomyopathy. Clinical spectrum and treatment. *Circulation*. 1995;92(7):1680–1692. [\[CrossRef\]](#)
3. Authors/Task Force members, Elliott PM, Anastakis A, et al. 2014 ESC Guidelines on diagnosis and management of hypertrophic cardiomyopathy: the Task Force for the Diagnosis and Management of Hypertrophic Cardiomyopathy of the European Society of Cardiology (ESC). *Eur Heart J*. 2014;35(39):2733–2779. [\[CrossRef\]](#)
4. Ommen SR, Mital S, Burke MA, et al. 2020 AHA/ACC Guideline for the diagnosis and treatment of patients With hypertrophic cardiomyopathy: A report of the American College of Cardiology/American Heart Association Joint Committee on clinical practice guidelines. *Circulation*. 2020;142(25):e558–e631. [\[CrossRef\]](#)
5. Maron MS, Olivetto I, Betocchi S, et al. Effect of left ventricular outflow tract obstruction on clinical outcome in hypertrophic cardiomyopathy. *N Engl J Med*. 2003;348(4):295–303. [\[CrossRef\]](#)
6. Nguyen A, Schaff HV, Hang D, et al. Surgical myectomy versus alcohol septal ablation for obstructive hypertrophic cardiomyopathy: A propensity score-matched cohort. *J Thorac Cardiovasc Surg*. 2019;157(1):306–315.e3. [\[CrossRef\]](#)
7. Sigwart U. Non-surgical myocardial reduction for hypertrophic obstructive cardiomyopathy. *Lancet*. 1995;346(8969):211–214.
8. Agarwal S, Tuzcu EM, Desai MY, Smedira N, Lever HM, Lytle BW, Kapadia SR. Updated meta-analysis of septal alcohol ablation versus myectomy for hypertrophic cardiomyopathy. *J Am Coll Cardiol*. 2010;55(8):823–834. [\[CrossRef\]](#)
9. Raute-Kreinsen U. Morphology of necrosis and repair after transcatheter ethanol ablation of septal hypertrophy. *Pathol Res Pract*. 2003;199(3):121–127. [\[CrossRef\]](#)
10. Lafont A, Durand E, Brasselet C, et al. Percutaneous transluminal septal coil embolisation as an alternative to alcohol septal ablation for hypertrophic obstructive cardiomyopathy. *Heart*. 2005;91(1):92. [\[CrossRef\]](#)
11. Gross CM, Schulz-Menger J, Krämer J, et al. Percutaneous transluminal septal artery ablation using polyvinyl alcohol foam particles for septal hypertrophy in patients with hypertrophic obstructive cardiomyopathy: acute and 3-year outcomes. *J Endovasc Ther*. 2004;11(6):705–711. [\[CrossRef\]](#)
12. Lawrenz T, Kuhn H. Endocardial radiofrequency ablation of septal hypertrophy. A new catheter-based modality of gradient reduction in hypertrophic obstructive cardiomyopathy. *Z Kardiol*. 2004 Jun;93(6):493–499. [\[CrossRef\]](#)
13. Llamas-Espérón GA, Sandoval-Navarrete S. Percutaneous septal ablation with absorbable gelatin sponge in hypertrophic obstructive cardiomyopathy. *Catheter Cardiovasc Interv*. 2007;69(2):231–235. [\[CrossRef\]](#)
14. Oto A, Aytemir K, Okutucu S, et al. Cyanoacrylate for septal ablation in hypertrophic cardiomyopathy. *J Interv Cardiol*. 2011;24(1):77–84. [\[CrossRef\]](#)
15. Asil S, Kaya B, Canpolat U, et al. Septal reduction therapy using nonalcohol agent in hypertrophic obstructive cardiomyopathy: Single center experience. *Catheter Cardiovasc Interv*. 2018;92(3):557–565. [\[CrossRef\]](#)

16. Szajner M, Roman T, Markowicz J, et al. Onyx[®] in endovascular treatment of cerebral arteriovenous malformations – a review. *Pol J Radiol*. 2013;78(3):35–41. [\[CrossRef\]](#)
17. Smedira NG, Lytle BW, Lever HM, et al. Current effectiveness and risks of isolated septal myectomy for hypertrophic obstructive cardiomyopathy. *Ann Thorac Surg*. 2008;85(1):127–133. [\[CrossRef\]](#)
18. Cui H, Schaff HV, Nishimura RA, et al. Conduction abnormalities and long-term mortality following septal myectomy in patients with obstructive hypertrophic cardiomyopathy. *J Am Coll Cardiol*. 2019;74(5):645–655. [\[CrossRef\]](#)
19. Sorajja P, Valeti U, Nishimura RA, et al. Outcome of alcohol septal ablation for obstructive hypertrophic cardiomyopathy. *Circulation*. 2008;118(2):131–139. [\[CrossRef\]](#)
20. Kuhn H, Lawrenz T, Lieder F, et al. Survival after transcatheter ablation of septal hypertrophy in hypertrophic obstructive cardiomyopathy (TASH): a 10 year experience. *Clin Res Cardiol*. 2008;97(4):234–243. [\[CrossRef\]](#)
21. Fitzgerald P, Kusumoto F. The effects of septal myectomy and alcohol septal ablation for hypertrophic cardiomyopathy on the cardiac conduction system. *J Interv Card Electrophysiol*. 2018;52(3):403–408. [\[CrossRef\]](#)
22. Jensen MK, Faber L, Liebrechts M, et al. Effect of impaired cardiac conduction after alcohol septal ablation on clinical outcomes: insights from the Euro-ASA registry. *Eur Heart J Qual Care Clin Outcomes*. 2019;5(3):252–258. [\[CrossRef\]](#)
23. Matsuda J, Takano H, Morooka M, et al. Relationship between procedural right bundle branch block and 1-year outcome after alcohol septal ablation for hypertrophic obstructive cardiomyopathy—a retrospective study. *Circ J*. 2021;85(9):1481–1491. [\[CrossRef\]](#)
24. Lawrenz T, Borchert B, Leuner C, et al. Endocardial radiofrequency ablation for hypertrophic obstructive cardiomyopathy: acute results and 6 months' follow-up in 19 patients. *J Am Coll Cardiol*. 2011;57(5):572–576. [\[CrossRef\]](#)
25. Crossen K, Jones M, Erikson C. Radiofrequency septal reduction in symptomatic hypertrophic obstructive cardiomyopathy. *Heart Rhythm*. 2016;13(9):1885–1890. [\[CrossRef\]](#)
26. Kong L, Zhao Y, Pan H, et al. A modified endocardial radiofrequency ablation approach for hypertrophic obstructive cardiomyopathy guided by transthoracic echocardiography: a case series. *Ann Transl Med*. 2021;9(12):1006. [\[CrossRef\]](#)
27. Yang H, Yang Y, Xue Y, Luo S. Efficacy and safety of radiofrequency ablation for hypertrophic obstructive cardiomyopathy: A systematic review and meta-analysis. *Clin Cardiol*. 2021;43(5):450–458.
28. Durand E, Mousseaux E, Coste P, et al. Non-surgical septal myocardial reduction by coil embolization for hypertrophic obstructive cardiomyopathy: early and 6 months follow-up. *Eur Heart J*. 2008;29(3):348–355. [\[CrossRef\]](#)
29. Guerrero I, Dhoble A, Fasulo M, et al. Safety and efficacy of coil embolization of the septal perforator for septal ablation in patients with hypertrophic obstructive cardiomyopathy. *Catheter Cardiovasc Interv*. 2016;88(6):971–977. [\[CrossRef\]](#)
30. Okutucu S, Aytemir K, Oto A. Glue septal ablation: A promising alternative to alcohol septal ablation. *JRSM Cardiovasc Dis*. 2016;5:2048004016636313. [\[CrossRef\]](#)
31. Spencer WH 3rd, Roberts R. Alcohol septal ablation in hypertrophic obstructive cardiomyopathy: the need for a registry. *Circulation*. 2000;102(6):600–601. [\[CrossRef\]](#)
32. Reinhard W, Ten Cate FJ, Scholten M, et al. Permanent pacing for complete atrioventricular block after nonsurgical (alcohol) septal reduction in patients with obstructive hypertrophic cardiomyopathy. *Am J Cardiol*. 2004;93(8):1064–1066. [\[CrossRef\]](#)
33. El-Jack SS, Nasif M, Blake JW, et al. Predictors of complete heart block after alcohol septal ablation for hypertrophic cardiomyopathy and the timing of pacemaker implantation. *J Interv Cardiol*. 2007;20(1):73–76. [\[CrossRef\]](#)
34. ten Cate FJ, Soliman OI, Michels M, et al. Long-term outcome of alcohol septal ablation in patients with obstructive hypertrophic cardiomyopathy: a word of caution. *Circ Heart Fail*. 2010;3(3):362–369. [\[CrossRef\]](#)
35. El-Sabawi B, Nishimura RA, Barsness GW, et al. Temporal Occurrence of Arrhythmic Complications After Alcohol Septal Ablation. *Circ Cardiovasc Interv*. 2020;13(2):e008540. [\[CrossRef\]](#)
36. Noseworthy PA, Rosenberg MA, Fifer MA, et al. Ventricular arrhythmia following alcohol septal ablation for obstructive hypertrophic cardiomyopathy. *Am J Cardiol*. 2009;104(1):128–132. [\[CrossRef\]](#)
37. Guttmann OP, Rahman MS, O'Mahony C, et al. Atrial fibrillation and thromboembolism in patients with hypertrophic cardiomyopathy: systematic review. *Heart*. 2014;100(6):465–472. [\[CrossRef\]](#)
38. Bleszynski PA, Goldenberg I, Fernandez G, et al. Risk of arrhythmic events after alcohol septal ablation for hypertrophic cardiomyopathy using continuous implantable cardiac monitoring. *Heart Rhythm*. 2021;18(1):50–56. [\[CrossRef\]](#)
39. Kim LJ, Albuquerque FC, Aziz-Sultan A, et al. Low morbidity associated with the use of NBCa liquid adhesive for preoperative transarterial embolization of central nervous system tumors. *Neurosurgery*. 2006;59(1):98–104. [\[CrossRef\]](#)