

A case of late thrombosis following treatment of in-stent restenosis with sirolimus-eluting stents due to discontinuation of antiplatelet agents

Stent içi darlığın sirolimus kaplı stentle tedavisi sonrasında antitrombosit ilaçların kesilmesine bağlı gelişen geç tromboz: Olgu sunumu

Uğur Arslan, M.D., Sedat Türkoğlu, M.D., Timur Timurkaynak, M.D.

Department of Cardiology, Medicine Faculty of Gazi University, Ankara

Drug-eluting stents are widely used to prevent restenosis in *de novo* lesions, and for percutaneous treatment of in-stent restenosis. However, their long-term safety profile is still debatable. A 46-year-old female patient was admitted with acute inferoposterior myocardial infarction due to late stent thrombosis that developed after 168 days of implantation of two sirolimus-eluting stents for a restenotic bare metal stent to the right coronary artery. She had been receiving aspirin and clopidogrel, both of which were discontinued for five days for the preparation of a noncardiac operation. Tissue plasminogen activator with heparin and tirofiban was started immediately, which resulted in ST-segment resolution within 30 minutes. Coronary angiography after the completion of t-PA infusion showed TIMI III flow in the right coronary artery. The stents were fully patent and all the thrombus was lysed. Antiaggregant therapy with aspirin and clopidogrel was resumed. Long-term may imply life-time treatment with antiplatelet agents.

Key words: Coronary angiography; coronary stenosis; coronary thrombosis/etiology; myocardial infarction/etiology; platelet aggregation inhibitors; stents/adverse effects.

Stent thrombosis is a rare complication of combined antiaggregant therapy; however, its occurrence usually causes devastating results such as acute myocardial infarction with ST elevation or sudden death. Late stent thrombosis (LST) (>1 month) has become a potential problem after the introduction of drug-eluting stents (DES), which is expected to occur more frequently compared to bare metal stents.^[1-4] This increased frequency may be due to delay in vascular healing and stent endothelialization and to hypersensitivity reactions.^[4,5] To prevent this compli-

Yeni lezyonlarda darlığın tekrarlamasını önlemek için ve stent içi darlığın tedavisinde ilaç kaplı stentler günümüzde yaygın olarak kullanılmaktadır. Ancak, ilaç kaplı stentlerin uzun dönem komplikasyonları hala tam olarak aydınlatılmamıştır. Bu yazıda, sağ koroner artere takılan metal stentte darlık gelişmesi sonucu iki adet sirolimus kaplı stent takılan ve bu işlemten 168 gün sonra geç stent trombozuna bağlı akut inferoposterior miyokard infarktüsü ile başvuran 46 yaşında bir kadın hasta sunuldu. Hastanın kullanmakta olduğu aspirin ve klopidogrel, kalp dışı bir cerrahi işlem için beş gün önce kesilmişti. Heparinli doku plazminojen aktivatörü ve tirofiban ile tedaviye başlanmasından 30 dakika sonra ST-segment gerilemesi sağlandı. İnfüzyon tedavisinin tamamlanmasından sonra yapılan koroner anjiyografide sağ koroner arterde TIMI III akım görüldü; stentler tamamen açıldı ve trombüs kaybolmuştu. Hastada aspirin ve klopidogrel tedavisine yeniden başlandı. Antitrombosit ilaçların uzun dönem kullanımı, yaşam boyu kullanım anlamına gelebilir.

Anahtar sözcükler: Koroner anjiyografi; koroner darlık; koroner tromboz/etyoloji; miyokard infarksiyonu/etyoloji; trombosit agregasyon inhibitörü; stent/yan etki.

cation, long-term combined antiaggregant therapy with aspirin and thienopyridines is recommended for 6-12 months.^[6] Yet, long-term safety profile of DES and optimum duration of antiplatelet therapy are unknown, especially if DES implantation has been performed for in-stent restenosis, in which case metal burden becomes quite high. Here, we report a patient who developed late thrombosis secondary to in-stent restenosis that resulted from Cypher stent implantation and discontinuation of antiaggregant medications.

Received: June 19, 2006 Accepted: August 1, 2006

Correspondence: Dr. Uğur Arslan, Gazi Üniversitesi Tıp Fakültesi, Kardiyoloji Anabilim Dalı, Beşevler, 06510 Ankara.
Tel: 0312 - 202 56 29 Fax: 0312 - 000 00 00 e-mail: ugurarslan5@yahoo.com

CASE REPORT

A 46-year-old female patient was admitted to our hospital with acute inferoposterior myocardial infarction. She was a smoker and had a history of diabetes mellitus and hyperlipidemia. In January 2005, she had undergone bare metal stent implantation (size not known) in another institution to the mid-portion of the right coronary artery after the diagnosis of myocardial infarction without ST-segment elevation. In May 2005, coronary angiography was repeated because of anginal symptoms and diffuse in-stent restenosis was detected. The lesion was dilated with balloon angioplasty and two overlapping sirolimus-eluting stents (3.0 mm in diameter; 33 mm and 13 mm in length, respectively; Cypher, Cordis, Miami, FL, USA) were applied to cover the entire restenotic lesion. She was discharged on clopidogrel and aspirin treatment.

Laparoscopic cholecystectomy was planned for symptomatic cholelithiasis five months later in October 2005, for which aspirin and clopidogrel treatment was stopped. Repeat coronary angiography showed a focal restenosis (30%) in the Cypher stent (Fig. 1a). However, she was admitted with acute inferoposterior myocardial infarction after 168 days of DES implantation and five days of discontinuation of dual antiplatelet agents (Fig. 2a). Tissue plasminogen activator (t-PA) with heparin and tirofiban was started immediately, which resulted in ST-segment resolution within 30 minutes (Fig. 2b). Emergency

coronary angiography after the completion of t-PA infusion showed TIMI III flow in the right coronary artery. The stents were fully patent and all the thrombus was lysed (Fig. 1b). No percutaneous intervention was considered and antiaggregant therapy with aspirin and clopidogrel was resumed to be used for life-time. No complications developed during hospitalization and a stress ECG test was negative before hospital discharge.

DISCUSSION

Stent thrombosis is a feared complication with severe clinical consequences. Late stent thrombosis which is defined as that occurring after 30 days of stent implantation is a rare complication of percutaneous coronary interventions.^[7] However, its incidence seems to be increasing with the widespread use of DES. The mechanism of LST is thought to be similar to that of intracoronary brachytherapy whose incidence is as high as 3.3% to 4.2%.^[8] As in intracoronary brachytherapy, delay in arterial healing and endothelization seems to be an important aspect in the pathophysiology of LST with DES.^[1-4] Because of this delay, long-term combined antiaggregant therapy with aspirin and thienopyridines is strongly recommended. In a recently published study by Ong et al.^[9] there was no LST case with sustained dual antiaggregant therapy. Moreover, there is no report of LST in the literature in the presence of combined aspirin and clopidogrel treatment. These findings support long-term treatment with aspirin combined with thienopy-

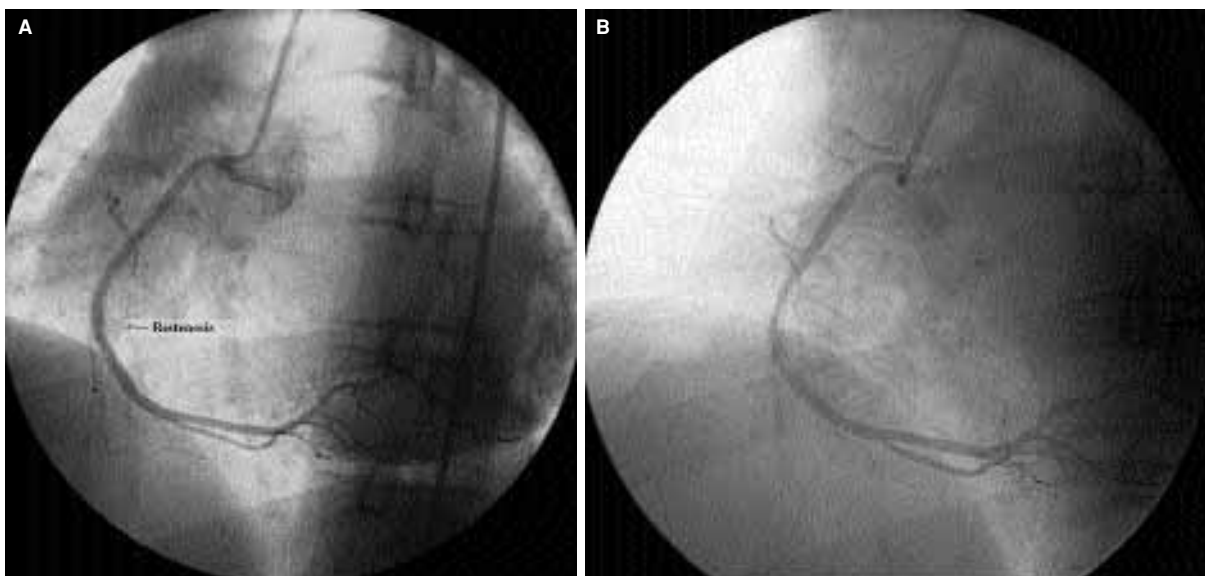


Figure 1. (A) Coronary angiogram showing focal (30%) restenosis five months after balloon angioplasty and implantation of two overlapping sirolimus-eluting stents. **(B)** Coronary angiogram after thrombolytic therapy showing full patency.

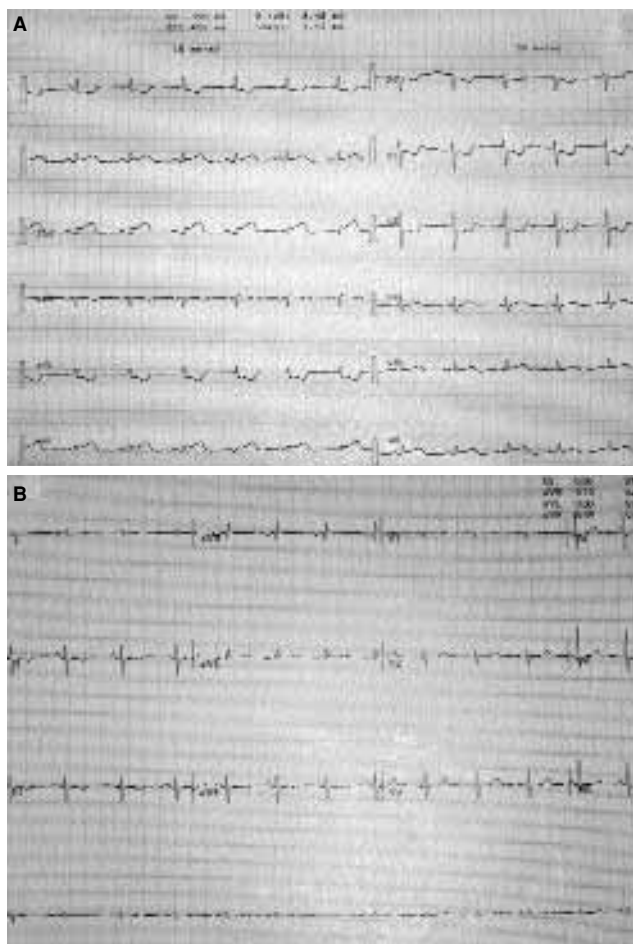


Figure 2. (A) An electrocardiogram showing acute inferior-posterior myocardial infarction after 168 days of sirolimus-eluting stent implantation. **(B)** ST-segment resolution during thrombolytic therapy.

ridines. Although the most recent guidelines recommend three months for sirolimus- and six months for paclitaxel-eluting stents, the optimal duration for antiaggregant therapy in in-stent restenosis with DES is still unknown.^[10]

A meta-analysis covering 5,013 patients in 11 randomized trials showed no difference in short- and medium-term safety profile of DES compared to that of bare metal stents.^[11] However, long term complications such as LST are not well established. Although there is no report of LST during dual antiplatelet therapy, LST does occur when patients are stable on antiplatelet monotherapy. This may be due to several factors such as delayed endothelization, polymerization, hypersensitivity reactions, or aspirin resistance.^[9] On the other hand, there are other reports on the safety of aspirin administered for a long time as the only antiaggregant agent after cessation of clopi-

dogrel.^[12] McFadden et al.^[12] reported that only four cases developed LST after aspirin cessation among 5,013 patients receiving only aspirin monotherapy up to 335 to 442 days after DES implantation. Of these, aspirin was discontinued due to planned noncardiac surgery in three patients.

Very recently, the ERACI III trial reported seven cases of thrombosis among 225 DES implantations, of which three cases were late thrombosis (>6 months, range 204 to 927 days) and were associated with cessation of dual antiplatelet therapy for noncardiac surgery.^[13]

A recent prospective study of 2,229 consecutive patients undergoing successful DES implantation investigated risk factors for stent thrombosis.^[14] The cumulative incidence of stent thrombosis at nine months was 1.3% and was associated with premature discontinuation of antiplatelet therapy, renal failure, bifurcation lesions, diabetes, and low ejection fraction.

Although percutaneous interventions for in-stent restenosis with DES are successful,^[15] long-term consequences of this condition are still unknown. Waters et al.^[16] reported three cases of in-stent restenosis following sirolimus-eluting stent implantation, two of which had prior brachytherapy and developed LST after cessation of dual antiplatelet treatment (8 and 16 months) seven and 14 days before noncardiac surgery, respectively. The other patient experienced LST after six months of dual antiplatelet treatment while still receiving aspirin in the second week of clopidogrel cessation. Nasser et al.^[17] reported two cases of late sirolimus-eluting stent thrombosis occurring four and 21 months after implantation. Both resulted from cessation of aspirin prior to noncardiac surgery. However, the authors did not mention the duration of dual antiplatelet treatment.

A prothrombotic state related to brachytherapy and high metal burden might account for LST besides intrinsic problems inherent to DES itself. In our case, cessation of dual antiplatelet therapy for only five days after receiving it for more than six months led to LST and ended up with acute myocardial infarction. Diabetes and the total length of the overlapping stents (46 mm) might have contributed to the development of LST, as well. In addition, six-month antiplatelet therapy might be inadequate for the endothelization of relatively long, and high metal burden stent applications.

Another issue to be considered for the development of LST is that the overlapping region of the two drug-eluting stents is more prone to thrombosis because, in this region, re-endothelization process is more difficult and takes longer. This was also the case in our patient in whom a long lesion was covered with two overlapping stents

It seems that unanticipated noncardiac operations will be more frequent in the future because the number of DES-implanted patients is rapidly growing. In usual practice, antiaggregant therapy is discontinued before these surgical interventions. A relatively minor laparoscopic surgery was planned in our case and after five days of discontinuation of dual antiplatelet agents acute inferoposterior myocardial infarction developed. It should be kept in mind that even short-term discontinuation of antiplatelet agents may cause stent thrombosis, leading to fatal cardiac complications. To avoid this, surgery should be postponed if the circumstances allow, or antiaggregant therapy should be continued especially if a minor surgery is considered. However, the problem still exists as we still do not know the time such an operation can be performed with safety. Another option may be the use of anticoagulant therapy after discontinuation of antiaggregant therapy. Standard heparin can be started after cessation of antiaggregant therapy and discontinued just before surgery as its plasma half-life is shorter. After the operation, heparin can again be used until antiaggregant therapy is initiated.

In conclusion, the safety profile of DES in the long-term is still unknown. Clinicians should be aware of serious late complications such as LST especially in lesions of in-stent restenosis caused by DES implantations having high metal burden. These patients might constitute a higher risk group for LST in the future than those having *de novo* lesions. We propose that special care be given to those patients receiving dual antiplatelet therapy, which seems to be protective as there is no reported case of LST as long as it is maintained. Long-term may imply life-time treatment with dual antiplatelet agents.

REFERENCES

- Virmani R, Farb A, Guagliumi G, Kolodgie FD. Drug-eluting stents: caution and concerns for long-term outcome. *Coron Artery Dis* 2004;15:313-8.
- Liistro F, Colombo A. Late acute thrombosis after paclitaxel eluting stent implantation. *Heart* 2001;86:262-4.
- Kerner A, Gruberg L, Kapeliovich M, Grenadier E. Late stent thrombosis after implantation of a sirolimus-eluting stent. *Catheter Cardiovasc Interv* 2003;60:505-8.
- Virmani R, Guagliumi G, Farb A, Musumeci G, Grieco N, Motta T, et al. Localized hypersensitivity and late coronary thrombosis secondary to a sirolimus-eluting stent: should we be cautious? *Circulation* 2004;109:701-5.
- Degertekin M, Serruys PW, Foley DP, Tanabe K, Regar E, Vos J, et al. Persistent inhibition of neointimal hyperplasia after sirolimus-eluting stent implantation: long-term (up to 2 years) clinical, angiographic, and intravascular ultrasound follow-up. *Circulation* 2002;106:1610-3.
- Silber S, Albertsson P, Aviles FF, Camici PG, Colombo A, Hamm C, et al. Guidelines for percutaneous coronary interventions. The Task Force for Percutaneous Coronary Interventions of the European Society of Cardiology. *Eur Heart J* 2005;26:804-47.
- Wang F, Stouffer GA, Waxman S, Uretsky BF. Late coronary stent thrombosis: early vs. late stent thrombosis in the stent era. *Catheter Cardiovasc Interv* 2002;55:142-7.
- Waksman R, Ajani AE, Pinnow E, Cheneau E, Leborgne L, Dieble R, et al. Twelve versus six months of clopidogrel to reduce major cardiac events in patients undergoing gamma-radiation therapy for in-stent restenosis: Washington Radiation for In-Stent restenosis Trial (WRIST) 12 versus WRIST PLUS. *Circulation* 2002;106:776-8.
- Ong AT, McFadden EP, Regar E, de Jaegere PP, van Domburg RT, Serruys PW. Late angiographic stent thrombosis (LAST) events with drug-eluting stents. *J Am Coll Cardiol* 2005;45:2088-92.
- American Heart Association [homepage on the Internet]. ACC/AHA/SCAI 2005 Guideline Update for Percutaneous Coronary Intervention. Available from: <http://www.americanheart.org/presenter.jhtml?identifier=3035436>.
- Babapulle MN, Joseph L, Belisle P, Brophy JM, Eisenberg MJ. A hierarchical Bayesian meta-analysis of randomised clinical trials of drug-eluting stents. *Lancet* 2004;364:583-91.
- McFadden EP, Stabile E, Regar E, Cheneau E, Ong AT, Kinnaird T, et al. Late thrombosis in drug-eluting coronary stents after discontinuation of antiplatelet therapy. *Lancet* 2004;364:1519-21.
- Rodriguez AE, Mieres J, Fernandez-Pereira C, Vigo CF, Rodriguez-Alemparte M, Berrocal D, et al. Coronary stent thrombosis in the current drug-eluting stent era: insights from the ERACI III trial. *J Am Coll Cardiol* 2006;47:205-7.
- Iakovou I, Schmidt T, Bonizzoni E, Ge L, Sangiorgi GM, Stankovic G, et al. Incidence, predictors, and outcome of thrombosis after successful implantation of drug-eluting stents. *JAMA* 2005;293:2126-30.
- Werner GS, Emig U, Krack A, Schwarz G, Figulla HR. Sirolimus-eluting stents for the prevention of restenosis

in a worst-case scenario of diffuse and recurrent in-stent restenosis. *Catheter Cardiovasc Interv* 2004;63:259-64.

16. Waters RE, Kandzari DE, Phillips HR, Crawford LE, Sketch MH Jr. Late thrombosis following treatment of in-stent restenosis with drug-eluting stents after discon-

tinuation of antiplatelet therapy. *Catheter Cardiovasc Interv* 2005;65:520-4.

17. Nasser M, Kapeliovich M, Markiewicz W. Late thrombosis of sirolimus-eluting stents following noncardiac surgery. *Catheter Cardiovasc Interv* 2005;65:516-9.