

## Endovascular Therapy of Aortic Rupture Secondary to a Psoas Abscess

### Psoas Absesine Bağlı Aort Rüptürü ve Endovasküler Tedavisi

#### ABSTRACT

Secondary infection of the aorta is a sporadic and life-threatening disease. It is usually caused by infection and abscess in an adjacent structure. The most common mechanism for secondary aortic infection is a psoas abscess eroding the aortic wall, which rarely results in non-aneurysmal aortic rupture. Primary treatment is surgical aortic reconstruction, but the risk of emergency surgical treatment is high. Endovascular aortic stent-graft implantation can be lifesaving in this setting by stopping the bleeding. However, the crucial question of durability and late infections remains unanswered and warrants long-term antibiotic treatment and follow-up. In this report, we present a case of primary psoas abscess, which resulted in non-aneurysmal aortic rupture and its endovascular treatment.

**Keywords:** Aortic rupture, endovascular therapy, psoas abscess

#### ÖZET

Aortun sekonder enfeksiyonu sporadik ve hayatı tehdit eden nadir bir durumdur. Genellikle komşu yapılarıdaki enfeksiyon ve apse nedeniyle oluşur. Sekonder aort enfeksiyonu için en yaygın neden psoas absesidir ve bu durum nadiren anevrizmal olmayan aort rüptürü ile sonuçlanabilmektedir. Primer tedavi cerrahi olarak aort rekonstrüksiyonudur, ancak acil cerrahi tedavi riski yüksektir. Endovasküler aortik stent-greft implantasyonu bu ortamda kanamayı durdurarak hayat kurtarıcı olabilir. Bununla birlikte, uzun dönem sonuçlar ve geç enfeksiyonlar ile ilişkin sorular yanıtız kalmaktadır. Endovasküler tedavi uzun süreli antibiyotik tedavisi ve takibini gerektirmek gibi kısıtlılıklar içermektedir. Bu olgu sunumunda anevrizmal olmayan aort rüptürü ile sonuçlanan bir primer psoas apsesi ve endovasküler tedavisi anlatılmıştır.

**Anahtar Kelimeler:** Aort rüptürü, endovasküler tedavi, psoas apsesi

Primary infected aortic aneurysm is a rare and life-threatening disease. Secondary infection that spreads from a contiguous septic site to the aorta is extremely rare, and its exact incidence is unknown.<sup>1</sup> Infection of the aorta originating from the adjacent tissue usually results in developing a mycotic aortic aneurysm, and direct non-aneurysmal aortic rupture is rare. The disease carries a very poor prognosis because mycotic aortic aneurysms tend to grow rapidly and rupture; patients with mycotic aortic aneurysms often have severe comorbidities, particularly immunodeficiency and coexisting sepsis. Conventional surgical treatment with an aneurysm and infected aortic tissue resection, extensive local debridement, and revascularization by in situ reconstruction or extra-anatomic bypass is the gold standard but has high mortality and morbidity.

The iliopsoas muscle lies adjacent to the abdominal aorta and iliac arteries. An iliopsoas abscess can rarely erode the aortic and iliac arteries wall, resulting in aortic rupture without aneurysmal dilatation. This report presents a case of aortic rupture that developed from a psoas abscess eroding the abdominal aortic wall and its treatment. Even though Ethics Committee approval is not required for case reports in Türkiye, the Declaration of Helsinki was followed, and informed consent was obtained from the patient and relatives to publish this case report.

#### CASE REPORT OLGU SUNUMU

Serkan Asil<sup>ID</sup>  
Suat Görmel<sup>ID</sup>  
Ozan Köksal<sup>ID</sup>  
Selen Eşki<sup>ID</sup>  
Barış Buğan<sup>ID</sup>  
Uygar Çağdaş Yüksel<sup>ID</sup>

Department of Cardiology, Gülhane  
Training and Research Hospital, Ankara,  
Türkiye

#### Corresponding author:

Serkan Asil  
✉ dr\_serkanasil@hotmail.com

**Received:** September 11, 2022

**Accepted:** December 14, 2022

**Cite this article as:** Asil S, Görmel S, Köksal O, Eşki S, Buğan B, Yüksel UÇ. Endovascular therapy of aortic rupture secondary to a psoas abscess. *Türk Kardiyol Dern Ars.* 2023;51(5):353-355.

DOI:10.5543/tkda.2023.63458



Available online at [archivestsc.com](http://archivestsc.com).  
Content of this journal is licensed under a  
Creative Commons Attribution -  
NonCommercial-NoDerivatives 4.0  
International License.

### Case Report

A 75-year-old male patient was admitted to the Emergency Unit with back pain radiating to the left lower limb, fever, and fatigue. His past medical history was unremarkable except for hypertension and coronary artery disease. However, the patient's recent medical history and files showed that he had been admitted to another hospital for back pain and fever 1 month earlier. A psoas abscess was detected in the abdominal computed tomography (CT), and intravenous (IV) antibiotic therapy was started (Figure 1A and B). Abscess drainage was recommended, but the patient did not accept the recommendation and was discharged on oral antibiotic therapy. A month later, the patient was admitted to our hospital with the same complaints. An abdominal CT scan performed at admission showed that the psoas abscess was adjacent to the aorta and the left paravertebral space (Figure 1C and D).

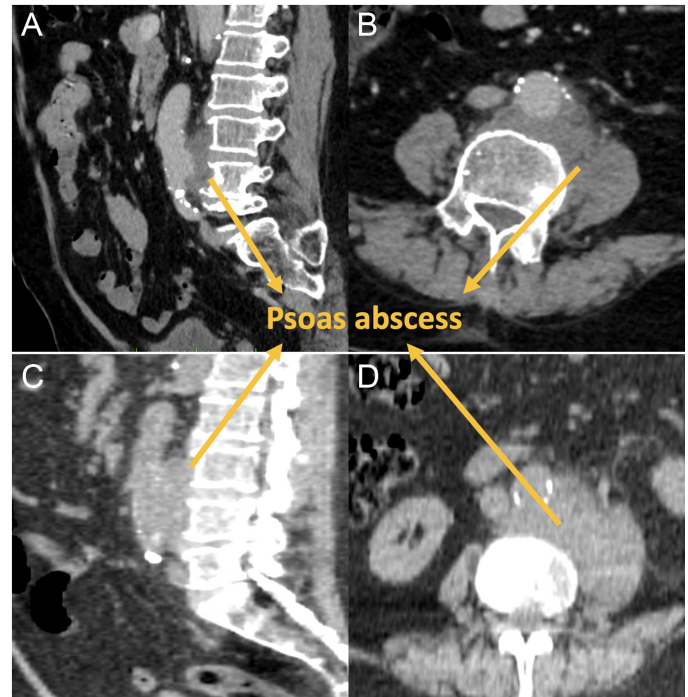
His laboratory examination revealed high levels of inflammatory markers and negative blood cultures; the C reactive protein value, hemoglobin, and white blood cell counts were 208 mg/L, 11.2 g/dL, 15 000 cells/ $\mu$ L, respectively. Other infection sites were ruled out with blood, urine, and sputum cultures; tuberculosis tests; and thoracic and abdominal CT imaging. All cultures were negative, but the tests were performed while the patient was under oral antibiotic therapy. The patient was admitted to the general surgery service with an abscess drainage plan, and IV piperacillin-tazobactam and vancomycin antibiotic therapy. On the third day after admission, the hemoglobin values dropped to 7.8 g/dL. The CT angiography showed a non-aneurysmal rupture of the abdominal aorta (Figure 2A and B). This finding was most likely the consequence of the erosion of the arterial wall by the abscess in the psoas muscle due to the abdominal aorta not dilated on former CT scans, and hemoglobin values were stable for the last month.

The case was discussed at Clinical Conference with the participation of cardiovascular surgery, cardiology, interventional radiology, and general surgery. In order to prevent life-threatening hemorrhage, it was decided to implant an aortic stent graft. A tubular aortic stent graft with a diameter of 28 and 82 mm in length (Endurant II Medtronic, Santa Rosa, Calif, USA) was implanted (Figure 2C and D, Supplementary Video 1). In the postoperative period, the patient's inflammatory symptoms regressed under antibiotic therapy and his hemoglobin level remained stable. Additional aortic surgery and abscess drainage were recommended, but the patient refused and was followed under IV anti-biotherapy for 6 weeks in the clinic and then was discharged. The patient was followed up as an outpatient, and inflammatory marker levels were normal, and he had no complaints. He has been alive for 1 year after the procedure.

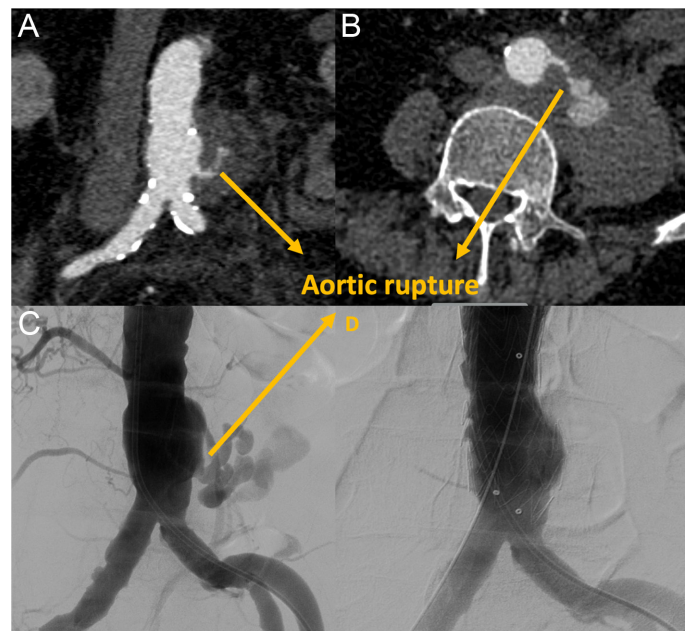
### Discussion

This report describes a rare case of psoas abscess adjacent to the abdominal aorta that eroded the aortic wall and caused non-aneurysmal perforation. This potentially fatal clinical situation can be treated by endovascular techniques.

Aortic rupture due to infection usually results from primary infection of the aorta, and its mortality reaches 20%-40% without



**Figure 1. (A-B)** The axial and sagittal images of psoas abscess in the paravertebral area adjacent to the abdominal aorta on abdominal CT at an urban hospital a month ago. **(C-D)** The images of psoas abscess in the paravertebral area adjacent to the abdominal aorta on abdominal CT in our hospital.



**Figure 2. (A-B)** Psoas abscess and ruptured abdominal aorta on coronal and axial computed tomographic image. **(C)** Angiographic view of the ruptured abdominal aorta. **(D)** Successful endovascular treatment of aortic rupture with aortic stent-graft implantation.

rupture.<sup>1,2</sup> Secondary aortic infection and rupture caused by the direct spread of the microbial agent is a rare clinical situation, and there is limited data in the literature other than rare case reports.

*Salmonella* and *Staphylococcus aureus* are well-known causes of primary vascular infections worldwide.<sup>3</sup> Due to the increasing number of immunocompromised patients and the use of intravesical Bacille Calmette-Guérin applications in bladder cancer, *Mycobacterium tuberculosis* is one of the most frequent microorganisms found to cause contiguous abdominal aorta and iliac arterial infections. Long et al<sup>4</sup> reported 39 cases of tuberculous mycotic aortic aneurysms; 30 cases were secondary to the spread of psoas muscle abscess infection, which was contiguous to the aorta. In another case review of 70 patients with vertebral osteomyelitis and contiguous arterial infection, *Salmonella* was detected in 27% and mycobacterium in 24%.<sup>5,6</sup>

There is no consensus regarding the treatment of infectious arterial ruptures. However, traditionally, the treatment for contiguous aortic infections is primarily surgical. Surgical management involves resection of the involved arterial segment, extensive debridement of infected tissue, drainage of abscesses, and extra-anatomic arterial reconstruction through clean tissue planes or in situ with autologous grafts.<sup>7,8</sup> Nevertheless, the patient's clinical condition and additional comorbidities increase the surgical risk. In this setting, although there is a risk of late graft infection, endovascular aortic stent-graft implantation can be performed to save time and stop the bleeding as quickly as possible. Also recently, the preferred operative technique shifted from surgery to endovascular repair.<sup>9</sup> Especially in cases with high-risk surgery and rupture, the endovascular approach has become the standard treatment as a bridge or as a final therapy.<sup>9</sup> In registry studies, it was reported that endovascular treatment and open arterial surgery results might be similar in the early period and comparable in the late period.<sup>9,10</sup>

Endovascular graft infection should be considered if the infection cannot be controlled at follow-up, and surgical arterial replacement by autologous graft material or extra-anatomic reconstruction should be performed. Shirasu et al<sup>11</sup> analyzed 1203 patients with primary infected abdominal aortic aneurysms in their meta-analysis in 2021. While 359 patients were treated endovascularly, 844 patients underwent open arterial reconstruction.<sup>11</sup> The pooled analyses depicted significantly higher rates of recurrent infection after endovascular therapy than after open arterial reconstruction.<sup>11</sup> However, recurrent infection-related rupture or death, perioperative death, 1-year mortality, and readmission or reintervention were not significantly different statistically between the two groups.<sup>11</sup>

In conclusion, the non-aneurysmal aortic rupture is caused by a psoas abscess adjacent to the abdominal aortic wall infection and is rarely seen as a potentially fatal clinical situation. The risk of emergency surgical treatment may be high. Endovascular

aortic stent-graft implantation can be lifesaving in this setting by stopping the bleeding. However, the crucial question of durability and late infections remains unanswered and warrants long-term antibiotic treatment and follow-up.

**Informed Consent:** Informed consent was obtained from the patient for the publication of the case image and the accompanying images.

**Peer-review:** Externally peer-reviewed.

**Author Contributions:** Concept – S.A., U.C.Y.; Design – S.A., U.C.Y.; Supervision – S.G., B.B.; Funding – S.A.; Materials – S.A., O.K.; Data Collection and/or Processing – S.A., O.K.; Analysis and/or Interpretation – S.A., B.B.; Literature Review – S.A., S.G.; Writing – S.A.; Critical Review – S.A., U.C.Y.

**Declaration of Interests:** The authors declare that they have no competing interest.

**Funding:** This study received no funding.

**Supplementary Video 1:** Angiographic images of aortic rupture and endovascular stent-graft implantation.

## References

1. Lin CH, Hsu RB. Primary infected aortic aneurysm: clinical presentation, pathogen, and outcome. *Acta Cardiol Sin.* 2014;30(6):514-521. [\[CrossRef\]](#)
2. Cinà CS, Arena GO, Fiture AO, Clase CM, Doobay B. Ruptured mycotic thoracoabdominal aortic aneurysms: a report of three cases and a systematic review. *J Vasc Surg.* 2001;33(4):861-867. [\[CrossRef\]](#)
3. Posacioglu H, Islamoglu F, Apaydin AZ, Ozturk N, Oguz E. Rupture of a nonaneurysmal abdominal aorta due to spondylitis. *Tex Heart Inst J.* 2009;36(1):65-68.
4. Long R, Guzman R, Greenberg H, Safneck J, Hershfield E. Tuberculous mycotic aneurysm of the aorta: review of published medical and surgical experience. *Chest.* 1999;115(2):522-531. [\[CrossRef\]](#)
5. McHenry MC, Rehm SJ, Krajewski LP, Duchesneau PM, Levin HS, Steinmuller DR. Vertebral osteomyelitis and aortic lesions: case report and review. *Rev Infect Dis.* 1991;13(6):1184-1194. [\[CrossRef\]](#)
6. Leeman M, Burgers P, Brehm V, van Brussel JP. Psoas abscess after Bacille Calmette-Guérin instillations causing iliac artery contained rupture. *J Vasc Surg.* 2017;66(4):1236-1238. [\[CrossRef\]](#)
7. Inufusa A, Mikawa Y, Morita I, Fujiwara T. Ruptured abdominal aortic aneurysm associated with a psoas abscess. *Arch Orthop Trauma Surg.* 2002;122(5):306-307. [\[CrossRef\]](#)
8. Taylor CF, Lennox AF. Treatment options for primary infected aorta. *Ann Vasc Surg.* 2007;21(2):225-227. [\[CrossRef\]](#)
9. Sörelis K, Wanhainen A, Furebring M, et al. Nationwide study of the treatment of mycotic abdominal aortic aneurysms comparing open and endovascular repair. *Circulation.* 2016;134(23):1822-1832. [\[CrossRef\]](#)
10. Dang Q, Stadius van Eps RGS, Wever JJ, Veger HTC, Dutch Society of Vascular Surgery, the Steering Committee of the Dutch Surgical Aneurysm Audit, and the Dutch Institute for Clinical Auditing. Nationwide study of the treatment of mycotic abdominal aortic aneurysms comparing open and endovascular repair in the Netherlands. *J Vasc Surg.* 2020;72(2):531-540. [\[CrossRef\]](#)
11. Shirasu T, Kuno T, Yasuhara J, et al. Meta-analysis finds recurrent infection is more common after endovascular than after open repair of infected abdominal aortic aneurysm. *J Vasc Surg.* 2022;75(1):348-355.e10. [\[CrossRef\]](#)