

## Giant right atrial myxoma mimicking a thrombus

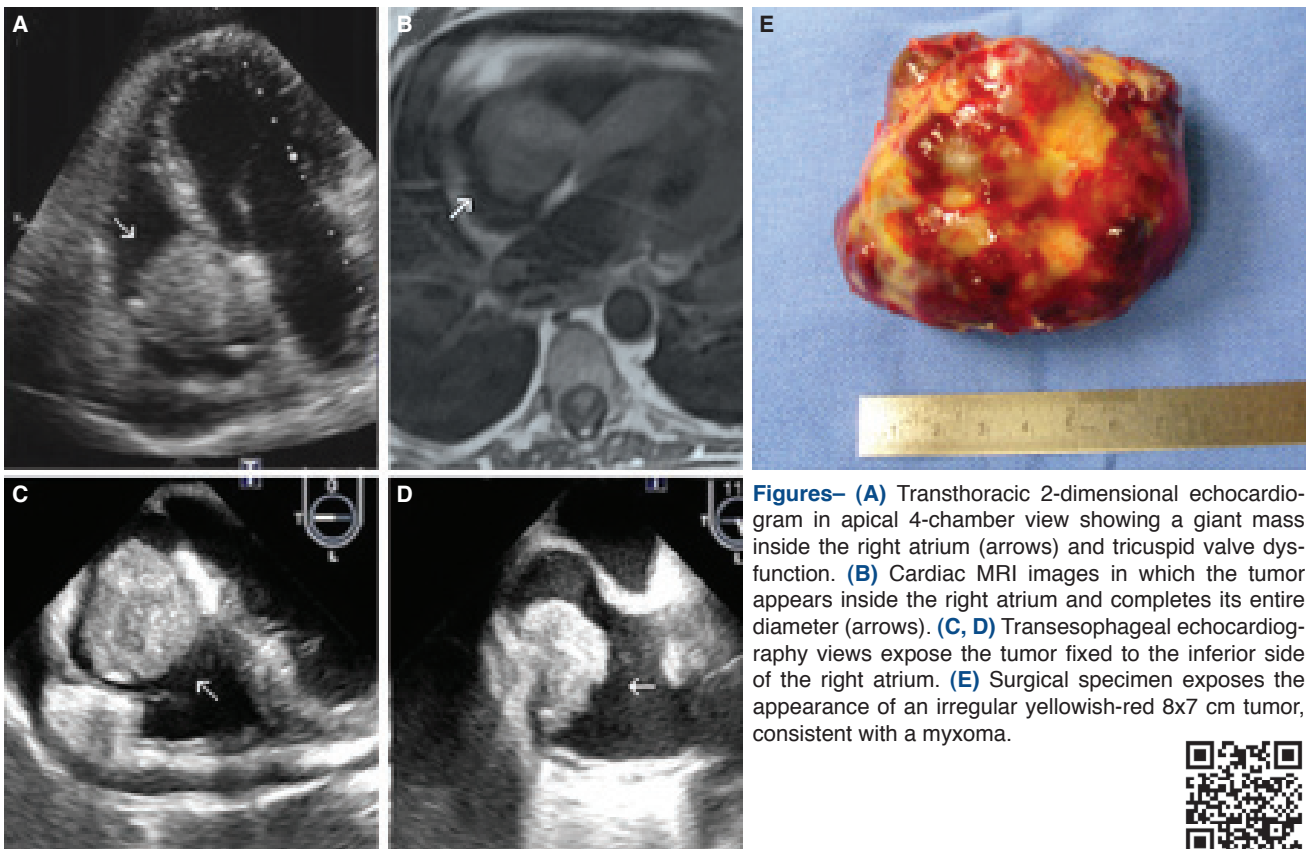
### Trombüsü taklit eden dev sağ atriyal miksoma

María Elena Arnáiz-García  
Jose María González-Santos  
Javier López-Rodríguez  
María José Dalmau-Sorlí

Department of Cardiac Surgery,  
University Hospital of Salamanca,  
Salamanca, Spain

A 45-year-old woman presented with weakness and progressive dyspnea. She had a previous history of severe renal insufficiency treated with hemodialysis and a permanent right jugular central venous catheter as dialysis access. On the physical examination, there were no relevant findings. Electrocardiography showed sinus rhythm. Surprisingly, on chest radiography, a cardiomegaly was detected. Transthoracic echocardiography was achieved and revealed a giant mass located on the right atrium (RA), protruding through the tricuspid valve causing tricuspid regurgitation (Fig. A). Due to the presence of a central venous catheter, the mass was initially misdiagnosed as a thrombus. However, a magnetic resonance (MR) angiography was done and ruled out this possibility (Fig. B). The patient underwent cardiac

surgery. Transesophageal echocardiography intraoperatively showed the mass (Fig. C, D). Median sternotomy was performed and standard cardiopulmonary bypass established. A giant 8x7 cm yellowish-red mass arising from the RA and attached to the inferior vena cava was found. It had a smooth surface with nodules and hemorrhagic areas (Fig. E). The tumor was excised and sent to the Pathology Department and was considered to be a cardiac myxoma. Myxomas are the most common type of benign cardiac tumors. They are usually located on the left atrium, and only exceptional cases grow on the right side of the heart. Diagnosis is difficult because the majority of cases remain asymptomatic. When symptomatic, the clinical presentation is related with embolization or atrioventricular valve dysfunction. Differential diagnosis must be done with malignant tumors or thrombus (especially in the presence of a central venous catheter). Echocardiography and MR play an important role in the diagnosis. Surgical removal is the elective treatment. Recurrences occur when excision of the tumor is incomplete.



**Figures–** (A) Transthoracic 2-dimensional echocardiogram in apical 4-chamber view showing a giant mass inside the right atrium (arrows) and tricuspid valve dysfunction. (B) Cardiac MRI images in which the tumor appears inside the right atrium and completes its entire diameter (arrows). (C, D) Transesophageal echocardiography views expose the tumor fixed to the inferior side of the right atrium. (E) Surgical specimen exposes the appearance of an irregular yellowish-red 8x7 cm tumor, consistent with a myxoma.

