

Herpes Zoster Infection and Myocardial Injury: The Cause or the Bystander?

Herpes Zoster Enfeksiyonu ve Miyokardiyal Hasar: Neden mi Yoksa Seyirci mi?

A 56-year-old gentleman was admitted with atypical chest pain upon palpation and lesions consistent with herpes zoster (Figure 1A) on his chest extending into his armpit. He experienced severe pain even while clothed and sought relief. His medical history included percutaneous coronary intervention of the proximal left anterior descending artery, along with recent diagnoses of hypertension and type 2 diabetes, for which he was not receiving medical therapy. His current medications included acetylsalicylic acid 100 mg once daily and metoprolol 50 mg once daily. He also had a 30-pack-year smoking history.

Laboratory parameters showed a C-reactive protein (CRP) of 23 mg/L (upper reference limit 5 mg/L), hs-Troponin T at 26 ng/L (upper reference limit 14 ng/L) and 30 ng/L at the 1st-hour control, with other tests within normal ranges. His electrocardiogram (ECG) indicated a sinus rhythm of 75 beats per minute with Q waves in the inferior leads. The echocardiogram revealed a normal ejection fraction and mild mitral regurgitation.

Due to pathological Q waves on the electrocardiogram (Figure 1E) and elevated troponin levels, an invasive coronary angiogram was recommended. This revealed multivessel disease (Figure 1B-D). Consequently, coronary artery bypass grafting was planned and performed following medical treatment for herpes zoster.

This case underscores the complexities of evaluating acute chest pain in the emergency department. Here, the incidental finding of myocardial injury led to the discovery of extensive coronary artery disease. Additionally, the active infection may have contributed to the destabilization of coronary plaques. Care must be taken in interpreting hs-Troponin results, even in incidental findings, to avoid attributing them solely to secondary causes.

Informed Consent: Written consent was obtained from the patient.

Peer-review: Internally peer-reviewed.

Author Contributions: Concept – M.M.G., M.R.S.; Design – M.M.G., M.R.S.; Supervision – M.R.S., N.K.; Resource – M.M.G., B.E.; Data Collection and/or Processing – M.M.G., B.E.; Analysis and/or Interpretation – M.R.S., N.K.; Literature Review – M.M.G., M.R.S.; Writing – M.M.G., B.E., M.R.S.; Critical Review – M.R.S., N.K.

Conflict of Interest: The authors have no conflicts of interest to declare.

Funding: The authors declared that this study received no financial support.

CASE IMAGE OLGU GÖRÜNTÜSÜ

Muhammed Mert Göksu 

Berk Erdiç 

Nihan Kayalar 

Mehmet Rasih Sonsöz 

Department of Cardiology, Başakşehir Çam & Sakura City Hospital, İstanbul, Türkiye

Corresponding author:

Muhammed Mert Göksu

✉ dr.mmgoksu@gmail.com

Received: May 10, 2023

Accepted: July 03, 2023

Cite this article as: Göksu MM, Erdiç B, Kayalar N, Sonsöz MR. Herpes Zoster infection and myocardial injury: The cause or the bystander? *Türk Kardiyol Dern Ars.* 2024;52(5):367-368.

DOI:10.5543/tkda.2023.59614



Available online at archivestsc.com.
Content of this journal is licensed under a Creative Commons Attribution – NonCommercial–NoDerivatives 4.0 International License.

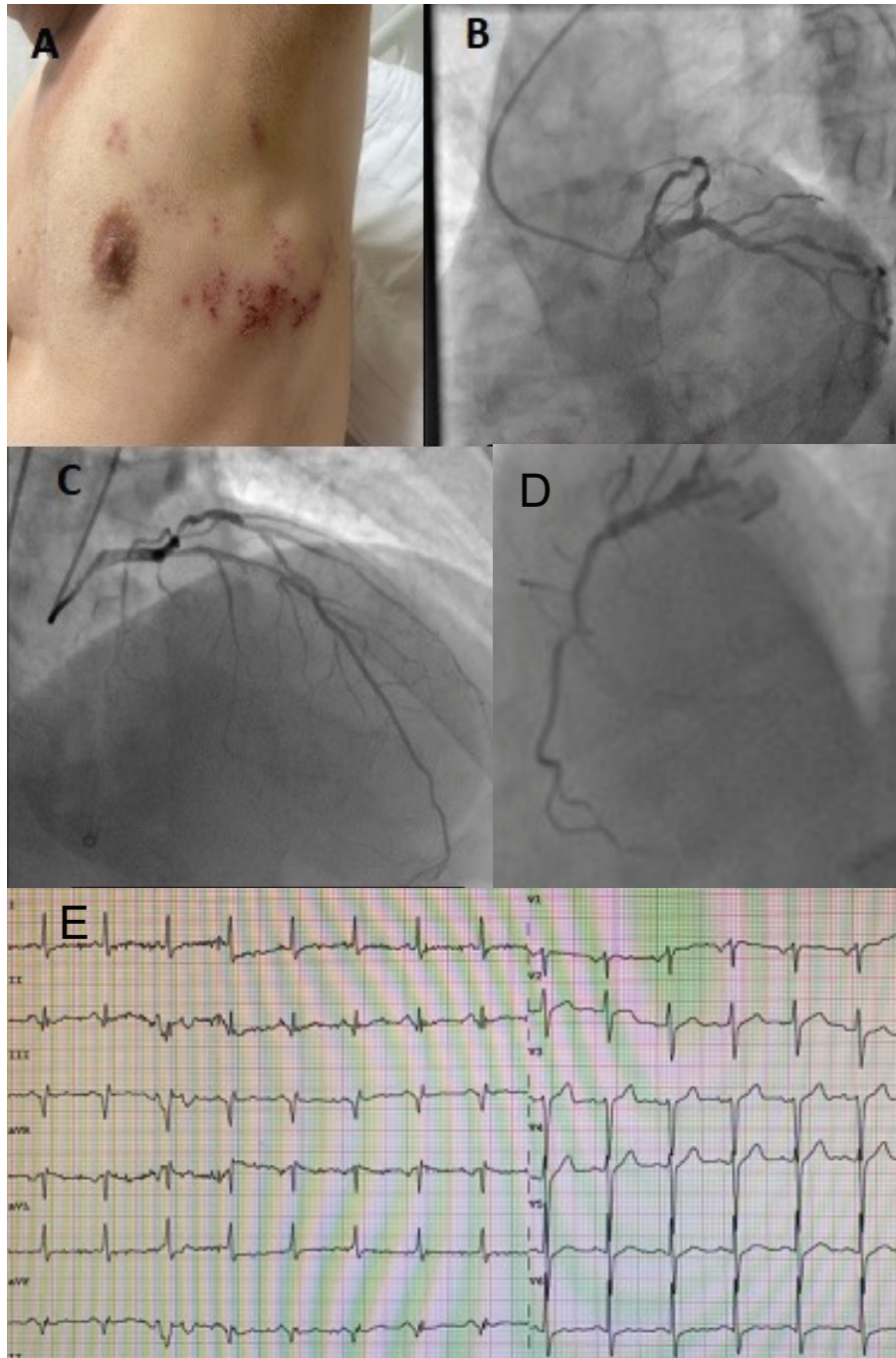


Figure 1. (A) Herpetiform lesions along the left thoracic dermatome. **(B)** Left anterior oblique caudal view showing 80% stenosis in the proximal left anterior descending artery and 50% stenosis in the mid circumflex artery. **(C)** Right anterior oblique cranial view displaying a diffuse lesion in the left anterior descending artery. **(D)** Left anterior oblique view depicting total in-stent occlusion of the middle right coronary artery (arrows). **(E)** The electrocardiogram displaying pathological Q waves in the inferior leads.