

Fragmented QRS complexes are a marker of myocardial fibrosis in hypertensive heart disease

Parçalı QRS kompleksleri hipertansif kalp hastalığında miyokart fibrozunun bir belirticidir

Lütfü Bekar, M.D., Muzaffer Katar, M.D.,# Mücahit Yetim, M.D., Oğuzhan Çelik, M.D.,
Hakan Kilci, M.D.,* Orhan Önalın, M.D.†

Department of Cardiology, Hitit University Çorum Training and Research Hospital, Çorum, Turkey

#Department of Medical Biochemistry, Tokat Government Hospital, Tokat, Turkey

*Department of Cardiology, Şişli Hamidiye Etfal Training and Research Hospital, İstanbul, Turkey

†Department of Cardiology, Karabük University Faculty of Medicine, Karabük, Turkey

ABSTRACT

Objective: Carboxy-terminal propeptide of type 1 procollagen (PICP) is a marker of extracellular collagen synthesis. Fragmented QRS (fQRS) on a 12-lead electrocardiogram (ECG) has been demonstrated as a marker of myocardial fibrosis. The present objective was to investigate the association between serum PICP concentration and presence of fQRS on ECG in hypertensive patients.

Methods: Consecutive patients with previously or newly diagnosed hypertension were included. fQRS was defined as the presence of additional R-wave (R'), or notching of R- or S-waves, or the presence of fragmentation in 2 contiguous ECG leads. Serum PICP levels were measured by ELISA method.

Results: The study group consisted of 90 hypertensive patients (74% females, with a mean age of 54.7±8.5 years). Of these patients, 47 (52.2%) had fQRS on ECG. Age (p=0.121) and gender distribution (p=0.625) were similar in patients with or without fQRS. Receiver operating characteristic curve analysis yielded a strong predictive ability of PICP levels for the presence of fQRS (area under the curve: 0.850; 95% CI: 0.772–0.929; p<0.0001). In multivariate logistic regression analysis, PICP levels were strongly and independently associated with the presence of fQRS (OR: 1.938; 95% CI: 1.398–2.688).

Conclusion: Serum PICP level is a strong and independent predictor of fQRS. Discriminative performance of serum PICP levels for the presence of fQRS is high. The present results are the first to demonstrate that fQRS may indicate myocardial fibrosis in patients with hypertension.

ÖZET

Amaç: Karboksı terminal propeptid tip 1 prokollajen (PICP) hücre dışı kollajen sentezinin bir göstergesidir. On iki kanallı elektrokardiyografide (EKG) tespit edilen parçalı QRS'in (fQRS) miyokart fibrozunun bir belirtici olduğu gösterilmiştir. Bu çalışmada, hipertansiyonlu hastalarda serum PICP düzeyleri ile EKG'de saptanan fQRS arasındaki ilişkiyi araştırmayı amaçladık.

Yöntemler: Yeni veya eski tanılı ardışık hipertansiyonlu hastalar dahil edildi. Parçalanmış QRS birbirini takip eden iki EKG derivasyonunda ilave R dalgası (R') veya R veya S dalgasında çentiklenme veya bölünme varlığı olarak alındı. Serum PICP düzeyleri ELISA yöntemiyle ölçüldü.

Bulgular: Çalışmaya 90 hipertansiyonlu hasta alındı (%74 kadın, ortalama yaş 54.7±8.5 yıl). Bunlardan 47'sinde (%52.2) EKG'de fQRS saptandı. Yaş (p=0.121) ve cinsiyet dağılımı bakımından (p=0.625) fQRS'si olan ve olmayan gruplar birbirine benzerdi. Alıcı işlemci karakteristik eğrisi analizi ile PICP düzeylerinin fQRS varlığı için güçlü bir öngördürücü yeteneğe sahip olduğu görüldü (eğri altında kalan alan=0.850, %95 GA 0.772–0.929, p<0.0001). Çok değişkenli lojistik regresyon analizinde PICP düzeyleri fQRS için güçlü ve bağımsız bir öngördürücü idi (OO [odds oranı] 1.938, %95 GA 1.398–2.688).

Sonuç: Serum PICP düzeyleri fQRS'nin güçlü ve bağımsız bir belirticidir. PICP düzeylerinin fQRS için ayırt edici performansı yüksektir. Biz bu çalışmada fQRS'nin hipertansif hastalarda miyokart fibrozunu yansıtabileceğini gösteren ilk kanıtları sunduk.

Presented as a poster presentation at the 30th Turkish Cardiology Congress with International Participation (23-26 October 2014, Antalya, Turkey).

Received: January 21, 2016 Accepted: May 11, 2016

Correspondence: Dr. Lütfü Bekar. Hitit Üniversitesi Çorum Eğitim ve Araştırma Hastanesi, Kardiyoloji Kliniği, 19030 Çorum, Turkey.

Tel: +90 364 - 223 03 00 e-mail: lbb2006@gmail.com

© 2016 Turkish Society of Cardiology



Hypertension is one of the most common diseases, globally, and is responsible for increased cardiovascular morbidity and mortality.^[1] In hypertensive patients, left ventricular hypertrophy (LVH) is associated with increased risk of cardiovascular events. Myocyte hypertrophy and exaggerated accumulation of collagen occur in interstitial tissue, and lead to non-ischemic myocardial fibrosis.^[2] Research conducted in endomyocardial biopsy (EMB) and postmortem samples has demonstrated that the extent of myocardial collagen is increased in hypertensive patients, compared to normotensive individuals.^[1,2] Therefore, association between myocardial fibrosis and cardiovascular morbidity and mortality has been suggested. EMB is still the diagnostic gold standard for myocardial fibrosis, but is not routinely used, due to its invasive nature.^[3]

Carboxy-terminal propeptide of type 1 procollagen (PICP) is a marker of extracellular collagen synthesis. It has been reported that circulating PICP levels are higher in hypertensive patients than normotensive individuals, and that there is a significant correlation between serum PICP level and the amount of collagen content detected in EMB specimens.^[4]

Fragmented QRS (fQRS) on a 12-lead electrocardiogram (ECG) represents impaired ventricular conduction, and has been shown to be a marker of myocardial fibrosis or scar tissue in various clinical conditions.^[4-8] Accordingly, prevalence of fQRS is relatively low among the healthy general population^[9] and relatively high in patients with myocardial fibrosis or scarring.^[5-8,10] The present study is the first to investigate the association of serum PICP concentration and presence of fQRS on ECG in hypertensive patients.

METHODS

Patients

Adult hypertensive patients who consecutively presented to the outpatient cardiology clinic were included. The following exclusion criteria were applied: (i) history of coronary artery disease, cardiomyopathy, rheumatic heart disease, diabetes mellitus, or systemic or metabolic disease. (ii) echocardiographic findings of reduced left ventricular ejection fraction (<55%), moderate to severe valve disease, wall motion abnormality, or ventricular dilatation, (iii) presence of

liver or bone disease (which may effect serum PICP levels), (iv) use of drugs with anti-fibrotic properties, including angiotensin-converting-enzyme inhibitors, angiotensin-receptor blockers, and aldosterone antagonists, (v) presence of bundle branch block, atrial fibrillation, or paced rhythm. All included patients were in sinus rhythm.

Abbreviations:

BP	Blood pressure
BMI	Body mass index
CI	Confidence interval
ECG	Electrocardiogram
EMB	Endomyocardial biopsy
fQRS	Fragmented QRS
IVST	Septal wall thickness
LVEDD	Left ventricular end-diastolic diameter
LVH	Left ventricular hypertrophy
LVM	Left ventricular mass
LVMI	Left ventricular mass index
OR	Odds ratio
PICP	Carboxy-terminal propeptide of type 1 procollagen
PWT	Posterior wall thickness
R-wave	R'

Body mass index (BMI) was calculated as weight in kilograms divided by square of height in meters. Obesity was defined as a BMI of 30 kg/m² or higher. Estimated glomerular filtration rate (eGFR) was calculated using the Modification of Diet in Renal Disease equation:

$$\text{eGFR (mL/min/1.73 m}^2\text{)} = 186 \times \text{creatinine}^{-1.154} \times \text{age}^{-0.203} \times 0.742 \text{ (if female)} \times 1.212 \text{ (if the patient was black)}$$

Diagnosis of hypertension

Blood pressure (BP) measurements taken at home and the hospital, or data obtained from ambulatory BP monitoring, were used to diagnose hypertension.

Blood pressure measured in the hospital

After ≥10 min of rest, systolic BP and diastolic BP were obtained from the right arms of patients seated and supported at the level of the heart, using a sphygmomanometer (Erka Kallmeyer Medizintechnik GmbH & Co. KG, Bad Tölz, Germany). Patients with BP ≥140/90 mmHg were considered hypertensive. Caffeine intake and tobacco use were restricted for 30 minutes prior to obtaining BP. At least 2 BP readings were recorded during the study period.

Blood pressure measured at home

Patients with BP ≥135/85 mmHg over 3 consecutive days were considered hypertensive.

Ambulatory blood pressure monitoring

Ambulatory BP was also evaluated. Patients with average 24-hour BP of ≥130/80 mmHg, average day-

time BP of $\geq 135/85$ mmHg, and average nighttime BP of $\geq 120/70$ mmHg were considered hypertensive.

Echocardiographic examination

Transthoracic echocardiographic examinations were performed with the subject in the left side supine position, using a Vivid 3 ultrasound machine with a 3.2-MHz transducer (GE Vingmed Ultrasound AS, Horten, Norway). Conventional M-mode and B-mode parameters were measured in accordance with the American Society of Echocardiography guidelines.^[11] Left ventricular end-diastolic (LVEDD) and end-systolic diameters, and posterior (PWT) and septal (IVST) wall thicknesses were measured. Left ventricular mass (LVM) was calculated using the Devereux equation: $LVM = 0.8(1.04[LVEDD + IVST + PWT]^3 - LVEDD^3) + 0.6$.^[12] Left ventricular mass index (LVMI) was calculated by dividing LVM by body surface area. LVH was defined as $LVMI > 115$ g/m² for men and 95 g/m² for women.^[13]

Assessment of fQRS

Resting 12-lead ECG recordings (filter range: 0.15–100 Hz; AC filter: 60 Hz; 25 mm/s; 10 mm/mV) were assessed by 2 independent cardiologists blinded to clinical findings of patients. fQRS (Figure 1) was defined as presence of additional R', or notching of R' or S-wave, or the presence of fragmentation (more than 1 R') in 2 contiguous ECG leads.^[14]

Assessment of PICP levels

Fasting blood samples collected for routine analyses were portioned and stored at -40°C . Serum PICP levels were measured by enzyme-linked immunosorbent assay method using commercially available kits (Cusabio Biotech Co., Ltd., College Park, MD, USA). Lower detection limit of kits was 0.32 ng/mL. Approval was obtained from the institutional ethics committee (project no: 13-KAEK-058).

Statistical analysis

Continuous variables were expressed as mean \pm SD,

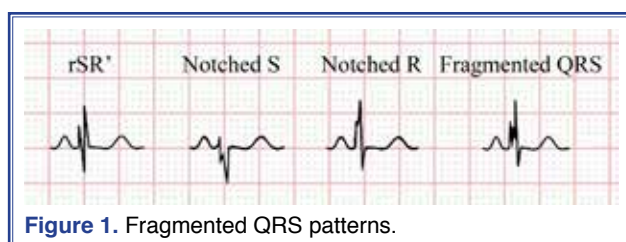


Figure 1. Fragmented QRS patterns.

or median and minimum—maximum, where appropriate. Categorical variables were presented as numbers and percentages. Distributions of continuous variables across the study groups were tested with Kolmogorov–Smirnov test. Continuous data were analyzed with Student's t-test or Mann-Whitney U test, and categorical data were compared using chi-square or Fisher's exact tests. Receiver operating characteristic curve analysis was conducted to assess the discriminative performance of PICP levels for the presence of fQRS on ECG. Areas under the curve with corresponding 95% confidence intervals (CIs) were presented. Sensitivity, specificity, positive predictive value, negative predictive value, and test accuracy were calculated. Multivariate logistic regression analyses (backward stepwise) were conducted to assess the association between PICP level and presence of fQRS. In multivariate regression models, effect size was adjusted for variables with significance levels of ≤ 0.25 in univariate analysis. To avoid multicollinearity, the most significant clinical variables were entered in regression models. Adjusted odds ratios (ORs), and 95% CIs were presented. A 2-tailed p value of < 0.05 was considered statistically significant. All statistical analyses were performed using SPSS software (version 21.0; SPSS Inc., Chicago, IL, USA).

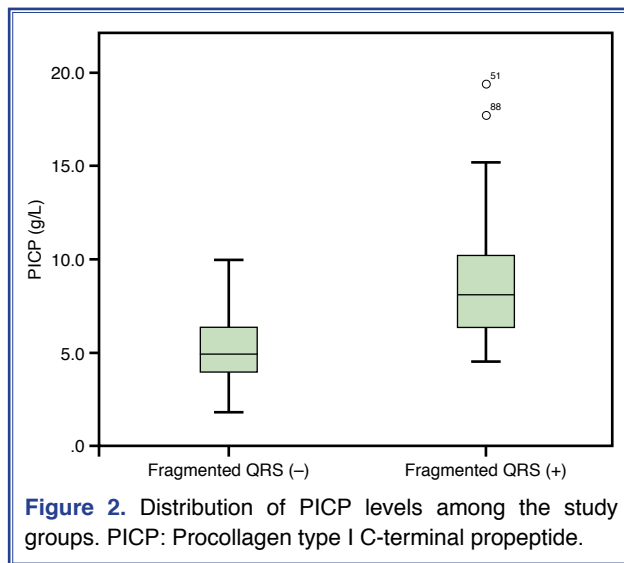
RESULTS

The study group included 90 hypertensive patients (74% females, with a mean age of 54.7 ± 8.5 years). Of these patients, 47 (52.2%) had fQRS on ECG. Baseline characteristics of patients with or without fQRS are presented in Table 1. Age ($p=0.121$) and gender distribution ($p=0.625$) were similar in patients with or without fQRS. Height ($p=0.017$), BMI ($p=0.009$), prevalence of obesity ($p=0.045$), total cholesterol level ($p=0.032$), IVST ($p=0.005$), PWT ($p=0.010$), LAD ($p=0.009$), LVM ($p=0.002$), LVMI ($p=0.002$), prevalence of LVH ($p=0.002$), and PICP levels (median: 8.13; min—max: 4.6–19.4 vs median: 4.96; min—max: 1.8–10.0 g/L; $p<0.0001$) were significantly higher in patients with fQRS than in patients without. Distributions of PICP levels among the groups are presented in Figure 2. Patients with or without fQRS were similar, with respect to other baseline characteristics, as shown in Table 1. Receiver operating characteristic curve analysis (Figure 3) yielded a strong predictive ability of PICP levels for

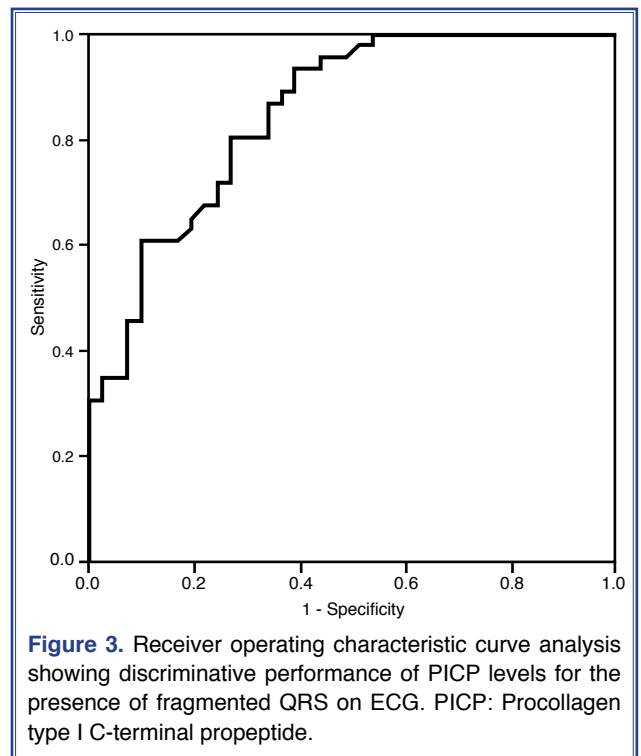
Table 1. Baseline characteristics of the study groups

	Fragmented QRS (+) (n=47)	Fragmented QRS (-) (n=43)	<i>p</i>
Age (year)	53.3±9.31	56.1±7.42	0.121
Female, n (%)	36 (76.6)	31 (72.1)	0.625
Weight (kg)	79.5±13.19	76.0±12.63	0.201
Height (cm)	159.7±9.06	163.9±6.91	0.017
Body surface area (m ²)	1.87±0.18	1.85±0.17	0.614
Body mass index (g/m ²)	31.2±5.16	28.4±4.98	0.009
Hyperlipidemia (%)	5 (10.6)	11 (25.6)	0.064
Smoker, n (%)	6 (12.8)	6 (14.0)	0.869
Obesity, n (%)	24 (51.1)	13 (30.2)	0.045
Drugs, n (%)			
Acetylsalicylic acid	12 (25.5)	8 (18.6)	0.430
Diuretic	5 (10.6)	9 (20.9)	0.178
Calcium channel blocker	16 (34.0)	13 (30.2)	0.699
Beta blocker	14 (29.8)	11 (25.6)	0.656
Other	0 (0)	2 (4.7)	0.225
Systolic blood pressure (mmHg)	148.9±20.45	144.3±15.69	0.239
Diastolic blood pressure (mmHg)	85.7±11.38	84.7±12.03	0.679
Mean blood pressure (mmHg)	106.8±13.35	104.6±11.91	0.410
Pulse pressure (mmHg)	60.0 (30–100)	60.0 (34–90)	0.160
Glucose (mg/dL)	96.4±11.53	95.7±10.29	0.782
Creatinine (mg/dL)	0.88±0.23	0.80±0.17	0.088
Hemoglobin (g/dL)	13.7±1.10	13.7±1.22	0.855
Total cholesterol (mg/dL)	192.2±32.71	210.6±44.68	0.032
Triglyceride (mg/dL)	163.9±81.38	169.8±100.27	0.770
Low-density lipoprotein (mg/dL)	129.8±32.29	142.3±37.95	0.100
High-density lipoprotein (mg/dL)	41.0 (27–68)	43.0 (25–74)	0.382
Estimated glomerular filtration rate (mL/min/1.73 m ²)	80.4 (40–144)	86.3 (59–174)	0.134
Left ventricular end-diastolic diameter (mm)	45.77±4.78	44.6±4.37	0.236
Left ventricular end-systolic diameter (mm)	29.1±4.39	29.4±4.35	0.763
Interventricular septal thickness (mm)	12.4±2.03	11.2±1.95	0.005
Posterior wall thickness (mm)	11.8±1.79	10.7±1.93	0.010
Left ventricular ejection fraction (%)	65.3±5.63	66.6±4.86	0.260
Fractional shortening (%)	35.5 (29–46)	35.9 (29–43)	0.417
Left atrial diameter (cm)	36.0±5.39	33.2±4.44	0.009
Left ventricular mass (g)	208.7±52.15	175.0±46.59	0.002
Left ventricular mass index (g/m ²)	117.1 (64–169)	92.2 (50–184)	0.002
Relative wall thickness	0.52±0.11	0.49±0.11	0.122
Left ventricular hypertrophy, n (%)	34 (72.3)	17 (39.5)	0.002
Procollagen type I C-terminal propeptide (g/L)	8.13 (4.6–19.4)	4.96 (1.8–10)	<0.0001

Continuous variables are presented as mean±standard deviation or median and minimum-maximum, where appropriate. Categorical variables are presented as number and percentages.



the presence of fQRS (area under the curve: 0.850; 95% CI: 0.772–0.929; $p < 0.0001$). With a cutoff value of 6.17 g/L, PICP levels had sensitivity, specificity, positive predictive value, negative predictive value, and accuracy of 80.4%, 73.2%, 77.1%, 76.9%, and 77.0%, respectively, for the presence of fQRS. In multivariate logistic regression analysis, PICP level, entered either as a continuous variable (OR: 1.938; 95% CI: 1.398–2.688) or as a dichotomous variable (PICP ≥ 6.17 g/L; OR: 11.782; 95% CI: 3.848–36.076), was strongly and independently associated with the presence of fQRS (Table 2). The association was still evident, even after adjustment for LVMI.



DISCUSSION

It is well-known that LVH is a more important risk factor for hypertensive patients than age, serum cholesterol level, BP level, or presence of coronary artery disease. LVH is associated with increased cardiovascular morbidity and mortality,^[15] and is a strong, independent risk factor for cardiac failure, coronary artery

Table 2. Multivariate analysis for the presence of fragmented QRS on ECG

	β	Wald	p	Odds Ratio	95% CI	
					Lower	Upper
Model 1						
Body mass index	0.119	3.994	0.046	1.126	1.002	1.266
PICP levels	0.662	15.752	<0.0001	1.938	1.398	2.688
Method: Backward Stepwise (Wald). Variable(s) entered on step 1: Age, body mass index, diuretic use, pulse pressure, total cholesterol levels, estimated glomerular filtration rate, left atrial diameter, left ventricular mass index and PICP levels. PICP: Indicates procollagen type I C-terminal propeptide; β : Regression coefficient; CI: Confidence interval.						
Model 2						
Body mass index	0.149	6.481	0.011	1.161	1.035	1.302
PICP ≥ 6.17 g/L	2.467	18.664	<0.0001	11.782	3.848	36.076

Method: Backward Stepwise (Wald). Variable(s) entered on step 1: Age, body mass index, diuretic use, pulse pressure, total cholesterol levels, estimated glomerular filtration rate, left atrial diameter, left ventricular mass index and PICP levels as a dichotomous variable. PICP: Indicates procollagen type I C-terminal propeptide; β : Regression coefficient; CI: Confidence interval.

disease, arrhythmia, and stroke.^[8] Myocyte hypertrophy and excessive accumulation of collagen occur in LVH, leading to disproportionate increase of fibrous tissue in the myocardium.^[2] LVH may also occur in athletic heart syndrome without myocardial fibrosis, due to proportional increase of LVM.^[16]

Myocardial fibrosis is a crucial factor for LVH in hypertensive patients, and is associated with adverse cardiac events. Therefore, detection of collagen accumulation can aid in the prediction of clinical course and treatment planning.^[17] EMB is still the diagnostic gold standard for the diagnosis of myocardial fibrosis, but is not routinely used due to its invasive nature. Myocardial fibrosis can be detected by cardiac magnetic resonance imaging and scintigraphic methods, in addition to histopathological evaluation.^[18] Serum PICP is a biochemical marker of extracellular collagen type 1 synthesis, and has higher sensitivity and specificity in the determination of myocardial fibrosis. A significant correlation has been shown between serum PICP levels and the amount of collagen detected in histopathological examination of tissue biopsies.^[2,19] fQRS is easily detected on a routine 12-lead ECG, and indicates altered ventricular conduction, which is related to myocardial fibrosis.^[14,20] A strong association between fQRS detected on ECG and myocardial fibrosis, as assessed by gadolinium-enhanced cardiac magnetic resonance imaging, has been demonstrated in several studies.^[5,7,8] However, the potential association of fQRS with myocardial fibrosis in hypertensive patients had yet to be investigated. In the present study, hypertensive patients with fQRS had significantly higher left ventricular wall thickness, LVM, LVMI, prevalence of LVH, and serum PICP levels, compared to hypertensive patients without fQRS. Moreover, there was a strong and independent association between serum PICP levels and presence of fQRS on ECG. The present results suggested that fQRS on ECG indicated underlying myocardial fibrosis in patients with hypertension.

Myocardial fibrosis may prolong myocardial conduction time, which may disrupt QRS morphology and lead to development of fQRS. Hypertensive patients have abnormal left ventricular geometry and higher incidence of LVH.^[21,22] It has also been suggested that hypertensive patients with fQRS have higher incidence of complex ventricular arrhythmias. This may be the result of ectopic impulses and re-entry circuits,

caused by myocardial fibrosis.^[18] Similarly, the presence of fQRS has been linked to higher risk of atrial arrhythmia.^[23,24]

Procollagens are produced by fibroblasts and secreted to the extracellular space. Carboxy terminal propeptide terminals of procollagens are removed by specific endopeptidases during collagen synthesis, released into the blood, and cleared by the liver.^[2] Serum PICP is a marker of myocardial fibrosis, and has better correlation with myocardial collagen content.^[2] It was presently found that serum PICP levels were increased in hypertensive patients with fQRS. This increase may be related to increased synthesis of myocardial collagen and myocardial fibrosis, leading to prolonged ventricular conduction time in hypertensive patients with fQRS. Myocardial fibrosis is a well-known predisposing factor for left ventricular dysfunction, arrhythmia, and sudden cardiac death, and is related to increased cardiovascular risk.^[25,26] Early diagnosis of myocardial fibrosis can be effective for both risk classification and selection of drugs used in the treatment of cardiovascular disease.

Limitations

Several limitations may have affected the present results, primarily small sample size. Myocardial fibrosis was not investigated with advanced imaging modalities or histopathological examination. Although patients on angiotensin-converting-enzyme inhibitors, angiotensin-receptor blockers, or aldosterone antagonists were excluded, the possible effects of other antihypertensive medications on myocardial fibrosis could not entirely be accounted for.

Conclusions

Serum PICP level is a strong and independent predictor of fQRS; discriminative performance of serum PICP level for the presence of fQRS on ECG was high. The first evidence that fQRS may indicate myocardial fibrosis in hypertensive patients was provided in the present study. Our data suggests that fQRS may be a useful tool in the assessment of myocardial fibrosis in patients with hypertension. fQRS is a simple, inexpensive, and widely available tool, which may have additional benefits in the risk assessment of patients with hypertension.

Conflict-of-interest issues regarding the authorship or article: None declared

REFERENCES

1. Rossi MA. Pathologic fibrosis and connective tissue matrix in left ventricular hypertrophy due to chronic arterial hypertension in humans. *J Hypertens* 1998;16:1031–41. [Crossref](#)
2. Querejeta R, Varo N, Lopez B, Larman M, Artinano E, Etayo JC, et al. Serum carboxy-terminal propeptide of procollagen type I is a marker of myocardial fibrosis in hypertensive heart disease. *Circulation* 2000;101:1729–35. [Crossref](#)
3. Cuspidi C, Ciulla M, Zanchetti A. Hypertensive myocardial fibrosis. *Nephrol Dial Transplant* 2006;21:20–3. [Crossref](#)
4. Take Y, Morita H. Fragmented QRS: What Is The Meaning? *Indian Pacing Electrophysiol J* 2012;12:213–25. [Crossref](#)
5. Basaran Y, Tigen K, Karaahmet T, Isiklar I, Cevik C, Gurel E, et al. Fragmented QRS complexes are associated with cardiac fibrosis and significant intraventricular systolic dyssynchrony in nonischemic dilated cardiomyopathy patients with a narrow QRS interval. *Echocardiography* 2011;28:62–8. [Crossref](#)
6. Das MK, Suradi H, Maskoun W, Michael MA, Shen C, Peng J, et al. Fragmented wide QRS on a 12-lead ECG: a sign of myocardial scar and poor prognosis. *Circ Arrhythm Electrophysiol* 2008;1:258–68. [Crossref](#)
7. Park SJ, On YK, Kim JS, Park SW, Yang JH, Jun TG, et al. Relation of fragmented QRS complex to right ventricular fibrosis detected by late gadolinium enhancement cardiac magnetic resonance in adults with repaired tetralogy of fallot. *Am J Cardiol* 2012;109:110–5. [Crossref](#)
8. Homsy M, Alsayed L, Safadi B, Mahenthiran J, Das MK. Fragmented QRS complexes on 12-lead ECG: a marker of cardiac sarcoidosis as detected by gadolinium cardiac magnetic resonance imaging. *Ann Noninvasive Electrocardiol* 2009;14:319–26. [Crossref](#)
9. Terho HK, Tikkanen JT, Juntila JM, Anttonen O, Kenttä TV, Aro AL, et al. Prevalence and prognostic significance of fragmented QRS complex in middle-aged subjects with and without clinical or electrocardiographic evidence of cardiac disease. *Am J Cardiol* 2014;114:141–7. [Crossref](#)
10. Fares H, Heist K, Lavie CJ, Kumbala D, Ventura H, Meadows R, et al. Fragmented QRS complexes—a novel but underutilized electrocardiographic marker of heart disease. *Crit Pathw Cardiol* 2013;12:181–3. [Crossref](#)
11. Lang RM, Bierig M, Devereux RB, Flachskampf FA, Foster E, Pellikka PA, et al. Recommendations for chamber quantification: a report from the American Society of Echocardiography's Guidelines and Standards Committee and the Chamber Quantification Writing Group, developed in conjunction with the European Association of Echocardiography, a branch of the European Society of Cardiology. *J Am Soc Echocardiogr* 2005;18:1440–63. [Crossref](#)
12. Devereux RB, Alonso DR, Lutas EM, Gottlieb GJ, Campo E, Sachs I, et al. Echocardiographic assessment of left ventricular hypertrophy: comparison to necropsy findings. *Am J Cardiol* 1986;57:450–8. [Crossref](#)
13. Mancia G, Fagard R, Narkiewicz K, Redón J, Zanchetti A, Böhm M, et al. 2013 ESH/ESC Guidelines for the management of arterial hypertension: the Task Force for the management of arterial hypertension of the European Society of Hypertension (ESH) and of the European Society of Cardiology (ESC). *J Hypertens* 2013;31:1281–357. [Crossref](#)
14. Das MK, Zipes DP. Fragmented QRS: a predictor of mortality and sudden cardiac death. *Heart Rhythm* 2009;6(3 Suppl):8–14. [Crossref](#)
15. Kannel WB. Prevalence and natural history of electrocardiographic left ventricular hypertrophy. *Am J Med* 1983;75(3A):4–11. [Crossref](#)
16. Levy D, Larson MG, Vasan RS, Kannel WB, Ho KK. The progression from hypertension to congestive heart failure. *JAMA* 1996;275:1557–62. [Crossref](#)
17. Gonzalez A, Lopez B, Díez J. Myocardial fibrosis in arterial hypertension. *European Heart J Supplements* 2002;4(Suppl D):18–22. [Crossref](#)
18. Jellis C, Martin J, Narula J, Marwick TH. Assessment of non-ischemic myocardial fibrosis. *J Am Coll Cardiol* 2010;56:89–97. [Crossref](#)
19. Díez J, Panizo A, Gil MJ, Monreal I, Hernández M, Pardo Mindán J. Serum markers of collagen type I metabolism in spontaneously hypertensive rats: relation to myocardial fibrosis. *Circulation* 1996;93:1026–32. [Crossref](#)
20. Morita H, Kusano KF, Miura D, Nagase S, Nakamura K, Morita ST, et al. Fragmented QRS as a marker of conduction abnormality and a predictor of prognosis of Brugada syndrome. *Circulation* 2008;118:1697–704. [Crossref](#)
21. Zhang B, Zhen Y, Shen D, Zhang G. Significance of fragmented QRS complexes for identifying left ventricular hypertrophy in patients with hypertension. *Ann Noninvasive Electrocardiol* 2015;20:175–80. [Crossref](#)
22. Bekar L, Celebi S. Fragmented QRS and Left Ventricular Geometry in Hypertensive Patients. *Kosuyolu Kalp Derg* 2013;16:93–8. [Crossref](#)
23. Temiz A, Gazi E, Güngör O, Altun B, Barutcu A, Bekler A, et al. Fragmented QRS and prediction of paroxysmal atrial fibrillation episodes. *Pak J Med Sci* 2014;30:862–7. [Crossref](#)
24. Bekar L. Fragmented QRS and atrial arrhythmias in hypertensive patients. 10th Mediterranean Meeting on Hypertension and Atherosclerosis, 2013. p. 6.
25. Kannel WB. Left ventricular hypertrophy as a risk factor in arterial hypertension. *Eur Heart J* 1992;13 Suppl D:82–8.
26. Messerli FH, Soria F. Hypertension, left ventricular hypertrophy, ventricular ectopy, and sudden death. *Am J Med* 1992;93:21–6. [Crossref](#)

Keywords: Fragmented QRS complexes; hypertension; myocardial fibrosis; procollagen.

Anahtar sözcükler: Fragmente QRS kompleksi; hipertansiyon; miyokart fibrozisi; prokollajen.