




Heart bowtie

Kalp içinde papyon

 Maryam Shojaeifard¹

 Leili Pourafkari²

 Nader Nader³

¹Rajaie Cardiovascular, Medical, and Research Center, Iran University of Medical Sciences, Tehran, Iran

²Catholic Health System, University at Buffalo, Buffalo, New York

³Department of Anesthesiology, University at Buffalo, Buffalo, New York

A 79-year-old woman presented for the pre-operative evaluation of an elective cholecystectomy; medical history was significant for hypertension and chronic kidney disease. The patient reported chronic shortness of breath on

exertion but no fever, recent weight loss, or chest pain. Transthoracic echocardiography showed a normal left ventricular ejection fraction and a bowtie-shaped echo density with well-defined borders located over the posterior mitral annulus and associated with moderate mitral valve regurgitation without causing mitral stenosis (Fig. 1A, Video 1 and 2*). A chest X-ray showed cardiomegaly with a lobular density over the cardiac silhouette (Fig. 1B). Further laboratory analyses showed normal white blood cell count and C-reactive protein values and an erythrocyte sedimentation rate of 22 mm/h.

Mitral annular calcification is a process that predominantly involves calcium deposits on the fibrous skeletal

ton of the posterior mitral annulus. Although the condition was formerly thought to be due to age-related degeneration, it is now considered an active process of injury and inflammation.

Clinical and echocardiographic features help distinguish this condition from a tumor, cyst, or abscess. While the clinical context is crucial in making an accurate diagnosis, cardiac magnetic resonance imaging and computerized tomography scan are valuable tools in diagnosing uncertain cases. Myxomas are generally mobile and pedunculated, and lack significant calcification. An abscess generally manifests as an echogenic homogenous mass in the myocardium without any remarkable calcification. Hydatid cysts of the heart are uncommon even in endemic regions and typically have a cystic appearance.

Though generally benign and warranting conservative management, the condition is occasionally associated with significant valvular dysfunction, conduction disturbances, and embolic events; however, it is associated infrequently with infective endocarditis.

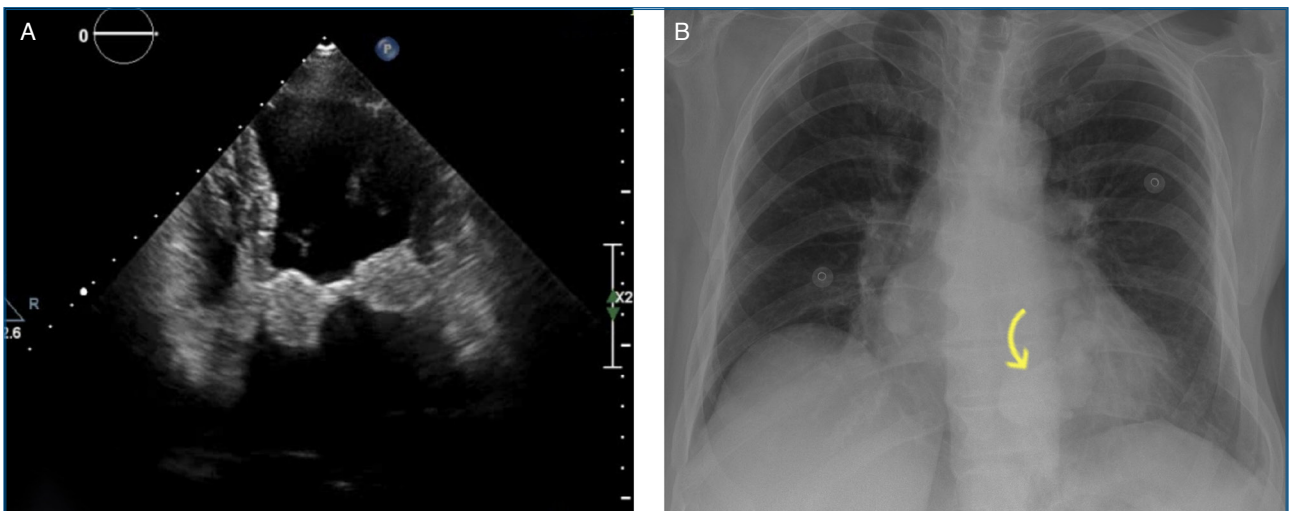


Figure 1. (A*) Four-chamber view of transthoracic echocardiography showing the echo-dense, bowtie-shaped mass attached to the mitral valve annulus. **(B)** Chest X-ray. Please note the lobulated density at the position of the mitral valve over the cardiac silhouette (marked by an arrow).

*Supplementary video files associated with this presentation can be found in the online version of the journal.