

CASE REPORT

Stent and implantable cardioverter defibrillator implantation in medically resistant vasospastic angina patient

İlacı dirençli vazospastik anginalı hastada stent ve implante edilebilir defibrilatör tedavisi

Nil Özyüncü, M.D., Hüseyin Göksülük, M.D., VeySEL Kutay Vurgun, M.D.,
Onur Yıldırım, M.D., Türkan Seda Tan Kürklü, M.D.

Department of Cardiology, Ankara University Faculty of Medicine, Ankara, Turkey

Summary– Vasospastic angina, also known as Prinzmetal's angina, is thought to occur due to vascular hyper-reactivity to various stimuli. Response to medical therapy is usually good; however, 1 out of 5 patients has resistant symptoms. Rarely, potentially lethal arrhythmias can occur due to vasospasm, and those patients are reported to have a poorer prognosis. Presently described is a case of resistant vasospastic angina with persistent symptoms under calcium channel blocker and nitrate treatment. The patient presented with hemodynamically unstable rapid-rate ventricular tachycardia, which was quite resistant to recurrent cardioversion. She was treated with stent implantation for definite vasospastic segments of the coronaries, in combination with medical therapy. An implantable cardioverter defibrillator was also implanted for secondary prevention of ventricular arrhythmia, as vasospasm was considered to be a diffuse disease without a certain definitive treatment.

Vasospastic angina is caused by a transient coronary artery spasm that may be due to various stimuli. Most commonly, it occurs in non-critical atherosclerotic lesions, leading to typical chest pain and ischemic changes on electrocardiogram (ECG), and is characteristically resolved with nitrates. Long-acting calcium channel blockers and nitrates are the mainstays of treatment; however, there are medically refractory cases. Rarely, this functional abnormality of the coronary arteries can lead to sudden cardiac death from severe, life-threatening ventricular arrhythmias, and it accounts for 5% of aborted sudden cardiac death cases.^[1] Described herein is a case of medically refractory vasospastic angina presenting with rapid-

Özet– Prinzmetal angina olarak da bilinen vazospastik angina, birçok faktörün tetikleyebileceği bir damar aşırı duyarlılığı olarak düşünülmektedir. Tıbbi tedaviye yanıt sıklıkla iyidir, ancak her beş hastadan birinde dirençli semptomlar görülmektedir. Nadiren vazospazma bağlı ölümcül aritmiler görülebilmektedir ve bu hastalarda prognoz daha kötüdür. Burada, kalsiyum kanal blokleri ve nitrat tedavisine rağmen semptomları devam eden dirençli bir vazospastik anginalı olguyu sunduk. Hasta, hemodinamik bozukluğa yol açan ve tekrarlayan kardiyoversiyonlara dirençli yüksek hızlı ventriküler taşikardi ile başvurdu. Tıbbi tedavisine ek olarak, koronerlerdeki belirgin vazospastik segmentlere stent yerleştirilerek tedavi edildi. Ayrıca, vazospazm kesin bir tedavisi olmayan yaygın bir vasküler hastalık olduğundan, ventrikül aritmilerine karşı ikincil korunma amaçlı implante edilebilir defibrilatör yerleştirildi.

rate ventricular tachycardia that was clinically managed using a stent and the implantation of an implantable cardioverter-defibrillator (ICD).

Abbreviations:

ECG	Electrocardiogram
ICD	Implantable cardioverter-defibrillator
LAD	Left anterior descending artery
RCA	Right coronary artery

CASE REPORT

A 48-year-old woman presented at the emergency department with crushing chest pain and dyspnea. Upon admission, her ECG revealed ST segment elevation in the anterior leads (Figure 1). She only had hypertension as a cardiovascular risk factor. She had undergone

Received: December 02, 2016 Accepted: February 28, 2017

Correspondence: Dr. Nil Özyüncü. Ankara Üniversitesi Tıp Fakültesi, Kardiyoloji Anabilim Dalı, Ankara, Turkey.

Tel: +90 312 - 508 25 23 e-mail: nilozyuncu@yahoo.com

© 2017 Turkish Society of Cardiology



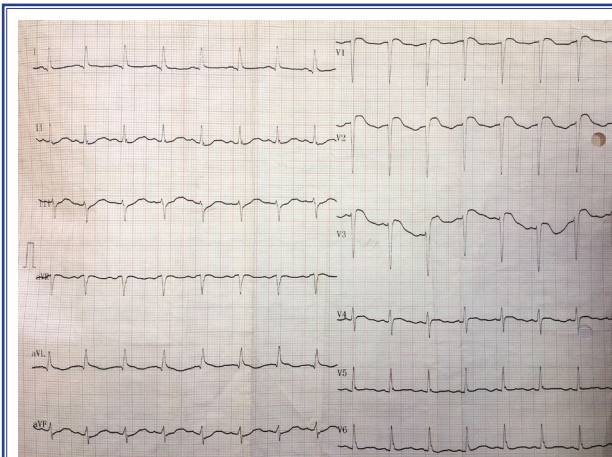


Figure 1. Electrocardiography performed on admission to the emergency department with typical chest pain. Anterior precordial leads showed ST segment elevation with reciprocal ST segment depression in inferior leads.

coronary angiography a month earlier as a result of resting angina occurring at night for a 1-month period. The angiography revealed multi-vessel coronary vasospasm in mildly atherosclerotic coronary arteries. Amlodipine 10 mg and isosorbide mononitrate 50 mg was prescribed. The angina attacks were reduced with the medication, but recently the angina had become quite severe. Just after monitorization, the patient became hemodynamically unstable and rapid-rate, monomorphic, sustained ventricular tachycardia was seen on the monitor (no ECG available). Immediate electrical cardioversion was performed, but the tachycardia was

resistant, despite 2 consecutive shocks. Cardiopulmonary resuscitation was performed with amiodarone bolus and repeated cardioversion; however, normal sinus rhythm could be achieved only after the fifth shock following a lidocaine bolus.

The patient was rapidly admitted to the catheterization laboratory for coronary angiography. There was a diffuse spasm leading to 80% stenosis in the proximal left anterior descending artery (LAD), which was resolved with an intracoronary nitroglycerin injection (Figure 2). Non-obstructive plaques were evident in the proximal LAD. On the right coronary catheterization, a focal spasm in the right coronary artery (RCA) ostium was apparent, and also relieved with nitroglycerin (Figure 3). Reports from the previous coronary angiography performed a month earlier also indicated the spasms, in the same locations. The spasms were refractory to the medical treatment of a long-acting calcium channel blocker and nitrate, and had led to rapid-rate, sustained ventricular tachycardia. Stent implantation for the spasmodic segments was recommended. For the proximal LAD, a 3x18 mm sirolimus-eluting stent was used, and a 2.75x13 mm sirolimus-eluting stent was implanted successfully in the RCA ostium (Figure 4).

Laboratory values were all within normal limits, with the exceptions of cardiac troponin, peaking at 0.46 ng/mL (normal range: <0.06 ng/mL) and creatine kinase-MB, peaking at 20 ng/mL (normal range: <6.3

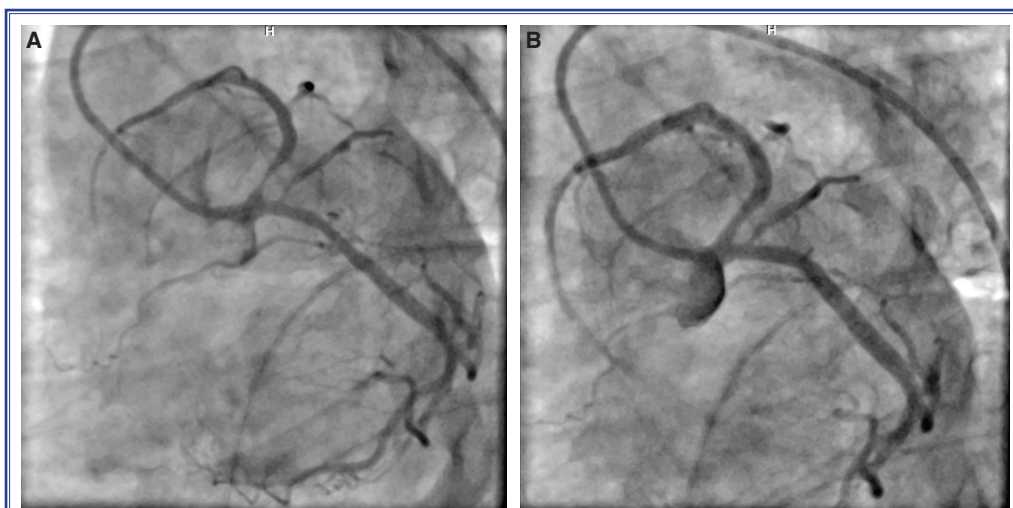


Figure 2. (A) Diffuse coronary vasospasm leading to 80% narrowing of the proximal left anterior descending artery (LAD), seen at left caudal angulation. Spasm at the proximal part of the obtus major branch of the circumflex artery was also observed. (B) Spasm was resolved after intracoronary nitroglycerin injection, but non-obstructive atherosclerotic plaques at proximal LAD could be seen.

ng/mL). There were no segmental wall motion abnormalities seen on echocardiography. During discharge, verapamil 240 mg/d, isosorbide mononitrate 50 mg/d and atorvastatin 20 mg/d were prescribed for the patient. Holter monitoring revealed no rhythm abnormalities, and she described no chest pain at follow-up. A joint meeting was held with the electrophysiology team about her resistant ventricular tachycardia leading to hemodynamic instability on admission. Since the coronary vasospasm reflects an endothelial hyper-reactivity involving whole coronary arteries, multi-vessel vasospasm in our patient under medical therapy

was thought to be a possible risk for recurrence. Because of coronary vasospasm was not a completely reversible cause of ventricular tachyarrhythmias, ICD implantation for secondary prevention was performed successfully in the second month. The patient was still in follow-up at the fourth month, and was free of chest pain and arrhythmias.

DISCUSSION

The exact pathogenesis of vasospastic angina is still not well known; however, vascular smooth muscle

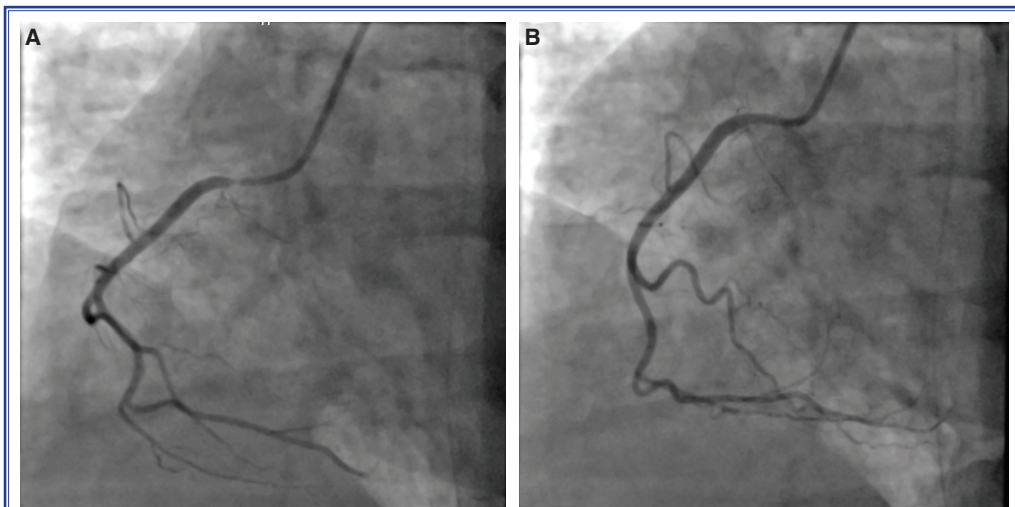


Figure 3. (A) Severe spasm seen at the right coronary artery ostium in right oblique angulation. (B) Spasm was relieved with intracoronary nitroglycerin injection, but non-obstructive atherosclerotic plaques at the proximal segment of the artery were present.

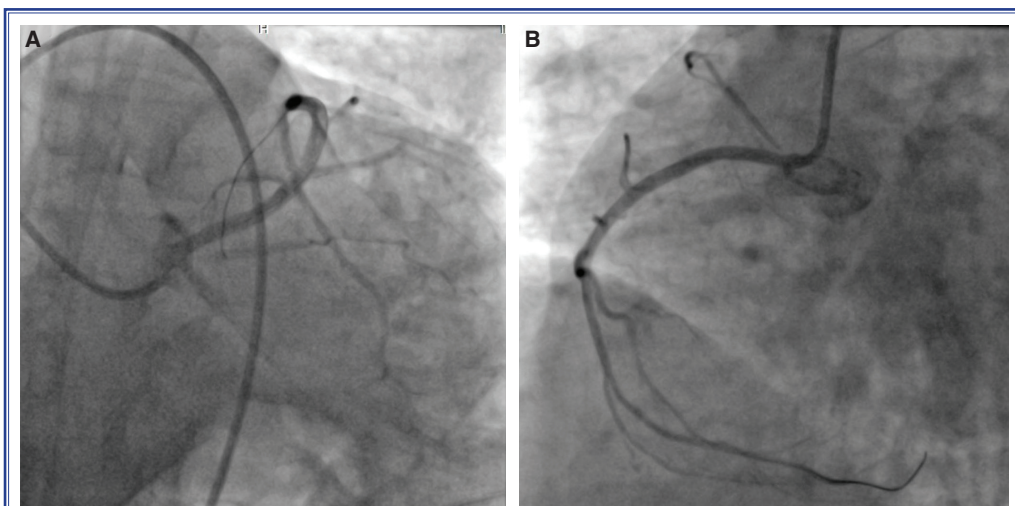


Figure 4. (A) Proximal part of the left anterior descending artery after stent implantation (view at left caudal angulation). (B) Right coronary artery after proximal stent implantation, including the ostium (right oblique view).

hyper-reactivity and endothelial dysfunction are thought to be the key inciting events. Typical angina not related to exertion usually has a diurnal variation, peaking in the early morning with increased sympathetic tonus. Medical treatment with long-acting calcium channel blockers and nitrates typically offers relief of symptoms and responders usually have a good prognosis. However, about 20% of patients with vasospastic angina continue to have symptoms despite medical treatment.^[2] Coronary artery spasm could induce serious ventricular arrhythmias and subsequent cardiac arrest. The prevalence of vasospastic angina in survivors of sudden cardiac death and without significant coronary stenosis was reported to be 6% in Japan.^[3] Although far-east Asia is the most frequent site for vasospastic angina, it should be considered that vasospastic angina is not a very rare cause of out-of-hospital cardiac arrest.

Our patient had the diagnosis of vasospastic angina in her previous catheterization, but was still having episodes of angina afterwards while under treatment with amlodipine and a nitrate. Current guidelines do not offer an exact treatment model for patients with resistant symptoms. Increasing the dose of long-acting calcium channel blockers (dihydropyridine, non-dihydropyridine, or combination) and nitrates is the mainstay of treatment. In the literature, there are case reports and single-center reports indicating that stent implantation can be a successful alternative for drug-resistant patients. Gasparone et al.,^[4] reported that coronary stenting was successful for symptom control at 6-month follow-up of 6 of 9 drug-resistant vasospastic angina patients. In a single-center trial of 21 drug-resistant vasospastic patients, 1 patient had recurrent vasospastic symptoms, 3 patients needed intervention due to stent restenosis, and the remainder were symptom-free for 1 to 8 years of follow-up.^[5] It should be kept in mind that coronary vasospasm is a diffuse disease and may develop in locations other than the stent site. Collectively, it is stated that stent implantation for vasospastic angina patients with significant stenosis should be considered in addition to medical treatment.^[6] However, for patients without coronary stenosis, it is still unclear whether stenting is useful because of the lack of information about long term clinical outcomes. In our patient, vasospasmotic segments were clearly defined in the same locations of the coronaries in 2 consecutive angiographies. They persisted despite ongoing use of vasodilatory medi-

cations. After the stent implantation she had no further angina symptoms in a 4-month period, so we did not need to search for ischemia. We believe stenting could be an attractive alternative therapy in combination with medical treatment in drug-resistant patients when a vasospastic segment can be clearly identified, as in our case.

Our patient had rapid-rate sustained ventricular tachycardia, leading to hemodynamic instability and the need for resuscitation. Currently, there was no consensus regarding ICD implantation in such patients. The Japanese Coronary Spasm Association risk score is a scoring system developed to identify high-risk vasospastic angina patients.^[7] According to that system, a history of resuscitated cardiac arrest due to coronary vasospasm constitutes the highest risk for future adverse cardiac events. Recently, there have been reports favoring the implantation of an ICD for secondary prevention in those cases. Matsue et al.,^[8] retrospectively observed 23 vasospastic angina patients with ICD implantation due to resuscitated ventricular tachycardia or fibrillation. At 3 years of follow-up, 5 patients (21%) had lethal arrhythmias and received appropriate shocks. Among 2032 vasospastic angina patients of a recent multi-center retrospective cohort, 188 of them had a history of resuscitation for cardiac arrest and followed-up for adverse events over a 7-year period.^[9] Cardiac death and death from any cause were significantly higher in survivors of cardiac arrest. ICD implantation was performed in 12.8% of the patients with resuscitated cardiac arrest and 20% of them were reported to receive appropriate shocks. The authors concluded that ICD implantation might prevent future cardiac events in those high-risk vasospastic angina patients. Meisel et al.,^[10] reported that 7 patients out of 8 who had had residual symptoms despite medical therapy had a recurrence of ventricular arrhythmia. Several case reports in the literature also support the implantation of an ICD in sudden cardiac death survivors of vasospastic angina patients.^[11,12] Our case had medically resistant vasospasm leading to resistant ventricular tachycardia. At follow-up, there was no episode tachycardia on her telemetry or Holter records. Because of the ongoing nature of the disease process and risk for recurrent events in the future, our patient was diagnosed as high-risk vasospastic angina and considered for ICD implantation. After searching the literature and discussing the idea at our joint meeting, we offered the patient the option

of an ICD implant and explained all the pros and cons. Lifelong use of just antiarrhythmic medications could lead to significant side effects as well as possible proarrhythmia. After receiving the informed consent of the patient, an ICD was implanted.

In conclusion, response to medical treatment is usually good in cases of vasospastic angina, but there is a refractory group that needs special care. We believe that stent implantation can be an alternative approach in resistant cases if a vasospastic segment is definite, as in our case. Lethal cardiac arrhythmia can be seen, though it is rare. As vasospastic angina has no definitive treatment, it cannot be accepted as being a reversible cause of ventricular arrhythmia. ICD implantation should be kept in mind for survivors of lethal arrhythmia due to coronary vasospasm in combination with optimal medical treatment. Large, multi-center trials are needed to document definitive treatment options for resistant vasospastic angina patients. We believe our case may offer clinicians an option in future challenging cases of vasospastic angina.

Conflict-of-interest: None declared.

REFERENCES

1. Eschalier R, Souteyrand G, Jean F, Roux A, Combaret N, Saludas Y, et al. Should an implanted defibrillator be considered in patients with vasospastic angina? *Arch Cardiovasc Dis* 2014;107:42–7. [\[CrossRef\]](#)
2. Bory M, Pierron F, Panagides D, Bonnet JL, Yvorra S, Desfossez L. Coronary artery spasm in patients with normal or near normal coronary arteries. Long-term follow-up of 277 patients. *Eur Heart J* 1996;17:1015–21. [\[CrossRef\]](#)
3. Takagi Y, Yasuda S, Tsunoda R, Ogata Y, Seki A, Sumiyoshi T, et al. Japanese Coronary Spasm Association. Clinical characteristics and long-term prognosis of vasospastic angina patients who survived out-of-hospital cardiac arrest: multicenter registry study of the Japanese Coronary Spasm Association. *Circ Arrhythm Electrophysiol* 2011;4:295–302. [\[CrossRef\]](#)
4. Gaspardone A, Tomai F, Versaci F, Ghini AS, Polisca P, Crea F, et al. Coronary artery stent placement in patients with variant angina refractory to medical treatment. *Am J Cardiol* 1999;84:96–8. [\[CrossRef\]](#)
5. Chu G, Zhang G, Zhang Z, Liu S, Wen Q, Sun B. Clinical outcome of coronary stenting in patients with variant angina refractory to medical treatment: a consecutive single-center analysis. *Med Princ Pract* 2013;22:583–7. [\[CrossRef\]](#)
6. JCS Joint Working Group. Guidelines for diagnosis and treatment of patients with vasospastic angina (Coronary Spastic Angina) (JCS 2013). *Circ J* 2014;78:2779–801. [\[CrossRef\]](#)
7. Takagi Y, Takahashi J, Yasuda S, Miyata S, Tsunoda R, Ogata Y, Seki A, et al. Japanese Coronary Spasm Association. Prognostic stratification of patients with vasospastic angina: a comprehensive clinical risk score developed by the Japanese Coronary Spasm Association. *J Am Coll Cardiol* 2013;62:1144–53. [\[CrossRef\]](#)
8. Matsue Y, Suzuki M, Nishizaki M, Hojo R, Hashimoto Y, Sakurada H. Clinical implications of an implantable cardioverter-defibrillator in patients with vasospastic angina and lethal ventricular arrhythmia. *J Am Coll Cardiol* 2012;60:908,13.
9. Ahn JM, Lee KH, Yoo SY, Cho YR, Suh J, Shin ES, et al. Prognosis of Variant Angina Manifesting as Aborted Sudden Cardiac Death. *J Am Coll Cardiol* 2016;68:137–45. [\[CrossRef\]](#)
10. Meisel SR, Mazur A, Chetboun I, Epshtein M, Canetti M, Gallimidi J, et al. Usefulness of implantable cardioverter-defibrillators in refractory variant angina pectoris complicated by ventricular fibrillation in patients with angiographically normal coronary arteries. *Am J Cardiol* 2002;89:1114–6.
11. Al-Sayegh A, Shukkur AM, Akbar M. Automatic implantable cardioverter defibrillator for the treatment of ventricular fibrillation following coronary artery spasm: a case report. *Angiology* 2007;58:122–5. [\[CrossRef\]](#)
12. Hendriks ML, Allaart CP, Bronzwaer JG, Res JJ, de Cock CC. Recurrent ventricular fibrillation caused by coronary artery spasm leading to implantable cardioverter defibrillator implantation. *Europace* 2008;10:1456–7. [\[CrossRef\]](#)

Keywords: Implantable cardioverter defibrillator; stent; vasospastic angina.

Anahtar sözcükler: İmplant edilebilir defibrilatör; stent; vazospastik angina.