

Successful percutaneous coronary intervention for acute coronary syndrome in a patient with haemophilia B

Akut koroner sendromlu hemofili B hastasına başarılı perkütan koroner girişim

Erkan Köklü, M.D., Nermin Bayar, M.D., İsa Öner Yüksel, M.D., Murat Esin, M.D., Şakir Arslan, M.D.

Department of Cardiology, Antalya Training and Research Hospital, Antalya

Summary– Haemophilia is a congenital coagulation defect brought about by the deficiency or lack of coagulation factor IX. The prevalence of coronary artery disease and acute coronary syndrome (ACS) is lower among haemophiliacs than in the normal population. However, with the administration of factor concentrate, average life expectancy can now extend to as long as 70 years in patients with haemophilia, and this in turn is leading to an increase in the prevalence of cardiac diseases among this population. Data regarding a treatment protocol for ACS and percutaneous coronary intervention (PCI) in patients with congenital coagulation defects is limited. We report a 41-year-old male patient with haemophilia B who presented with a non-ST elevation myocardial infarction, and on whom PCI was performed following monitoring of factor IX levels. The patient had no cardiovascular risk factor except smoking.

Haemophilia B is a congenital coagulation defect caused by the absence of factor IX, and inherited in an X-linked recessive pattern.^[1] Eighty-five percent of haemophiliacs are haemophilia A and 15% are haemophilia B, which has a frequency of 1/50.000. Owing to innovations in the treatment of haemophilia, and particularly the use of factor IX concentrate, life expectancy among haemophiliacs is now comparable to that among the normal population.^[2,3] On a parallel with this, the incidence of cardiovascular diseases has also grown among haemophilia patients. Acute coronary syndrome (ACS) is rare among haemophiliacs since the hypocoagulable state tends to augment bleeding and serves to protect against thrombotic events in patients with congenital coagulation defects.^[4,5]

Özet– Kalıtsal koagülasyon defekti olan hemofili hastalarında koroner arter hastalığı ve akut koroner sendrom (AKS) görülme sıklığı normal popülasyona göre daha azdır. Dışardan faktör konsantrelerinin verilmesiyle hemofilik hastaların ortalama yaşam süreleri 70 yıla ulaşmıştır. Hemofilik hastalarda uzayan yaşam süresi ile beraber yaşla paralel seyreden kalp hastalıklarının görülme sıklığı da artmıştır. Koagülasyon defekti olan hastalarda AKS takibi ve perkütan koroner girişim (PKG) gerektiğinde uygulanacak tedavi protokolüne dair veriler sınırlıdır. Bu yazıda, ST yükselmesiz miyokart enfarktüsü tablosuyla başvurup plazma faktör IX düzeyi takip edilerek PKG yapılan 41 yaşındaki hemofili B'li erkek hasta olgusu sunuldu. Hastada sigara kullanımı dışında kardiyovasküler risk faktörü bulunmuyordu.

However, when it occurs, it is vital to manage the balance between bleeding and thrombosis in the patient on whom percutaneous coronary intervention (PCI) is performed. Data concerning this clinical entity is restricted.

We present a 41-year-old male patient with haemophilia B presenting with non-ST elevation myocardial infarction (NSTEMI). The patient's plasma factor IX levels were monitored and PCI successfully performed.

Abbreviations:

ACS	Acute coronary syndrome
aPTT	Activated partial thromboplastin time
ASA	Acetylsalicylic acid
BMS	Bare metal stent
CAG	Coronary angiography
NSTEMI	Non-ST elevation myocardial infarction
STEMI	ST elevation myocardial infarction
PCI	Percutaneous coronary intervention

Received: July 18, 2014 Accepted: March 13, 2015

Correspondence: Dr. Erkan Köklü, Yenigün Mahallesi, 1067 Sokak, 6b/13, Muratpaşa, Antalya.

Tel: +90 242 - 249 44 00 e-mail: drerkankoklu@gmail.com

© 2015 Turkish Society of Cardiology



CASE REPORT

A forty one-year-old male patient with haemophilia B presented to another hospital with squeezing chest pain. NSTEMI was diagnosed and acetylsalicylic acid (ASA) 300 mg and clopidogrel 300 mg were administered. He was transferred to our hospital 8 hours after diagnosis. He was having atypical chest pains lasting 1–2 minutes which were not accompanied by electrocardiographic changes. While his physical examination, electrocardiogram and echocardiogram were normal, troponin I was ascertained to be 2.4 ng/ml (normal value <0.06 ng/ml). His blood pressure and heart rate were 110/70 mmHg and 68/min respectively, and haemogram and biochemical parameters were all within normal ranges. INR was 1.13 and activated partial thromboplastin time (aPTT) was 52 seconds (normal range 25–36 seconds). The patient had been using 1000 units of factor IX three times weekly. He was referred to the haematology department in order to arrange early intervention.

A target of +70% was set for factor IX level at pre-procedure and for 3 days post-procedure. With his level at only 8%, the patient was administered 3500 units of factor IX intravenously (immunine factor IX, Eczacıbaşı-Baxter) one hour before coronary angiography (CAG). Following the infusion of factor IX, aPTT was 39 seconds. Atorvastatin 20 mg, metoprolol 50 mg and ramipril 5 mg were added to his medication. No typical chest pain necessitating additional

medication occurred. CAG was performed using JR4 and JL4 6F catheters via the right femoral artery 18 hours after the patient's first complaint of chest pain. Heparin was not given pre- or post-procedure. CAG revealed non-significant lesions in the left coronary arteries, and 99% stenosis in the posterolateral branch of the right coronary artery (RCA) (Figure 1a). A 2.5x14 mm bare metal stent (BMS) was implanted (Figure 1b). Following 2 hours of PCI, the sheath was removed and the entry site manually compressed for 15 minutes. Neither bleeding nor haematoma was observed in the right groin. 1000 u, 1000 u and 500 u of factor IX were given daily for 3 days post-procedure as the patient's levels of factor IX were 54%, 49% and 59% respectively. At the end of one month, clopidogrel was stopped and ASA 100 mg and other medications were continued. During a follow-up of 8 months, the patient remained stable for cardiac outcome.

DISCUSSION

Atherosclerosis increases with ageing in haemophilia patients. Biere-Rafi et al. stated that the number of deaths owing to arterial thrombosis was 50% lower in patients with haemophilia than in the normal population. Moreover, while intima-media thickness of the carotid and femoral arteries was the same in both populations, the prevalence of atherosclerotic plaque was lower in patients with haemophilia.^[6] Death due to coronary artery disease and ACS is reported as diminished in patients with haemophilia compared with the

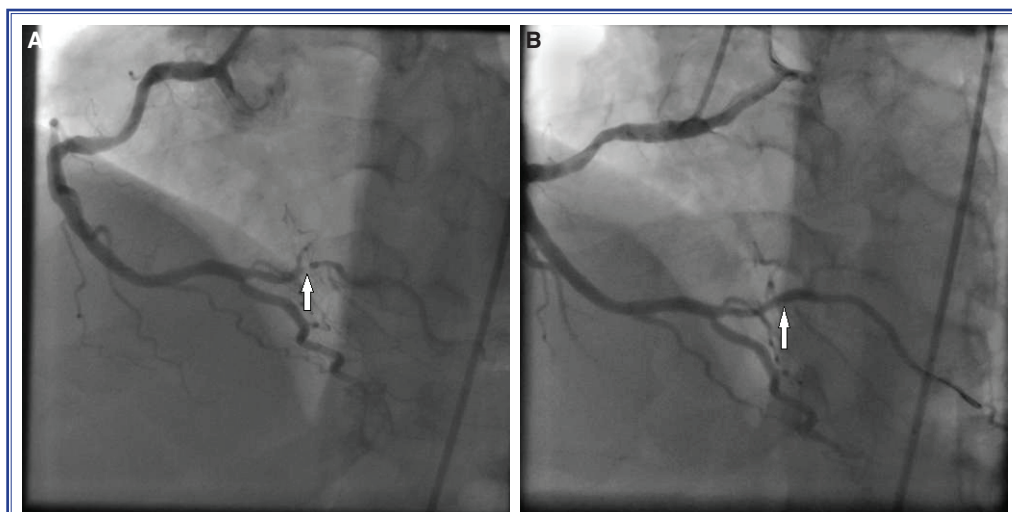


Figure 1. (A) Critical lesion of 99% in the posterolateral branch of RCA. **(B)** RCA angiography following 2.5x14 mm BMS implantation.

normal population.^[7] Thus, the hypocoagulable state might be seen as a protector against acute thrombosis rather than against atherosclerosis.

The variance of cardiovascular risk factors for patients with haemophilia is different from the normal population. A large European cross-sectional study revealed that hypertension was more frequent (49% vs. 40%), and obesity and hypercholesterolemia were lower (15% vs. 20%, 44% vs. 68%, respectively) in patients with haemophilia than in the normal population, while the percentages for smoking and diabetes mellitus were similar in both groups.^[8] Our patient was young compared to those in the literature, and the only cardiovascular risk factor present was smoking.

Indications and timing of urgent CAG and indications of primary PCI are the same in haemophiliacs and non-haemophiliacs.^[9] Patients with haemophilia and ST elevation myocardial infarction (STEMI) should be directed to centres capable of primary PCI as fibrinolytic therapy is contraindicated in patients with bleeding diathesis.^[9] Cooperation between cardiologists and haematologists is strongly recommended for follow-up of these patients.^[9]

Of major bleedings after PCI, 70% occur at the entry site or in the retroperitoneal region. Radial artery catheterization is recommended to minimize bleeding complications in patients with bleeding diathesis.^[10] Contrary to this recommendation, the literature review for this case report revealed that most coronary interventions in patients with haemophilia are performed via the femoral route with no significant bleeding complication. Closure devices are recommended in order to decrease bleeding complications at the entry site after removal of the femoral sheath.^[11] Level of aPTT in our case was 39 seconds prior to CAG, and rose over time. Delayed retraction of the femoral sheath means retraction while aPTT is higher, which could possibly enhance bleeding risk. Therefore, the femoral sheath was withdrawn at 2 rather than 4 hours after CAG.

Intravenous factor concentrates are administered to patients with haemophilia to reduce bleeding complications. It is recommended that they be administered intravenously because in patients treated with the bolus form acute thrombosis is expected because of the rapid increase in factor levels. One case of STEMI owing to bolus administration of factor concentrate was reported in the literature.^[12]

There is no exact data on factor IX levels to be obtained in various clinical situations in patients with haemophilia. The European Society of Cardiology (ESC) guidelines on acute coronary syndromes in patients with haemophilia recommend that the level of factor IX be kept around 50% (30%–80%) for 24 hours after PCI in patients with haemophilia. The guidelines also emphasize that factor IX levels of more than 80% could result in thrombosis, and recommend that factor IX level be higher than 5–15%, particularly in patients taking dual antiplatelet therapy. In long-term follow-up, the guidelines call for factor IX level to be kept above 5% if the patient is taking dual antiplatelet therapy and above 1% if the patient is taking only ASA in order to avoid bleeding.^[9] In our case, the patient's factor IX level on admission was 8%, which we consider was due to the administration of factor IX concentrate 30 hours before chest pain began. We maintained factor IX level at approximately 70% for 72 hours, which is longer than the guidelines recommend. The dosage was calculated using this formula: Factor IX level needed = (factor IX level targeted – plasma factor IX level) x 2 x plasma volume (40 u/kg x body weight).^[4] Our patient's weight was 73 kg. Plasma factor IX level of 8% and target plasma factor IX level was 70%. Factor IX level needed = (0.70–0.08) x 2 x 40 u/kg x 73 = 3620 u. Thereafter, the patient continued to take 3 doses of 1000 u of factor IX per week, as he had been doing prior to treatment.

There is no consensus concerning anticoagulant therapy in patients with ACS and haemophilia. While unfractionated heparin (UFH) is preferred as an anticoagulant due to its shorter half-life and presence of its antidote, there is no recommendation against use of other anticoagulants. UFH is not suggested unless the patient takes factor concentrate, and it is administered either full dose according to patient weight, or reduced dose according to thrombotic risk in a patient given factor concentrate.^[9] We did not administer anticoagulant treatment to our patient. However, we consider that UFH might be administered to those patients with a dose of PCI, due to the nature of acute coronary syndrome.

Thrombocyte count and functions are normal in haemophilia patients. Dual antiplatelet therapy is recommended owing to the risk of stent thrombosis after PCI. On the other hand, the use of antiaggregant treatment increases bleeding risk, particularly in the gas-

trointestinal system.^[9] The addition of proton pump inhibitors to antiaggregant treatment is recommended to reduce this risk. Bare metal rather than drug eluting stents are recommended because the switch from dual antiplatelet therapy to single antiplatelet treatment should be done as soon as possible. Thus, one month is generally adequate for dual antiplatelet therapy and ASA is generally continued after 1 month. Antiaggregant doses are applied as in patients without haemophilia.^[9] We considered that administration of an additional 300 mg of clopidogrel to our patient was more convenient. A BMS was also used for our patient and loading doses of ASA and clopidogrel were given. ASA 100 mg and clopidogrel 75 mg were prescribed for one month, following which clopidogrel was abandoned and ASA was recommended indefinitely.

PCI may be quite reliable in patients with haemophilia provided that factor IX levels are monitored closely. Use of a BMS, and dual antiplatelet therapy for one month may reduce bleeding complications.

Conflict-of-interest issues regarding the authorship or article: None declared.

REFERENCES

1. Biggs R, Douglas As, Macfarlane Rg, Dacie Jv, Pitney Wr, Merskey. Christmas Disease: A Condition Previously Mistaken For Haemophilia. *Br Med J* 1952;2:1378–82. [CrossRef](#)
2. Schutgens RE, Tuinenburg A, Roosendaal G, Guyomi SH, Mauser-Bunschoten EP. Treatment of ischaemic heart disease in haemophilia patients: an institutional guideline. *Haemophilia* 2009;15:952–8. [CrossRef](#)
3. Mannucci PM. Management of antithrombotic therapy for acute coronary syndromes and atrial fibrillation in patients with hemophilia. *Expert Opin Pharmacother* 2012;13:505–10.
4. Coppola A, De Simone C, Di Capua M, Tufano A, Cimino E, Conca P, et al. Acute coronary syndrome and severe haemophilia: an unusual association with challenging treatment. *Thromb Haemost* 2010;103:1270–2. [CrossRef](#)
5. Paolini R, Viero M, Pietrogrande F, Girolami A. Mild haemophilia A fails to protect from coronary artery disease: the report of two cases. *Haematologia (Budap)* 1993;25:179–84.
6. Biere-Rafi S, Zwiers M, Peters M, van der Meer J, Rosendaal FR, Büller HR, et al. The effect of haemophilia and von Willebrand disease on arterial thrombosis: a systematic review. *Neth J Med* 2010;68:207–14.
7. Plug I, Van Der Bom JG, Peters M, Mauser-Bunschoten EP, De Goede-Bolder A, Heijnen L, et al. Mortality and causes of death in patients with hemophilia, 1992–2001: a prospective cohort study. *J Thromb Haemost* 2006;4:510–6. [CrossRef](#)
8. Fransen van de Putte DE, Fischer K, Makris M, Tait RC, Chowdhury P, Collins PW, et al. Unfavourable cardiovascular disease risk profiles in a cohort of Dutch and British haemophilia patients. *Thromb Haemost* 2013;109:16–23. [CrossRef](#)
9. Staritz P, de Moerloose P, Schutgens R, Dolan G; ADVANCE Working Group. Applicability of the European Society of Cardiology guidelines on management of acute coronary syndromes to people with haemophilia - an assessment by the ADVANCE Working Group. *Haemophilia* 2013;19:833–40.
10. White GC 2nd, Rosendaal F, Aledort LM, Lusher JM, Rothschild C, Ingerslev J; Factor VIII and Factor IX Subcommittee. Definitions in hemophilia. Recommendation of the scientific subcommittee on factor VIII and factor IX of the scientific and standardization committee of the International Society on Thrombosis and Haemostasis. *Thromb Haemost* 2001;85:560.
11. Arzu E, Emre AR, Mehmet K, Selim Y, Necmi D. Percutaneous coronary intervention in left main coronary artery disease in a patient with hemophilia B. *Cardiovasc Interv Ther* 2011;26:153–6. [CrossRef](#)
12. Alsolaiman MM, Chang K, Arjomand H, Oza R, Costacurta G. Acute left anterior descending artery occlusion in a hemophiliac A patient during recombinant factor VIII infusion: treatment with coronary angioplasty. *Catheter Cardiovasc Interv* 2000;50:468–72. [CrossRef](#)

Key words: Acute coronary syndrome; angioplasty, balloon, coronary; factor IX, coagulation; hemophilia B; percutaneous coronary intervention.

Anahtar sözcükler: Akut koroner sendrom; anjiyoplasti, balon, koroner; faktör IX, koagülasyon; hemofili B; perkütan koroner girişim.