

Cardiac metastasis of an esophageal cancer: a rare cause of ventricular tachycardia and left ventricle outlet obstruction

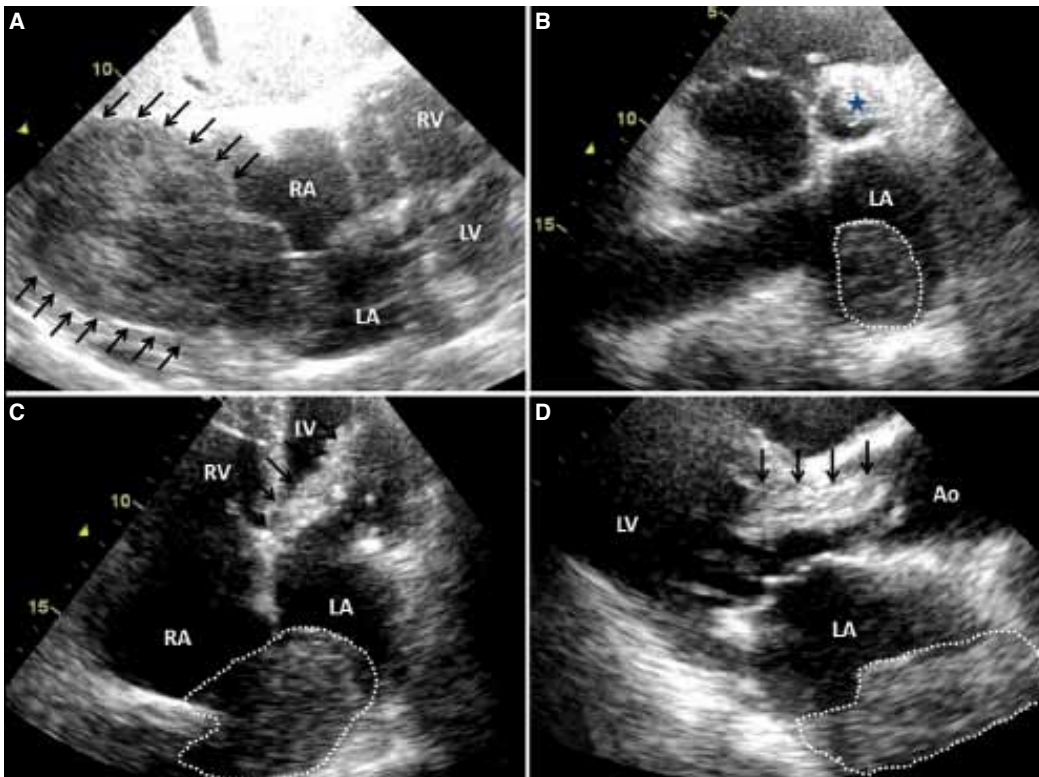
Özofagus kanserinin kalbe metastazı: Ventriküler taşikardi ve sol ventrikül çıkış yolu obstrüksiyonunun nadir bir nedeni

Özcan Başaran
Can Yücel Karabay#
Ahmet Güler#
Cevat Kıрма#

Department of Cardiology,
Mugla University Training and
Research Hospital, Mugla;
#Department of Cardiology,
Kartal Kosuyolu Training and
Research Hospital, İstanbul

An 80-year-old woman was admitted to our hospital with palpitations and shortness of breath. She had been diagnosed with esophageal cancer (squamous cell carcinoma) one year ago. A physical examination revealed a 2/6 systolic murmur on the left sternal border. Her pulse was weak and irregular at a rate of 170 bpm. Her blood pressure was taken as 90/50 mmHg. An ECG showed wide QRS complexes. She was diagnosed with ventricular tachycardia. As the patient was symptomatic, DC cardioversion was performed, and sinus rhythm was restored. Echocardiographic examination showed

left atrial and ventricular cardiac mass (Fig. A). A detailed examination showed the tumor had a direct extension to the pericardium and had invaded all of the cardiac layers (Fig. A and supplementary Video 1*). Intracardiac masses were detected in the left and right atria and left ventricle. The tumor in the left ventricle appeared to be a solitary metastasis and was protruding through the left ventricle outlet (Figs. B-D and supplementary Videos 2-4*). Amiodarone therapy was initiated and the patient was referred to oncology but she died the following day. We hypothesized that the mass in the left and right atria was a direct extension or a lymphatic spread of the tumor, while the solitary left ventricular mass was probably an intracavitary diffusion of the tumor from pulmonary veins. Hematopoietic myocardial metastasis might also have played a role in the metastasis of the tumor as conduction system abnormalities were associated with myocardial metastasis.



Figures— Transthoracic echocardiography of the patient. (A) Subcostal view: Arrows showing the mass infiltrating all three cardiac layers. (B) Modified parasternal short-axis view showing left atrial (dotted line) and left ventricular outlet mass (star). (C, D) Apical four-chamber and long-axis views showing left and right atrial mass (dotted line) and left ventricle outlet obstruction by the mass (arrows). *Supplementary video files associated with this presentation can be found in the online version of the journal.

