

## Non-invasive estimation of pericardial effusion volume by three-dimensional speckle-tracking echocardiography (From the MAGYAR-Path Study)

### Üç boyutlu speckle-tracking eko-kardiyografiyle perikart efüzyon volümünün girişimsel olmayan yöntemle hesaplanması (MAGYAR-Path çalışması)

Attila Nemes

Péter Domsik

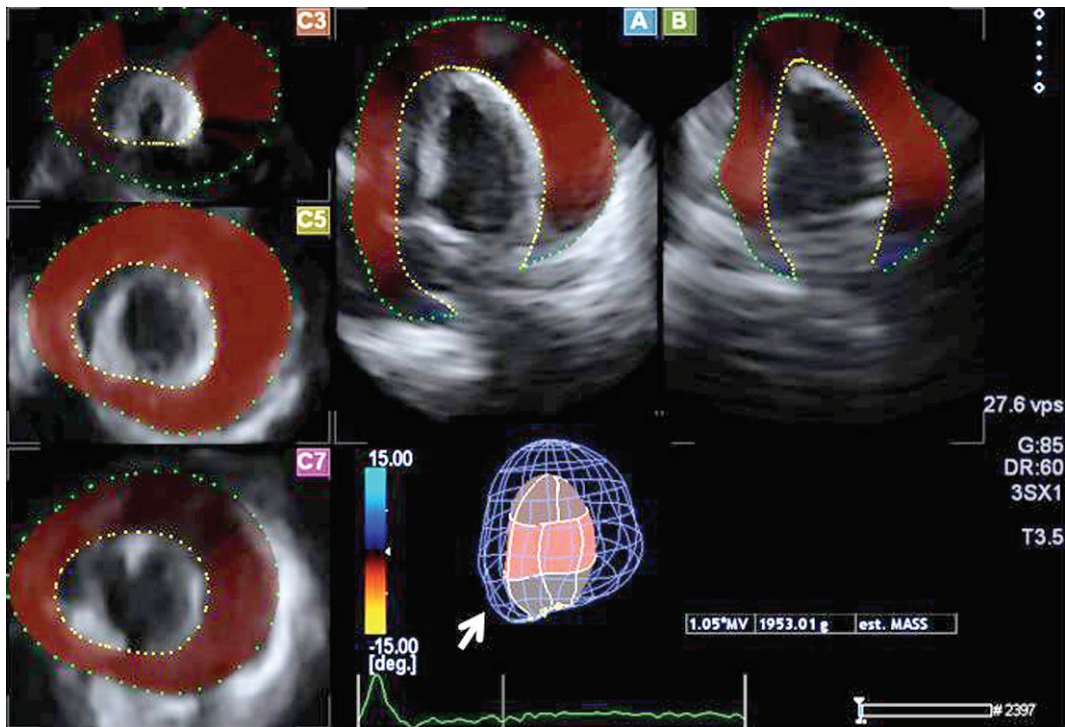
Anita Kalapos

Tamás Forster

2nd Department of Medicine  
and Cardiology Centre,  
University of Szeged, Szeged,  
Hungary

Two-dimensional transthoracic echocardiography has limitations in assessing size and extent of pericardial fluids. Three-dimensional (3D) speckle-tracking echocardiography (3DSTE) is a new 3D echocardiographic technology which allows quantification of volumes, strains and rotational characteristics of heart chambers. We present a 46-year-old symptomatic male patient with massive pericardial effusion, who was examined using 3DSTE. The patient was involved in the **MAGYAR-Path Study** (Motion Analysis of the heart and Great vessels bY three-dimensional speckle-tracking echocardiography in **Pathological** cases). Apical 4-chamber (A) and 2-chamber (B), and short-axis views at different levels (C3, C5, C7) of

the heart extracted from a 3D echocardiographic dataset are shown in Figure. During a regular 3DSTE examination, quantification of left ventricular (LV) mass is based on the definition of epicardial and endocardial LV borders. However, due to 3DSTE's incapability to assess pericardial effusion, the following manipulations were used for quantitative evaluations: The parietal membrane of the pericardium was defined as the "epicardial border", while the visceral membrane of the pericardium served as the "endocardial border" in multiple views. Pericardial effusion was defined as a volume in between (see table:  $1953/1.05=1860$  ml). An echo-guided pericardiocentesis produced 1800 ml of serosanguineous fluid, confirming results. The 3D model of the pericardial effusion (blue mesh) and the heart (coloured cast) could also be created (see white arrow). The results of this case suggest, that 3DSTE could be used as a simple non-invasive tool for quantitative assessment of pericardial effusion volume.



**Figures–** Three-dimensional speckle tracking echocardiographic estimation of pericardial effusion volume.