

Management of Intramyocardial Dissecting Hematoma Following Myocardial Infarction

Miyokart Enfarktüsü Sonrası Gelişen Miyokart içi Disekan Hematomun Tedavisi

ABSTRACT

Intramyocardial dissecting hematoma (IDH) is a rare condition mostly seen following acute myocardial infarction, chest trauma, and cardiac surgery. It is described as an incomplete rupture caused by hemorrhagic dissection within the myocardium, rather than extending to the epicardial layer. Management strategies for IDH are controversial due to limited reports. We present a case of a 61-year-old man diagnosed with IDH, left main, and three-vessel disease, subsequently treated surgically.

Keywords: Acute coronary syndrome, cardiac surgery, myocardial ischemia

ÖZET

Miyokart içi disekan hematom (MDH) sıklıkla akut miyokart enfarktüsü, göğüs travması, kalp cerrahisi sonrası görülebilen nadir bir komplikasyondur. Hemorajik diseksiyonun epikardiyal tabakaya uzanmaktan çok miyokardın içerisinde olduğu kısmi rüptür olarak tanımlanmaktadır. Miyokart içi hematomun tedavisinin yönetimi, sınırlı sayıda yayınlar bulunması nedeniyle tartışmalıdır. Bu yazıda MDH ile sol ana koroner arter ve üç damar hastalığı tanısı konulan ve ardından cerrahi olarak tedavi edilen 61 yaşında bir erkek hasta sunuyoruz.

Anahtar Kelimeler: Akut koroner sendrom, kardiyak cerrahi, miyokart iskemisi

Intramyocardial dissecting hematoma (IDH) is a rare mechanical complication following myocardial infarction.¹ Due to its rarity, our knowledge is mainly based on case reports or case series.² Although the dissection does not extend to the epicardium, which is a form of contained rupture, it carries an increased risk of mortality. Management strategies can be either conservative or involve surgical repair, depending on the size of the hematoma, revascularization strategies, and the hemodynamic and clinical status of the patient.^{3,4} Here, we discuss an IDH case treated with surgical evacuation of the hematoma, left ventricular repair, and three-vessel bypass surgery.


Case Report

A 61-year-old man with a history of smoking and hypertension presented with a few weeks-long history of intermittent chest pain and dyspnea. An electrocardiogram showed ST segment elevation and pathological Q waves in the V1-6 leads, suggesting a late stage of anterior wall myocardial infarction (Figure 1A). Transthoracic echocardiography revealed an ejection fraction (EF) of about 35%, with apical dyskinesis and a hypoechoic area surrounded by a clear, mobile endomyocardial border at the apex of the left ventricle (LV), suggesting IDH (Figures 1B and 1C, Video 1). There was no sign of blood flow into the IDH on color Doppler imaging (Video 2). Urgent coronary angiography revealed a 70% diameter stenosis of the distal left main coronary artery, extending into the ostia of the left anterior descending and circumflex arteries, causing 90% and 70% diameter stenoses, respectively. The right coronary artery showed 80% to 98% diffuse stenosis. Cine cardiac magnetic resonance (CMR) imaging displayed a hyperintense area along the mid to apical anterior, mid to apical lateral, and apical segments, sandwiched between

CASE REPORT OLGU SUNUMU

Beytullah Çakal¹ 

Sinem Çakal² 

Korhan Erkanlı³ 

¹Department of Cardiology, Istanbul Medipol University Hospital, Istanbul, Türkiye

²Department of Cardiology, Haseki Training and Research Hospital, Istanbul, Türkiye

³Department of Cardiovascular Surgery, Istanbul Medipol University Hospital, Istanbul, Türkiye

Corresponding author:

Beytullah Çakal
✉ bçakal@hotmail.com

Received: May 20, 2023

Accepted: August 08, 2023

Cite this article as: Çakal B, Çakal S, Erkanlı K. Management of intramyocardial dissecting hematoma following myocardial infarction. *Türk Kardiyol Dern Ars.* 2024;52(4):290-292.

DOI:10.5543/tkda.2023.15424



Available online at archivestsc.com.
Content of this journal is licensed under a
Creative Commons Attribution -
NonCommercial-NoDerivatives 4.0
International License.

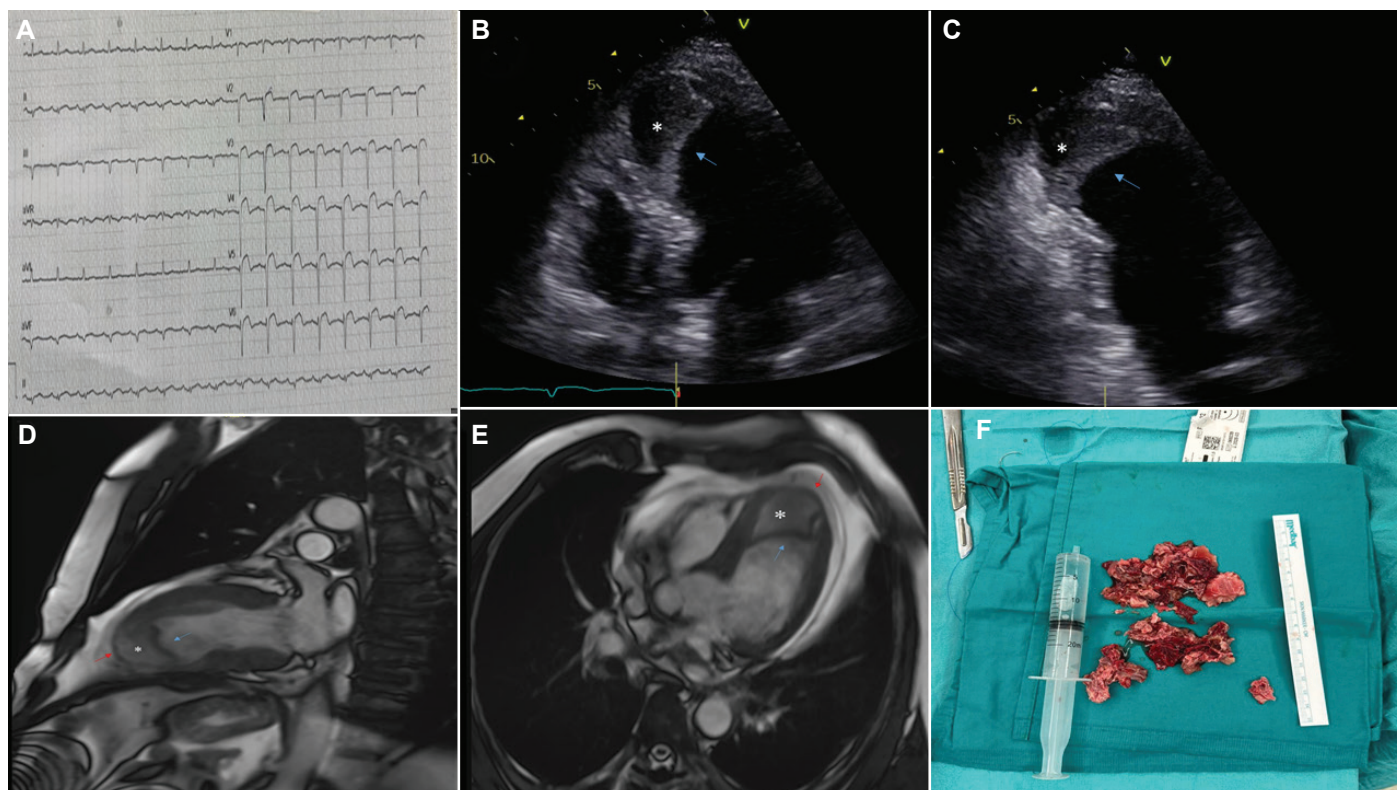


Figure 1. (A) ECG demonstrating ST-segment elevation with pathological Q waves in leads V2-6. **(B, C)** Four-chamber and two-chamber views of the LV showing a hypoechoic area without an obvious mobile thrombus. Still frames of cardiac magnetic resonance imaging from three-chamber **(D)** and four-chamber **(E)** orientations. A hyperintense structure consistent with the diagnosis of intramyocardial dissecting hematoma (white asterisk) (55 x 50 x 27 mm) is noted along the mid to apical anterior, mid to apical lateral, and apical segments, wrapped by a thinner layer of subendocardium (blue arrow) and subepicardium (red arrow). **(F)** Surgical specimen of hematoma-myocardial fragments from the dissected myocardium.

thinner layers of subendocardium and subepicardium, confirming the diagnosis of IDH (Figures 1D and 1E).

Due to the left main and three-vessel disease and the extent of the hematoma, the patient was scheduled for cardiac surgery. Medical management with frequent echocardiographic examinations during the hospital stay was carried out. He was discharged with acetylsalicylic acid, atorvastatin, perindopril, and metoprolol therapy. Ten days after hospital discharge, bypass surgery with evacuation of the hematoma (Figure 1F) and linear aneurysmectomy repair reinforced with Teflon strips were performed, resulting in a favorable postoperative course. Control echocardiography performed one month after the surgery showed an echodense area suggestive of a thrombosed residual intramyocardial hematoma (Video 3).

Discussion

Intramyocardial dissecting hematoma is a rare complication of acute myocardial infarction, but it may also occur after

trauma, post cardiac surgery, or spontaneously.^{1, 3-6} Hemorrhagic dissection within the myocardial fibers, rupture of intramyocardial vessels, impaired tensile strength of the infarcted myocardium, and increased perfusion pressure can lead to IDH. The outer wall of the hematoma is formed by the myocardium or pericardium, with a thin endocardial wall on the other side. Liu et al.⁷ showed that even if the culprit vessel is revascularized with a Thrombolysis in Myocardial Infarction (TIMI) flow grade 3, microvessels could remain obstructed in 80% of patients, and hemorrhage could occur in 80% of the cases, contributing to microvascular destruction and IMH. However, early revascularization could halt or slow the risk of reperfusion-related hemorrhage and potentially offer myocardial salvage, especially if performed within 72 hours. For this particular case, the patient's delayed admission could have possibly induced IDH.

Left ventricular apical thrombus or aneurysm may mimic IDH due to limited experience, lack of image quality, and its rarity, thus the diagnosis of IDH may be overlooked. The distinction from an apical thrombus could be made by identifying the endocardial border circumscribing the hematoma formation and its systolic expansion.⁸ CMR is more accurate for diagnosing IDH. Cine CMR shows a hyperintense region sandwiched between the subendocardium and subepicardium (Figures 1D and 1E, asterisk). Heterogeneous signals within this formation include hyperintense regions in the subepicardium with a larger area of isointense signals in the

ABBREVIATIONS

CMR	Cardiac magnetic resonance
EF	Ejection fraction
IDH	Intramyocardial dissecting hematoma
LV	Left ventricle
TIMI	Thrombolysis in Myocardial Infarction

myocardium and throughout the subendocardium, as derived from T2-weighted imaging. Visually apparent heterogeneous T2 signal with a hypointense signal on late gadolinium-enhanced CMR is suggestive of a thrombus; however, since this thrombus is located within the midmyocardium, sandwiched between the infarcted subendocardium and subepicardium, IDH can be quite easily differentiated from a left ventricular thrombus.⁹ In the case of inappropriate anticoagulation therapy due to misdiagnosis as an apical thrombus, there may be progression of the hematoma and bleeding into the pericardial space or LV cavity, which may result in sudden cardiac death. Thus, in our case, only aspirin was administered.

Presenting late after symptom onset, persistent ST segment elevation for more than 72 hours, and initial presentation with mild pericardial effusion should alert the physician to the suspicion of IDH. With the help of imaging modalities such as CMR, accurate diagnosis is important, as this could significantly impact patient treatment.⁶

Myocardial infarction involving the anterior wall accounts for most cases, and rupture of the hematoma into the pericardial or left ventricular cavity usually results in sudden death. Different aspects of IDH can be observed during its course, including resorption and thrombus formation. In our case, intramyocardial hematoma and its resorption were detected as an echo-lucent area within the myocardium.

The management of IDH depends on numerous factors, such as age, hemodynamic status, extent of the hematoma, EF, anterior myocardial infarction, amount of pericardial effusion,^{10,11} and its communication with the ventricular cavity. Vargas-Barrón reported an overall mortality of 47%, which rises to 78% if the septum is involved.¹¹ IDH without hemodynamic compromise could be managed conservatively; however, cases with enlarging hematoma, ventricular septal defect, increased pericardial effusion, left ventricular dysfunction in the setting of acute myocardial infarction, or the need for revascularization should undergo surgery.

Although IDH as a complication of myocardial infarction is rarely seen, treatment options should be individualized, such as a conservative approach with the expectation of resorption or surgical resection of the necrotic material and evacuation of the hematoma, as described in this case.

Informed Consent: Informed consent was obtained from the patient.

Peer-review: Externally peer-reviewed.

Author Contributions: Concept - B.Ç.; Design-B.Ç.; Supervision - K.E.; Resource - K.E.; Materials - K.E.; Data Collection and/or Processing -

B.Ç.; Analysis and/or Interpretation - S.Ç.; Writing - B.Ç., S.Ç., K.E.; Critical Review - K.E.

Use of AI for Writing Assistance: The authors declared no AI assistance during any stage for preparation of the manuscript.

Conflict of Interest: The authors have no conflicts of interest to declare.

Funding: The authors declared that this study received no financial support.

Video 1. Apical four-chamber view demonstrating an echolucent area within the myocardium surrounded by the endocardium.

Video 2. No blood flow was detected into the hematoma by color Doppler imaging.

Video 3. Follow-up echocardiography one month after surgery revealed an echodense area, suggesting the gradual regression of the hematoma post-surgery.

References

- Higashigaito K, Manka R, Taramasso M, Maisano F, Alkadhi H, Holubec T. Spontaneous Intramural Hematoma of the Left Ventricle. *Circulation*. 2016;133(5):543-545. [CrossRef]
- Lee TJ, Roslan A, Teh KC, Ghazi A. Intramyocardial dissecting haematoma mimicking left ventricular clot, a rare complication of myocardial infarction: a case report. *Eur Heart J Case Rep*. 2019;3(2):ytz056. [CrossRef]
- Silverstein JR, Tasset MR, Dowling RD, Alshaher MM. Traumatic intramyocardial left ventricular dissection: a case report. *J Am Soc Echocardiogr*. 2006;19(12):1529.e5-8. [CrossRef]
- Wakatabe M, Kotani S, Inoue Y. Non-ischaemic intramyocardial dissection following total arch replacement. *Interact Cardiovasc Thorac Surg*. 2020;31(2):268-270. [CrossRef]
- Zavar R, Vakhshoori M, Mirmohammadsadeghi M, Hashemi-Jazi M. A rare case of takotsubo syndrome led to intra-myocardial dissection and left ventricular apical aneurysm. *ARYA Atheroscler*. 2019;15(1):33-37.
- Gandhi S, Wright D, Salehian O. Getting over a Broken Heart: Intramyocardial Dissecting Hematoma as Late Presentation of Myocardial Infarction. *CASE (Phila)*. 2017;1(6):245-249. [CrossRef]
- Liu T, Howarth AG, Chen Y, et al. Intramyocardial Hemorrhage and the "Wave Front" of Reperfusion Injury Compromising Myocardial Salvage. *J Am Coll Cardiol*. 2022;79(1):35-48. [CrossRef]
- Agarwal G, Kumar V Jr, Srinivas KH, Manjunath CN, Prabhavathi B. Left Ventricular Intramyocardial Dissecting Hematomas. *JACC Case Rep*. 2020;3(1):94-98. [CrossRef]
- Alyousef T, Malhotra S, Iskander F, et al. Left Ventricular Intramyocardial Dissecting Hematoma: A Multimodality Imaging Diagnostic Approach. *Circ Cardiovasc Imaging*. 2021;14(7):e012410. [CrossRef]
- Leitman M, Tyomkin V, Sternik L, Copel L, Goitein O, Vered Z. Intramyocardial dissecting hematoma: Two case reports and a meta-analysis of the literature. *Echocardiography*. 2018;35(2):260-266. [CrossRef]
- Vargas-Barrón J, Roldán FJ, Romero-Cárdenas A, et al. Dissecting intramyocardial hematoma: clinical presentation, pathophysiology, outcomes and delineation by echocardiography. *Echocardiography*. 2009;26(3):254-261. [CrossRef]