

Alternative method for accessing the target coronary artery in patients with difficult coronary anatomy: exchanging the diagnostic catheter with a guiding catheter

Zor koroner anatomili hastanın hedef koroner arterine kateter yerleştirilmesinde alternatif bir yöntem: Tanısal kateterin kılavuz kateter ile değiştirilmesi

Ejder Kardeşoğlu, M.D., Murat Yalçın, M.D., Turgay Çelik, M.D.,# Namık Özmen, M.D.

Department Cardiology, Gülhane Military Medical Academy, Haydarpaşa Training Hospital, Istanbul;

#Department of Cardiology, Gülhane Military Medical Academy, Ankara

Summary– We report a method of the placement of the guiding catheter in two cases in which the diagnostic catheter could be easily engaged to the target coronary arteries but not a guiding catheter, due to a distorted aortic sinus and an osteal subtotal occlusion, respectively. After engaging to the target coronary artery with a diagnostic catheter, a coronary guidewire was advanced through the diagnostic catheter, and exchanged with a guiding catheter over the guidewires. The procedures were completed with success.

In percutaneous coronary interventions (PCI), the selection of the guiding catheter is an important step which may directly affect the procedural success. The engagement of the coronary artery with a guiding catheter may be difficult in cases with aorto-osteal lesions and an abnormal origin of the coronary arteries. It may rarely lead to premature termination of the procedure. As a general rule, a guiding catheter in the same size with the diagnostic one is used. The manipulation of the guiding catheter may be different from those of the same size diagnostic catheter because their designs are distinct from each other.^[1,2] Therefore, while the coronary artery is easily selected with a diagnostic catheter, sometimes the cardiologist may have difficulty with a guiding catheter.^[3-5]

We described a method for the engagement of the target coronary artery by exchanging the diagnos-

Özet– Bu yazıda, tanısal kateterin hedef koroner artere yerleştirilebildiği ancak aortik sinüsün distorsiyonu veya ostiyumdaki subtotal tıkanma gibi nedenlerle kılavuz kateterin yerleştirilemediği iki olguda kılavuz kateteri yerleştirebilmek için alternatif bir yöntem sunuldu. Hedef koroner artere tanısal kateterle girdikten sonra koroner kılavuz teli tanısal kateter içinden ilerletilerek koroner artere girildi. Daha sonra kılavuz teli üzerinden kılavuz kateteri ilerletilerek koroner artere yerleştirildi ve tanısal kateter ile değiştirildi. İşlem başarıyla tamamlandı.

tic catheter with a guiding catheter in two cases with an abnormal origin of the coronary artery and an aorto-osteal lesion, respectively.

Abbreviations:

PCI	Percutaneous coronary interventions
RCA	Right coronary artery
LAD	Left anterior descending

CASE REPORT

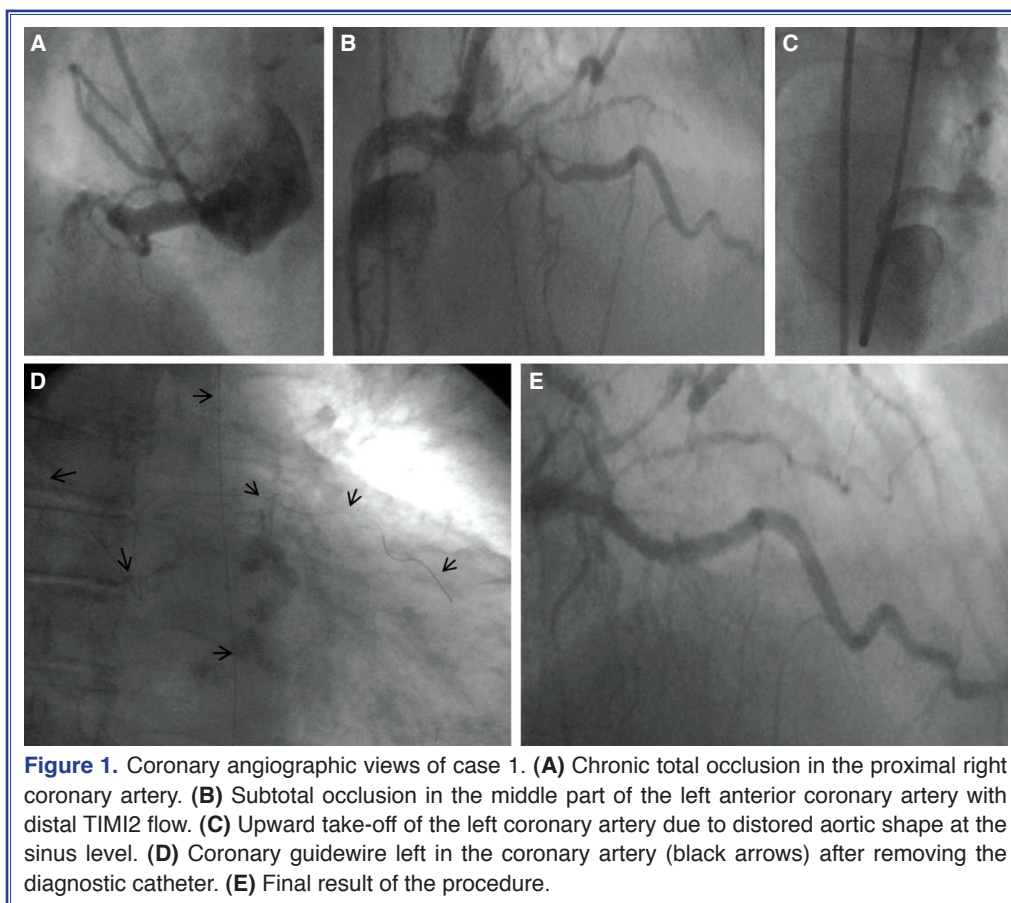
Case 1- A 78-year-old female was admitted to the emergency room presenting with prolonged typical chest pain with ST-segment elevation at the anterior leads. The patient's hemodynamics were stable. The patient was taken to the catheterization laboratory for primary PCI. Diagnostic coronary angiography, performed via femoral approach, demonstrated a chronic total occlusion in the proximal right coronary artery (RCA) giving some bridging collaterals

Received: February 08, 2012 Accepted: April 12, 2012

Correspondence: Dr. Ejder Kardeşoğlu. GATA Haydarpaşa Eğitim Hastanesi, Kardiyoloji Kliniği, 34668 Üsküdar, İstanbul, Turkey.

Tel: +90 - 212 - 542 23 85 e-mail: ekardesoglu@yahoo.com

© 2012 Turkish Society of Cardiology

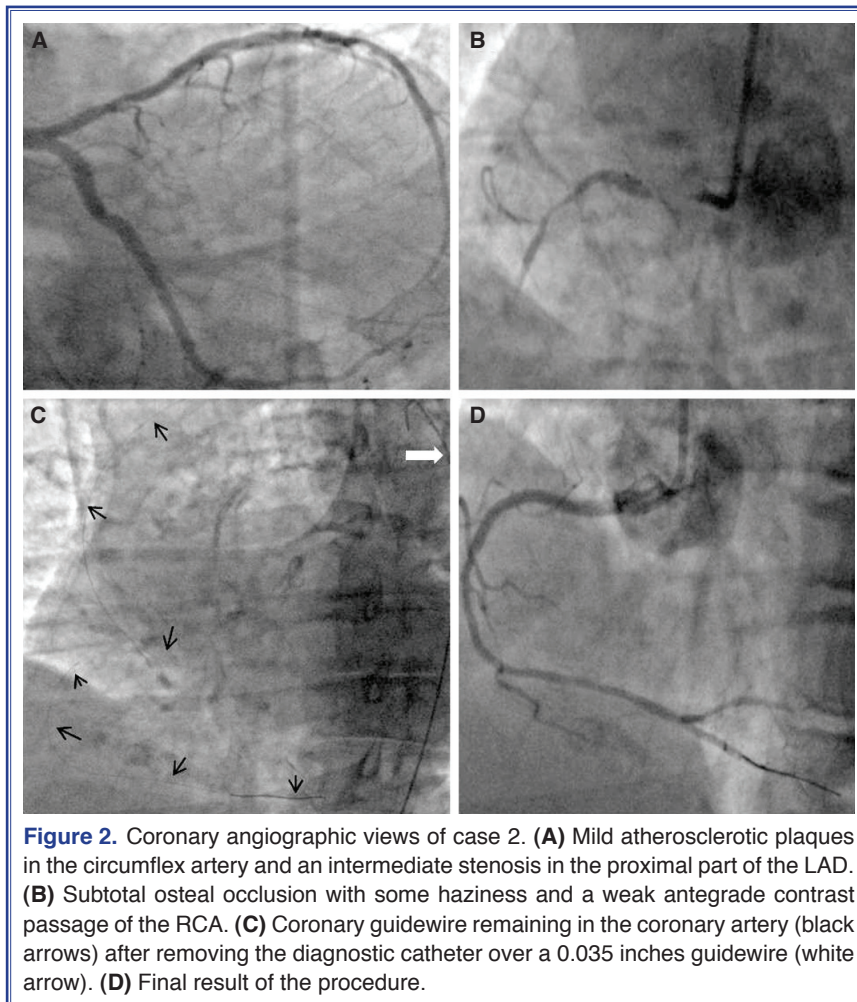


which slightly fill the distal part (Fig. 1A). In the left coronary system, there was no significant stenosis in the circumflex artery, and there was a subtotal occlusion in the middle part of the left anterior coronary artery (LAD) with distal TIMI2 flow (Fig. 1B). The left coronary artery was accessed using a 6 French diagnostic JL4 catheter (Boston Scientific Corp., USA) without any difficulty. We failed in selecting the left coronary artery despite many attempts, using several various curved guiding catheters. The left aortic cuspid angiography demonstrated an upward take-off of the left coronary artery due to distorted aortic shape at the sinusal level (Fig. 1C). We decided to use the diagnostic catheter to access the left main coronary artery. A floppy coronary guide-wire (Asahi Intecc Co., Japan) was easily advanced to the distal LAD through the JL4 diagnostic catheter. The coronary guidewire was extended with an extension wire. A 0.035 inches guidewire was placed within the diagnostic catheter for achieving a better support during the manipulation. The diagnostic catheter was slightly pulled back into the aorta. The coronary guidewire was advanced

slightly for performing a small loop above the aortic valve (Fig. 1D).

The diagnostic catheter was then gently removed over the guidewires, under fluoroscopy. A 3.5 Extra Back-Up guiding catheter (Medtronic Inc., USA) was carefully advanced over the same guidewires up to the left aortic sinus with same manner. The 0.035 inches guidewire was removed, and the guiding catheter was connected with a Y connector. The guiding catheter was meticulously engaged to the left main coronary artery by pulling the coronary guidewire. A 2.75x24 mm bare metal stent (Biotronik Se & Co., Germany) was implanted with distal TIMI3 flow (Fig. 1E).

Case 2- A 75-year-old obese female patient with a medical history of hypertension and chronic obstructive pulmonary disease was evaluated for the typical chest pain despite maximum medical treatment which had been started just after prosthetic hip surgery performed a month before. We performed diagnostic coronary angiography using femoral approach. Diagnostic coronary angiography revealed mild athero-



sclerotic plaques in the circumflex artery and intermediate stenosis in the proximal part of the LAD (Fig. 2A).

The septal arteries demonstrated grade 2 collaterals to the distal RCA. The RCA was engaged using a diagnostic JR4 coronary catheter (Boston Scientific Corp., USA) with a few manipulations. We detected a subtotal ostial occlusion with some haziness and a weak antegrade contrast passage (Fig. 2B). We decided to determine the hemodynamic importance of the stenosis in the proximal LAD, using fractional flow reserve. This measurement showed that the lesion was not hemodynamically significant. We decided to attempt an intervention to the ostial occlusion at the RCA. However, we could not select the ostium of the RCA despite using many different shaped guiding catheters, and we failed to cross the ostial lesion at the RCA with a coronary guidewire. We decided to use the same method described in Case 1, to access

the RCA with a guiding catheter. After engaging the ostium of the RCA with a 5F diagnostic catheter, a floppy coronary guidewire (Asahi Intecc Co., Japan) was advanced to the distal RCA through the diagnostic catheter without any difficulty. The coronary guidewire was extended with an extension wire. A 0.035 inches guidewire was inserted within the diagnostic catheter for better support during the manipulation. The diagnostic catheter was slightly removed from the ostium of the RCA. The coronary guidewire was advanced to perform a small loop within the aortic sinus (Fig. 2C).

The diagnostic catheter was exchanged with a guiding catheter using the same manner described in Case 1. We successfully implanted two stents in the ostial lesion (Endeavor stent, Medtronic Inc., USA). We achieved an acceptable angiographic view with the well-opposed stents and a distal TIMI 3 flow (Fig. 2D).

DISCUSSION

Placement of a suitable guiding catheter into the target coronary artery is the first step of the procedure.^[1] We described a relatively simple and easy method to access the target coronary artery in two cases in which a diagnostic catheter but not a guiding catheter was inserted easily. In this method, either a coronary guidewire extended with an extension wire or a long coronary guidewire should be used through the diagnostic catheter. Following this step, the diagnostic catheter should be exchanged with a suitable guiding catheter over the coronary guidewire. The first important part of the method is to keep the coronary guidewire in place during the exchange procedure. For this issue, making a small loop with a coronary guidewire in the related aortic sinus after removing the diagnostic catheter from the coronary ostium as well as using a 0.035 guidewire for the support seem to be adequate. The second critical step is placing the guiding catheter into the coronary ostium, without losing the guidewire position. It appears quite enough using the same maneuver when the guiding catheter leaves the coronary ostium during a PCI. Pulling the guidewire back gently while advancing the guiding catheter will help.

In previous literature, researchers have reported using similar methods for some neurovascular interventions.^[6] In the neurovascular interventions, exchanging the diagnostic catheter with a guiding catheter seems relatively easy, since the target organ is stationary. The movement of the coronary arteries makes this exchange more challenging than those in the neurovascular interventions. Another case report, utilized an approach similar to ours, in which the guiding catheter was replaced over the coronary guidewire by another one, giving more support.^[7] In addition, the diagnostic catheters were used for PCIs in some case reports.^[8,9] Especially in acute coronary syndromes, it appears advantageous in lowering the procedure time. This approach may not be possible to

perform in complex cases in which bulky devices are required. In conclusion, the diagnostic catheter can be used for exchange with a guiding catheter over the coronary guidewire in suitable cases.

Conflict-of-interest issues regarding the authorship or article: None declared

REFERENCES

1. Baim DS. Percutaneous balloon angioplasty and general coronary intervention. In: Baim DS, editor. *Grossman's Cardiac Catheterization, Angiography&Intervention*. 7th ed. Philadelphia: Lippincott Williams&Wilkins. 2006. p. 433-6.
2. Pavei A, Marco J. Tools & techniques: choice and use of guiding catheters. *EuroIntervention* 2010;6:543-4.
3. Sarkar K, Sharma SK, Kini AS. Catheter selection for coronary angiography and intervention in anomalous right coronary arteries. *J Interv Cardiol* 2009;22:234-9.
4. Turgut O, Tandogan I, Dizman R. Use of the RCB guide in PCI of a chronic total occlusion in an anomalous right coronary artery with high anterior takeoff. *J Invasive Cardiol* 2009;21:E70-2.
5. Sarkar K, Sharma SK, Kini AS. Catheter selection for coronary angiography and intervention in anomalous right coronary arteries. *J Interv Cardiol* 2009;22:234-9.
6. Nagayama T, Nishimuta Y, Sugata S, Nishizawa T, Arita K. Use of a guide wire system to insert guiding catheters. *J Neurosurg* 2010;112:1232-4.
7. Op de Beeck V, Agostoni P. Changing the guiding catheter over the coronary wire: a simple (and cheap) technique to get out of trouble. *Acta Cardiol* 2009;64:817-9.
8. Keller PF, Gosselin G, Grégoire J, Guédès A, Verin V. Feasibility of the PCI through 6F diagnostic catheters. *Catheter Cardiovasc Interv* 2007;69:410-5.
9. Chen YQ, Hou L, Wei YD, Li WM, Xu YW. Feasibility of using 6F angiographic catheters for primary percutaneous coronary intervention in patients with acute myocardial infarction. *Chin Med J (Engl)* 2010;123:1345-6.

Key words: Angioplasty, transluminal, percutaneous coronary; heart catheterization/instrumentation/methods; coronary angiography; coronary stenosis/therapy.

Anahtar sözcükler: Anjiyoplasti, translüminal, perkütan koroner; kalp kateterizasyonu/enstrümantasyon/yöntem; koroner anjiyografi; koroner darlık/televi.