

An impressive image of woven right coronary artery

“Örgü” sağ koroner arterin etkileyici bir görüntüsü

Mustafa Oylumlu, M.D., Abdulkadir Yıldız, M.D., Hasan Kaya, M.D., Faruk Ertaş, M.D.

Department of Cardiology, Dicle University Faculty of Medicine, Diyarbakir

Summary– Woven coronary artery is a rare congenital anomaly with an unknown etiology. A 53-year-old male presented with exertional chest pain and dyspnea for six months. Electrocardiogram and transthoracic echocardiography were in normal range. Dobutamine stress echocardiography revealed reversible ischemia in the inferior wall. Right coronary angiography showed an 80% stenosis before the sinoatrial branch and a twisting course of the right coronary artery lumen after it divided into multiple thin channels. Left coronary angiogram revealed noncritical lesions. A diagnosis of woven right coronary artery was considered, and he was discharged with medical therapy.

Woven coronary artery is a rare congenital anomaly with an unknown etiology. This anomaly can be at any level of the coronary artery formed by a twisting course of multiple thin channels along the vessel and then combination of these fine channels with the main channel. It is thought to be a benign anomaly and is well defined in the right and left coronary arteries.

In this case, we describe a 53-year-old male patient with a woven right coronary artery (RCA).

CASE REPORT

A 53-year-old male with exertional chest pain was admitted to our hospital. The patient had no other cardiac risk factors except smoking. His complaints were angina and shortness of breath with exertion for the previous six months. His admission electrocardiography was normal. Transthoracic echocardiography revealed normal left ventricular wall motion with a left ventricular ejection fraction of 60%. Reversible ischemia in the inferior wall was

Özet– Örgü koroner arter etiyolojisi bilinmeyen nadir bir doğumsal anomalidir. Elli üç yaşında erkek hasta altı aydır olan eforla göğüs ağrısı ve nefes darlığı şikayeti ile başvurdu. Hastanın elektrokardiyografi ve transtorasik ekokardiyografi bulguları normal idi. Dobutamin stres ekokardiyografide inferiyor duvarda iskemi saptanması üzerine yapılan koroner anjiyografide sağ koroner arterde (RCA) sinoatrial dal öncesi %80 darlık ve darlık sonrasında RCA'nın çok sayıda ince kanala ayrılıp kıvrımlı seyrettiği görüldü. Sol koroner arterde kritik olmayan lezyonlar mevcuttu. “Örgü” koroner arter tanısı konulan hasta tıbbi tedavi ile taburcu edildi.

demonstrated on the dobutamine stress echocardiography.

Right coronary angiography revealed an 80% stenosis before the sinoatrial branch. Beyond this stenosis, the main lumen was divided into thin channels having a twisting course along the RCA and merging just before the crux (Fig. 1a, b, Videos 1, 2*). Left coronary angiogram revealed an ectatic dilatation in the mid portion of the circumflex artery and left anterior descending artery (Fig. 1c, arrow, Video 3*). Medical therapy was initiated.

Abbreviation:

RCA Right coronary artery

DISCUSSION

Woven coronary artery is a rare anomaly in which twisting multiple thin channels at any segment of the coronary artery merge again to form the main lumen. [1] It has a very characteristic appearance similar to that of braided hair (woven). In the literature, some 10 cases have been reported including either the RCA or the left coronary system. The etiology is unknown and

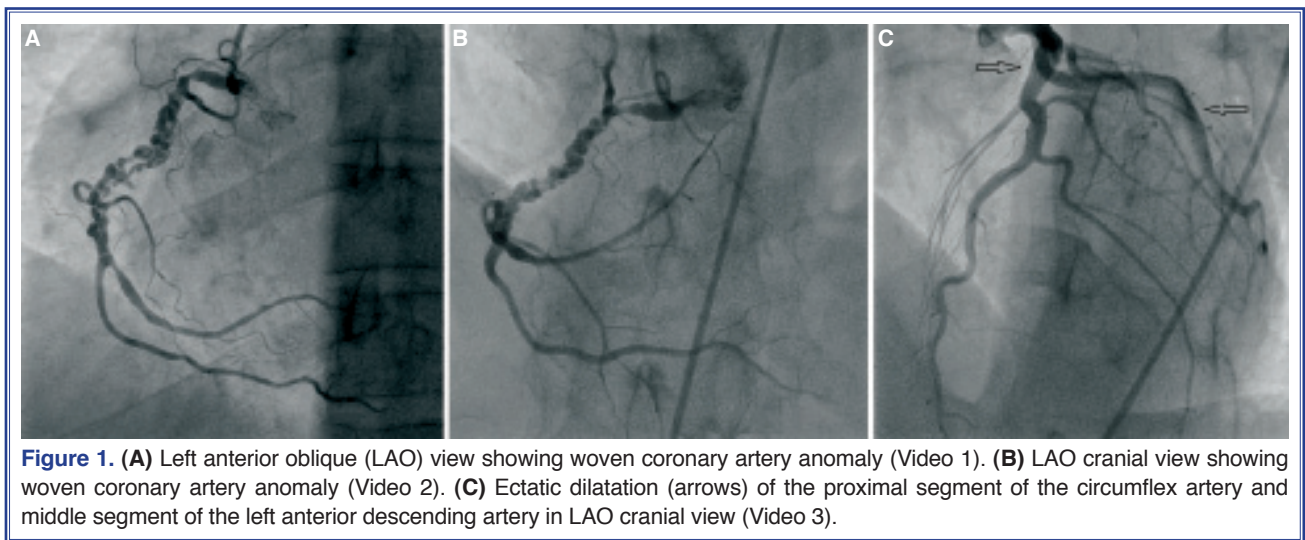
Received: March 11, 2013 Accepted: April 29, 2013

Correspondence: Dr. Mustafa Oylumlu. Dicle Üniversitesi Tıp Fakültesi Kalp Hastanesi, 21280 Diyarbakır.

Tel: +90 412 - 248 80 01 e-mail: dr.oylumlu@yahoo.com

© 2013 Turkish Society of Cardiology





there are limited data available because of the small number of cases. However, some authors have suggested that this anomaly is the result of spontaneous coronary artery dissection.^[2] It can be misdiagnosed as an intracoronary thrombus or spontaneous or iatrogenic coronary artery dissection.^[2,3]

Usually, a woven coronary artery does not disturb the coronary blood flow, and it is believed to be a benign condition. No adverse coronary events were detected during the 3-5-year follow-up period in the cases reported by Martuscelli et al.,^[2] Kursaklioglu et al.^[4] and Iyisoy et al.^[5]

As woven coronary artery does not interfere with distal blood flow, negative stress tests are expected in this anomaly. In our case, positive dobutamine stress echocardiography could be explained by 80% stenosis in the proximal RCA. Percutaneous coronary intervention for the stenotic lesion was not appropriate, and metoprolol 50 mg/day, perindopril 10 mg/day, atorvastatin 20 mg/day, and acetyl salicylic acid 100 mg/day were prescribed for the patient.

Recognition of this anomaly can be difficult, which sometimes results in misdiagnosis. For this reason, in cases of angiographic filling defects with normal distal blood flow, different projections of cine-angiographic images and careful radiological examination of these enlarged images can help in the correct diagnosis. Although this anomaly appears to be a

benign coronary anomaly without any major adverse cardiovascular events, like in our case, more data are needed to understand precisely the pathophysiology of this malformation.

Conflict-of-interest issues regarding the authorship or article: None declared.

***Supplementary video files associated with this article can be found in the online version of the journal.**

REFERENCES

1. Sane DC, Vidaillet HJ Jr. "Woven" right coronary artery: a previously undescribed congenital anomaly. *Am J Cardiol* 1988;61:1158. [CrossRef](#)
2. Martuscelli E, Romeo F, Giovannini M, Nigri A. Woven coronary artery: differential diagnosis with diffuse intracoronary thrombosis. *Ital Heart J* 2000;1:306-7.
3. Kaya D, Kilit C, Onrat E. An uncommon congenital anomaly of coronary arteries misdiagnosed as intracoronary thrombus: woven coronary artery disease. *Anadolu Kardiyol Derg* 2006;6:383-4.
4. Kursaklioglu H, Iyisoy A, Celik T. Woven coronary artery: a case report and review of literature. *Int J Cardiol* 2006;113:121-3. [CrossRef](#)
5. Iyisoy A, Celik T, Yuksel UC, Isik E. Woven right coronary artery: a case report and review of the literature. *Clin Cardiol* 2010;33:43-5. [CrossRef](#)

Key words: Coronary angiography; woven coronary artery.

Anahtar sözcükler: Koroner anjiyografi; örgü koroner arter.