

## Isotretinoin-associated possible Kounis syndrome: A case report and a review of other cardiovascular side effects reported in the literature

### İsotretinoin ile ilişkili olası Kounis sendromu: Olgu sunumu ve diğer kardiyovasküler yan etkilerin literatür derlemesi

● Murat Akçay, M.D., ● Serkan Yüksel, M.D.

Department of Cardiology, Ondokuz Mayıs University Faculty of Medicine, Samsun, Turkey

**Summary**– Isotretinoin is widely used in the treatment of acne vulgaris and other dermatological diseases. Numerous side effects have been reported in the literature. A myocardial bridge occurs when segments of the coronary artery create an intramyocardial tunnel. Atherosclerotic plaque formation frequently occurs in the segment proximal to a myocardial bridge. Coronary thrombus formation, which is often the cause of myocardial infarction in young patients, can be triggered by many factors. Kounis syndrome is described as acute coronary syndromes associated with allergic or hypersensitivity reactions. This article is a description of the case of a patient predisposed to the development of a thrombus by a myocardial bridge who was successfully treated for coronary thrombosis and which may represent a case of Kounis syndrome associated with isotretinoin use presented in the context of the relevant literature.

Isotretinoin, or 13-cis-retinoic acid, is a synthetic vitamin A derivative used in the therapy of acne vulgaris and other dermatological diseases.<sup>[1]</sup> It has been used since 1980 and side effects have been reported in the literature.<sup>[2]</sup> It is known to be teratogenic, and in addition, adverse nervous system, musculoskeletal, ocular, gastrointestinal, hematological, psychiatric, and cardiac system effects have also been reported.<sup>[1,2]</sup> Furthermore, cases of hyperlipidemia, insulin-resistance and diabetes, myocardial infarction, thromboembolism, and stroke have been reported in the literature.<sup>[2,3]</sup> Kounis syndrome is described as acute coronary syndromes associated with allergic or hypersensitivity reactions.<sup>[4,5]</sup> Foods; drugs, most

**Özet**– İsoetretinoin, akne ve diğer dermatolojik hastalıklarda yaygın olarak kullanılmaktadır ve literatürde birçok yan etki bildirilmektedir. Miyokardiyal köprüleşme, koroner arterin belli segmentinin intramiyokardiyal tünel biçimli seyir izlemesidir. Miyokardiyal köprünün olduğu koroner arter segmentinin proksimalinde sıklıkla aterosklerotik plak oluşumu izlenir. Genç hastalarda miyokart enfaktüsüne sıklıkla neden olan koroner arterde trombüs oluşumunu tetikleyen birçok faktör olabilmektedir. Kounis sendromu, alerjik ya da hipersensivite reaksiyonunun eşlik ettiği akut koroner olay olarak tanımlanmaktadır. Bu yazıda miyokardiyal köprüleşmenin zemin hazırladığı koroner trombüsün başarılı şekilde tedavi edildiği bir olgu isotretinoin ile ilişkili olası Kounis sendromu olarak tanımlanmış ve konu ile ilgili literatür eşliğinde sunulmuştur.

commonly, non-steroidal anti-inflammatory drugs; environmental exposure; and coronary stents have triggered allergic reactions.<sup>[4,5]</sup> Myocardial bridging is a congenital coronary anomaly in which a segment of the coronary artery courses intramuscularly with the myocardium overlying the artery like a bridge. This causes vessel compression in systole, resulting in hemodynamic alterations.<sup>[5]</sup> The hemodynamic changes may lead to atherosclerotic alterations to the intima and cause the intracoronary formation of a thrombus.<sup>[5,6]</sup>

Presently described is the successful treatment of a coronary thrombus in a patient susceptible to the occurrence as a result of a myocardial bridge that may

Received: December 11, 2017 Accepted: March 27, 2018

Correspondence: Dr. Murat Akçay. Ondokuz Mayıs Üniversitesi Tıp Fakültesi, Kardiyoloji Anabilim Dalı, Samsun, Turkey.

Tel: +90 362 - 312 19 19 e-mail: drmuratakay@hotmail.com

© 2019 Turkish Society of Cardiology

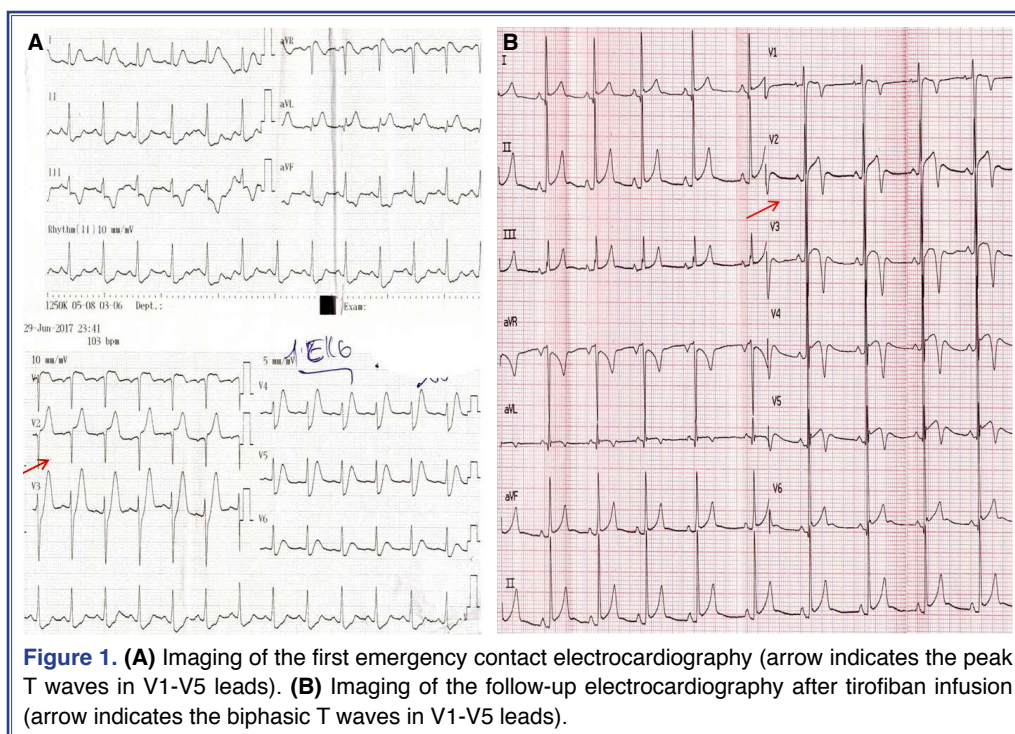


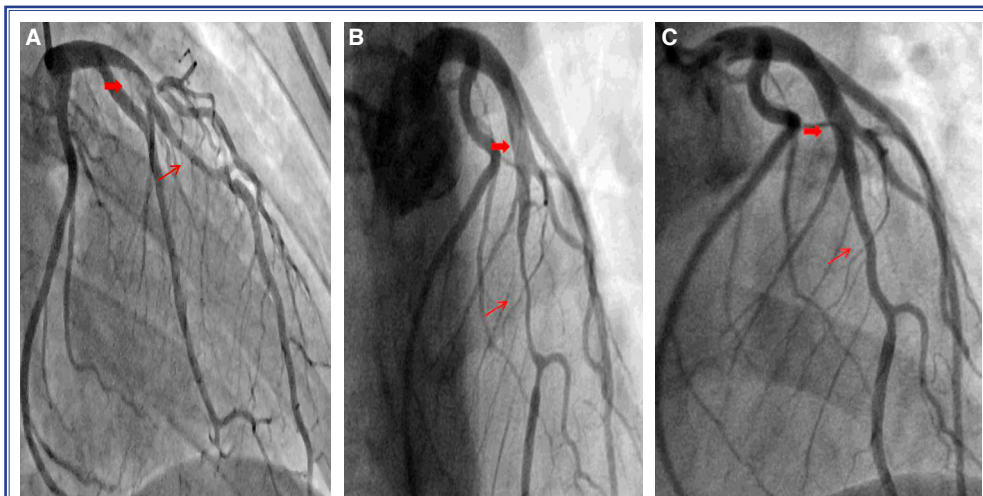
have been a case of isotretinoin-associated Kounis syndrome.

### CASE REPORT

A 25-year-old male patient presented at the emergency department with typical acute chest pain ongoing for 1 hour. The physical examination revealed a systolic blood pressure of 120 mm Hg, a diastolic blood pressure of 80 mm Hg, and a heart rate of 100 beats per minute; cardiac auscultation showed no abnormalities. Sharp T-wave and dynamic ST-segment changes were detected in the V1-V5 derivations of electrocardiography (Fig. 1a). Laboratory analysis indicated a high cardiac troponin I level of 4.1 ng/mL (normal range: 0.0–0.1 ng/mL) and a creatine kinase myocardial band mass of 8.2 ng/mL (normal range: 0.0–3.2 ng/mL). No risk factor for coronary artery disease was detected, with the exception of cigarette smoking. There was no family history of coronary artery disease, no known allergy or history of allergic reaction and no substance abuse, including cocaine. The patient stated that he had been on isotretinoin treatment (20 mg/day) for 1 week due to acne and that he had received the last dose 1 hour before the onset of his chest pain. Acetylsalicylic acid, ticagrelor, and enoxaparin were uploaded with the diagnosis of non-ST elevation myocardial infarction.

A thrombus and distal flow in the proximal left anterior descending coronary artery with a muscular bridge causing 70% to 80% stenosis were observed on coronary angiography (Fig. 2a/Video 1\*). An infusion of tirofiban was administered for 18 hours at a dose of 0.15 mcg/kg/minute. The chest pain was completely resolved. A thrombophilia evaluation, including factor V Leiden and prothrombin gene mutations, proteins C and S, anti-thrombin III, homocysteine level, and active protein C resistance, was completely negative. Blood lipid and lipoprotein levels were within the normal limits. Anti-nuclear, anti-dsDNA, and anti-cardiolipin antibodies were also within normal limits, eliminating consideration of vasculitis and connective tissue diseases. A later control coronary angiography revealed that the thrombus had decreased in size (Fig. 2b/Video 2\*). Biphasic negative T waves in the V1-V5 derivations were observed on electrocardiography (Fig. 1b). Echocardiography showed mild hypokinesia of the anterior wall with no valvular abnormality, intracardiac mass, or thrombus. Antiaggregant and anticoagulant treatment continued, and 1 week later an additional control angiography revealed that the thrombus had resolved (Fig. 2c/Video 3\*). The patient was discharged as asymptomatic with 200 mg metoprolol, ticagrelor, acetylsalicylic acid, and ator-





**Figure 2.** (A) Angiographic imaging of the left anterior descending (LAD) artery thrombotic lesion (thin arrow indicates the myocardial bridge, thick arrow indicates the thrombus). (B) Imaging of decreased LAD artery thrombus after the tirofiban infusion (thin arrow indicates the myocardial bridge, thick arrow indicates the thrombus). (C) Imaging of dissolved LAD thrombus after 1 week (thin arrow indicates the myocardial bridge area, thick arrow indicates dissolved thrombus area).

vastatin treatment. Isotretinoin therapy was discontinued. One month later, there were no signs of ischemia on myocardial perfusion scintigraphy and he was asymptomatic at the 6-month follow-up.

## DISCUSSION

To the best of our knowledge, this is the first presented case of a myocardial bridge with possible

**Table 1.** Some of the isotretinoin-associated cardiovascular side effects reported in the literature

Age-gender	Drug use time	Symptoms	Risk factors	Diagnosis	Therapy	Imaging	Physiopathology
28-year-old female <sup>[2]</sup>	One year	Chest pain	Cigarettes, oral contraceptive, high glycemia and cholesterol levels	Inferior-STEMI	Thrombus aspiration and stent implantation	Optical coherence tomography	Complicated atherosclerotic plaque
25-year-old male (Our case)	One week	Chest pain	Cigarettes, myocardial bridge	Non-STEMI	Antiaggregant, anticoagulant medications and drug cessation	No	Myocardial bridge and possible type II Kounis syndrome
26-year old female <sup>[1]</sup>	Four months	Palpitation, syncope	No	Atrial tachycardia and pericardial effusion	Drug cessation	No	Unknown
35-year old female <sup>[12]</sup>	One month	Palpitation	No	Premature ventricular contractions	Drug cessation	No	Unknown
18-year old male <sup>[13]</sup>	Three months	Palpitation	No	Sinus tachycardia and right bundle branch block	Drug cessation	No	Unknown

STEMI: ST-segment elevation myocardial infarction.

Kounis Syndrome secondary to isotretinoin treatment.

The diagnosis of Kounis syndrome is based on clinical suspicion and the signs and symptoms observed, especially after an allergic event that is the result of a hypersensitivity reaction.<sup>[4,5]</sup> It is a multifactorial pathophysiological mechanism that remains unclear.<sup>[4,5]</sup> The existing literature data related to Kounis syndrome are drawn from isolated clinical cases with different triggers. Three subtypes have been identified: Type I, coronary vasospasm; type II, atherosclerotic plaque; and type III, stent thrombosis-associated acute coronary syndrome.<sup>[4,5]</sup> Kounis syndrome type II occurs in cases of pre-existing atheromatous plaque stimulated by mediators. Treatment of the coronary event guides the appropriate therapy.<sup>[4]</sup>

A myocardial bridge is usually associated with a benign prognosis in the literature; however, it has also been considered a cause of angina, malignant arrhythmia, myocardial infarction, coronary vasospasm, and sudden cardiac death.<sup>[6-9]</sup> Atherosclerotic plaque formation in the coronary artery frequently occurs in the proximal segment of the myocardial bridge, but the tunneled segment is typically preserved.<sup>[7]</sup> Hemodynamic forces, endothelial structure disorder, and increased local arterial wall strain can cause endothelial damage and plaque fissuring with subsequent thrombus formation in the proximal region.<sup>[6,9]</sup> Agirbasli et al.<sup>[8]</sup> reported on the case of a myocardial bridge leading to thrombus formation in a young athlete. Venturini et al.<sup>[10]</sup> also reported a myocardial bridge-triggered coronary vasospasm and described it as type I Kounis syndrome.

Isotretinoin is widely used in dermatology; however, it may lead to adverse events affecting many systems.<sup>[3]</sup> Although rare, isotretinoin has been shown to be associated with adverse cardiac effects, including congenital heart disease; atrial, or rarely, ventricular arrhythmias; and coronary events due to metabolic effects.<sup>[11-14]</sup> Lorenzo et al.<sup>[2]</sup> reported the case of a myocardial infarction with accelerated atherosclerosis and plaque rupture in a young woman due to metabolic effects of isotretinoin. Isotretinoin particularly affects lipid parameters.<sup>[10]</sup> In our case, the triglyceride level was 133 mg/dL and the low-density lipoprotein cholesterol level was 127 mg/dL. Table 1 presents a summary of the major case reports presented due to cardiovascular adverse effects

in comparison with our case. The myocardial bridge in the present case may have caused pre-existing atherosclerotic plaque changes, which combined with the isotretinoin treatment, triggered the endothelial injury, plaque rupture, and thrombus formation, making it a complicated case. Since the acute coronary event developed 1 hour after the isotretinoin therapy, our case may be an example of isotretinoin-associated type II Kounis syndrome. Successful treatment of the thrombus was achieved with antiaggregants and anticoagulants. The primary limitation of this case report is the lack of an intravascular ultrasound examination of the atheromatous plaque structure due to possible complications. Intravascular ultrasound can help with treatment strategy decisions and forming an objective diagnosis.

In conclusion, isotretinoin may be associated with several cardiac adverse effects, including Kounis syndrome, as in our case. Numerous factors may trigger a coronary thrombus formation in a young patient.<sup>[15]</sup> However, the combination of a myocardial bridge with isotretinoin-induced Kounis syndrome was probably the major cause of this premature myocardial infarction. A conservative approach can be successfully applied with effective antiaggregant and anticoagulant therapy, as in our case.

\*Supplementary video file associated with this article can be found in the online version of the journal.

**Peer-review:** Externally peer-reviewed.

**Conflict-of-interest:** None.

**Informed Consent:** Written informed consent was obtained from the patient for the publication of the case report and the accompanying images.

**Authorship contributions:** Concept: M.A., S.Y.; Design: M.A.; Supervision: M.A., S.Y.; Materials: M.A., S.Y.; Data collection: M.A.; Literature search: M.A.; Writing: M.A., S.Y.

## REFERENCES

1. Güler E, Babur Güler G, Yavuz C, Kızılırmak F. An unknown side effect of isotretinoin: pericardial effusion with atrial tachycardia. *Anatol J Cardiol* 2015;15:168-9. [[CrossRef](#)]
2. Lorenzo N, Antuña P, Dominguez L, Rivero F, Bastante T, Alfonso F. Acute myocardial infarction in a young woman on isotretinoin treatment. *Int J Cardiol* 2015;181:39-41. [[CrossRef](#)]
3. Bérard A, Azoulay L, Nakhai-Pour HR, Moussally K. Isotretinoin and the risk of cardiovascular, cerebrovascular

- and thromboembolic disorders. *Dermatology* 2011;223:45–51. [CrossRef]
4. Kounis NG. Kounis syndrome: an update on epidemiology, pathogenesis, diagnosis and therapeutic management. *Clin Chem Lab Med* 2016;54:1545–59. [CrossRef]
  5. Akçay M. Ibuprofen-induced Kounis syndrome with diffuse ST segment depression and atrial fibrillation. *Anatol J Cardiol* 2017;18:380–1. [CrossRef]
  6. Möhlenkamp S, Hort W, Ge J, Erbel R. Update on myocardial bridging. *Circulation* 2002;106:2616–22. [CrossRef]
  7. Ishii T, Asuwa N, Masuda S, Ishikawa Y. The effects of a myocardial bridge on coronary atherosclerosis and ischaemia. *J Pathol* 1998;185:4–9. [CrossRef]
  8. Agirbasli M, Martin GS, Stout JB, Jennings HS 3rd, Lea JW 4th, Dixon JH Jr. Myocardial bridge as a cause of thrombus formation and myocardial infarction in a young athlete. *Clin Cardiol* 1997;20:1032–6. [CrossRef]
  9. Derkacz A1, Nowak T, Gorawski M, Bezubka J, Szelemej R. Thrombosis within the area of muscle bridge as a cause of myocardial infarction. *Kardiologia Pol* 2011;69:291–2. [Article in Polish]
  10. Venturini E, Marabotti C, Magni L, Testa R, Kounis NG. Myocardial bridge as a trigger of Kounis syndrome. *Int J Cardiol* 2016;202:87–9. [CrossRef]
  11. Karadag AS, Gumrukcuoglu HA, Gunes Bilgili S, Ozkol HU, Ertugrul DT, Simsek H, et al. Does isotretinoin therapy have any effects on electrocardiography, heart rate and blood pressure? *J Dermatolog Treat* 2012;23:168–71. [CrossRef]
  12. Alan S, Ünal B, Yildirim A. Premature ventricular contractions associated with isotretinoin use. *An Bras Dermatol* 2016;91:820–1. [CrossRef]
  13. Charalabopoulos K, Papalimneou V, Charalabopoulos A, Hatzis J. Two new adverse effects of isotretinoin. *Br J Dermatol* 2003;148:593. [CrossRef]
  14. Selcoki Y, Gorpelioglu C, Turgut F, Sarifakioglu E, Ozkara A, Tekin O, et al. Isotretinoin: is there any arrhythmic effect? *Int J Dermatol* 2008;47:195–7. [CrossRef]
  15. Kayıkçıoğlu M. How to design studies on premature myocardial infarction? *Türk Kardiyol Dern Ars* 2017;45:495–7. [Article in Turkish] [CrossRef]

---

**Keywords:** Coronary thrombus; isotretinoin; Kounis syndrome; myocardial bridge; myocardial infarction.

**Anahtar sözcükler:** Koroner trombus, isotretinoin; Kounis sendromu; miyokardiyal köprüleşme; miyokart enfarktüsü.