

## Pseudo-myocardial infarction pattern in a patient with spontaneous pneumomediastinum

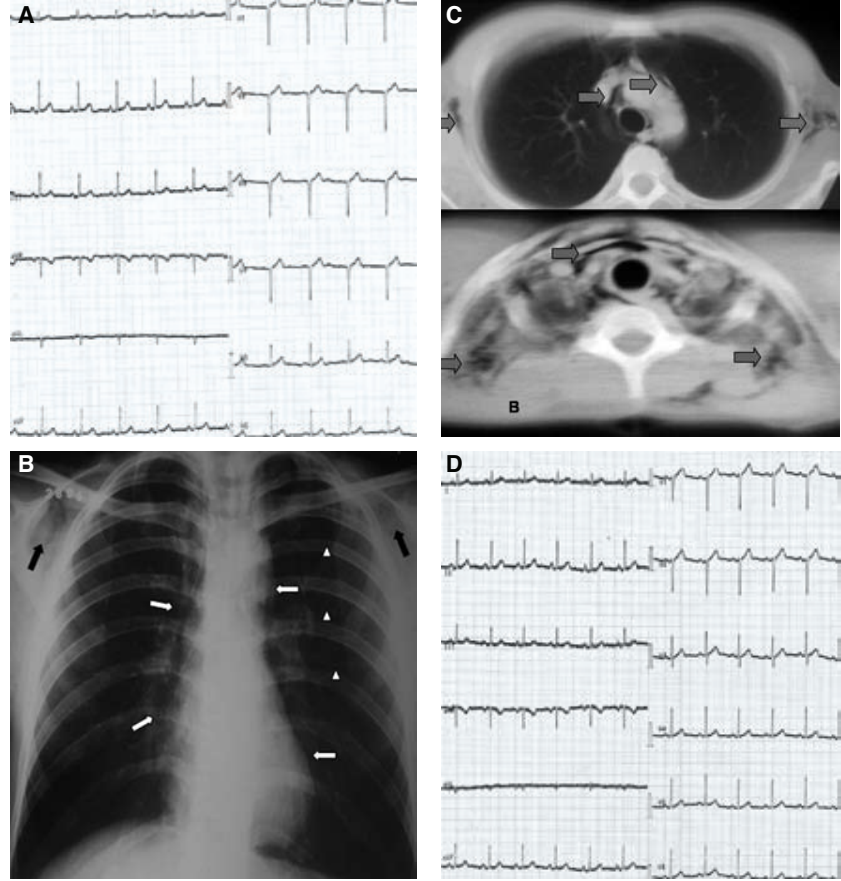
Murat Ünlü  
Akin Yıldızhan<sup>1</sup>  
Özcan Özeke  
Umuttan Doğan

Departments of  
Cardiology and  
<sup>1</sup>Thoracic Surgery,  
Diyarbakır Military  
Hospital,  
Diyarbakır

Poor/reversed R-wave progression in the precordial leads is a common ECG pattern, which is often misinterpreted as signs of an old infarction of the anterior wall.

A 24-year-old,

previously healthy man was referred to our emergency department with an initial diagnosis of acute coronary syndrome. He was admitted with vomiting and sudden onset of chest pain, which had began immediately after lunch, arising from the epigastrium and radiating to the neck and shoulders. His past and family history were free of any cardiovascular pathology. The initial examination did not show any specific finding. His baseline electrocardiogram showed normal sinus rhythm with Q waves in leads V1-4 (Fig. A). Cardiac markers and left ventricular wall motion on bedside echocardiographic examination were normal. After one hour, crepitus were noted in the anterior neck extending posteriorly on both sides to the trapezius muscles. Chest radiography showed pneumomediastinum, a radiolucent outline of the mediastinum with subcutaneous emphysema in the soft tissues of the neck and axillary region. The lungs were clear, no pleural effusion, pulmonary edema, or pneumothorax were noted (Fig. B). Contrast-enhanced computed tomography showed extensive pneumomediastinum with gas extending into the neck and between the



great vessels. There was a small linear gas collection extending to the outline of the mediastinum (Fig. C). Esophageal perforation was excluded with X-ray scopy on swallowing of radiopaque fluid. After the first week of hospitalization, the patient felt much better

## Spontan pnömomediastinumlu bir hastada yalancı miyokart enfarktüsü paterni

with no chest pain or shortness of breath, and a repeat ECG showed normal progression of the R wave in the precordial leads (Fig. D). The diagnosis was made as spontaneous pneumomediastinum. He was discharged and made a full recovery.

**Figures.** (A) Baseline electrocardiogram showing loss of R-wave progression and prominent S wave from V1 to V4. (B) Chest radiograph shows a radiolucent outline of the mediastinum (white arrows), subcutaneous emphysema in the soft tissues (black arrows), and a pleural line over the left lung (arrowheads). (C) Contrast-enhanced computed tomography showing pneumomediastinum, gas (gray arrows) extending into the neck and between the great vessels, and a linear gas collection extending to the outline of the mediastinum. (D) The electrocardiogram taken after a week shows normal R-wave progression.