

A case report of an acute reversible increase in pacing impedance of a ventricular epicardial lead after catheter ablation of ventricular tachycardia

Ventriküler takikardi ablasyonu sonrasında ventriküler epikardiyal lead'in akut geridönüşümlü impedans artışı

Emir Baskovski, M.D. , Başar Candemir, M.D. , Müge Akbulut, M.D. , Kerim Esenboğa, M.D. 

Department of Cardiology, Ankara University School of Medicine, Ankara, Turkey

Summary– Pacemakers are lifesaving devices that are being implanted with various indications, such as sinus node disease, atrioventricular block, and cardiac resynchronization therapy. Impedance measurement is one of the integral tests by which electrical resistance in pacing lead is tested. In this paper, we report an interesting observation of sudden impedance rise after ventricular tachycardia ablation with transmural lesions, which subsequently normalized without any need for intervention. The clinical implication of our findings is that careful observation might be indicated instead of lead replacement in case of a sudden surge in epicardial lead impedance after endocardial ablation owing that the impedance surge might be reversible.

Pacemakers are lifesaving devices that are being implanted with various indications, such as sinus node disease, atrioventricular (AV) block, and cardiac resynchronization therapy.^[1] The normal function of these devices, which consist of a generator and 1 or more intravascular/epicardial lead(s), is of utmost importance, especially in pacemaker-dependent patients. Malfunctions in the generator and/or lead(s) can be diagnosed with various diagnostic tests, for example, change in pacing thresholds, sensing threshold, and pacing impedance.^[2] Impedance is a measure of the electrical resistance in the lead. Detection of an acute change in lead impedance is an alarming event for clinicians and requires an analytical approach in diagnosis because it may point to a very significant problem requiring intervention (i.e., lead fracture).^[3]

In this report, we present a case of an extremely high, acute lead impedance surge in a ventricular epicardial pacing lead after ventricular tachycardia (VT)

Özet– Kalıcı kalp pilleri sinüs düğüm hastalığı, atriyoventriküler düğüm hastalığı ve kardiyak resenkronizasyon tedavisi gibi çeşitli endikasyonlarla implante edilmekteler. İmpedans ölçümü pil lead'lerin elektriksel rezistansını ölçen temel bir testir. Biz bu raporda transmural lezyonların oluşturulduğu bir ventriküler takikardi ablasyonu vakasında kendiiğinden gerileyen akut impedans artışını sunuyoruz. Ventrikül lead'lerin insersiyon bölgesi yakınlarında yapılan transmural lezyon hedefleyen ablasyonlardan sonra akut impedans artışları görülebilir, ancak, geridönüşümlü olması sebebiyle herhangi müdahaleden önce klinik takip yapılması önerilebilir.

ablation, which returned to normal level 24 hours after the procedure.

CASE REPORT

A woman aged 43 years was referred to our Electrophysiology division owing to recurrent hemodynamically significant VT episodes and near syncope. An informed consent was obtained from the patient. The patient had mitral valve surgery and tricuspid ring annuloplasty performed 5 years before this presentation. After the surgery, a third-degree AV block had developed, necessitating the implantation of a permanent pacemaker. At 4 years before this presentation, she had developed a device-related infection (pacemaker pocket infection and lead endocarditis) because of which the pacemaker and intravascular leads were explanted and epicardial right ventricular (RV) and left ventricular (LV) leads (Fig. 1) along with a biventricular (BIV) pacemaker generator on

Received: August 28, 2020 Accepted: November 18, 2020

Correspondence: Emir Baskovski, M.D. Department of Cardiology, Ankara University School of Medicine, Ankara, Turkey

Tel: +905343294409 e-mail: emirbaskovski@gmail.com

© 2021 Turkish Society of Cardiology



the right pectoral region were implanted in another center.

On echocardiography, a mildly dilated left ventricle, severe hypokinesia of anterior basal and middle LV wall, and an ejection fraction of 45% were observed, along with a normally functioning mechanic mitral valve and annuloplasty ring. There were no significant atherosclerotic lesions on coronary angiography. VT ablation was scheduled owing to recurrent hemodynamically significant VT episodes.

The patient underwent invasive VT induction in a sedated state. Before the procedure, the basal rhythm was atrial fibrillation with complete AV block with right ventricle-only VVI pacing at 50 bpm. The pacemaker was programmed into asynchronous mode at 40 bpm, and a ventricular quadripolar electrode was placed into the RV apex for backup/pacing. Using CARTO 3 electro-anatomical mapping system (Biosense Webster, Johnson & Johnson, Diamond Bar, CA, USA), voltage and activation mappings of VTs were performed retrogradely only using a long sheath because the trans-septal route could not be utilized owing to the presence of metallic mitral valve. Mapping revealed a broad, low-amplitude region between the subright coronary cusp (left coronary cusp junction) and the anterosuperior mitral annulus, which displayed local abnormal ventricular activities (LAVAs), and late, low amplitude and fragmented electrograms. This site was located at a region radioscopically just opposite to the insertion of epicardial RV leads. A total of 3 different monomorphic VTs with similar morphologies (all inferior axis), suggesting a common epicardial/intramurally located upper LV ostial origin, were induced. Of the 3 VTs induced, 2 were mapped and ablated at endocardial sites in close proximity to epicardial RV pacing lead, and the last one, being hemodynamically intolerable (tachycardia cycle length of 230 ms), had to be immediately cardioverted. Tolerable VTs recurred twice during the initial phases of the procedure. So, owing to presumed epicardial origin, ablation of all the LAVAs and late and fragmented potentials were performed with very high-power 60W/30ml/min irrigation at 1–2 minutes at each site of radiofrequency (RF) applications aiming complete transmural until the elimination of all signals (Fig. 2). Subsequently, no tachycardia could

be induced by programmed stimulation or rapid pacing.

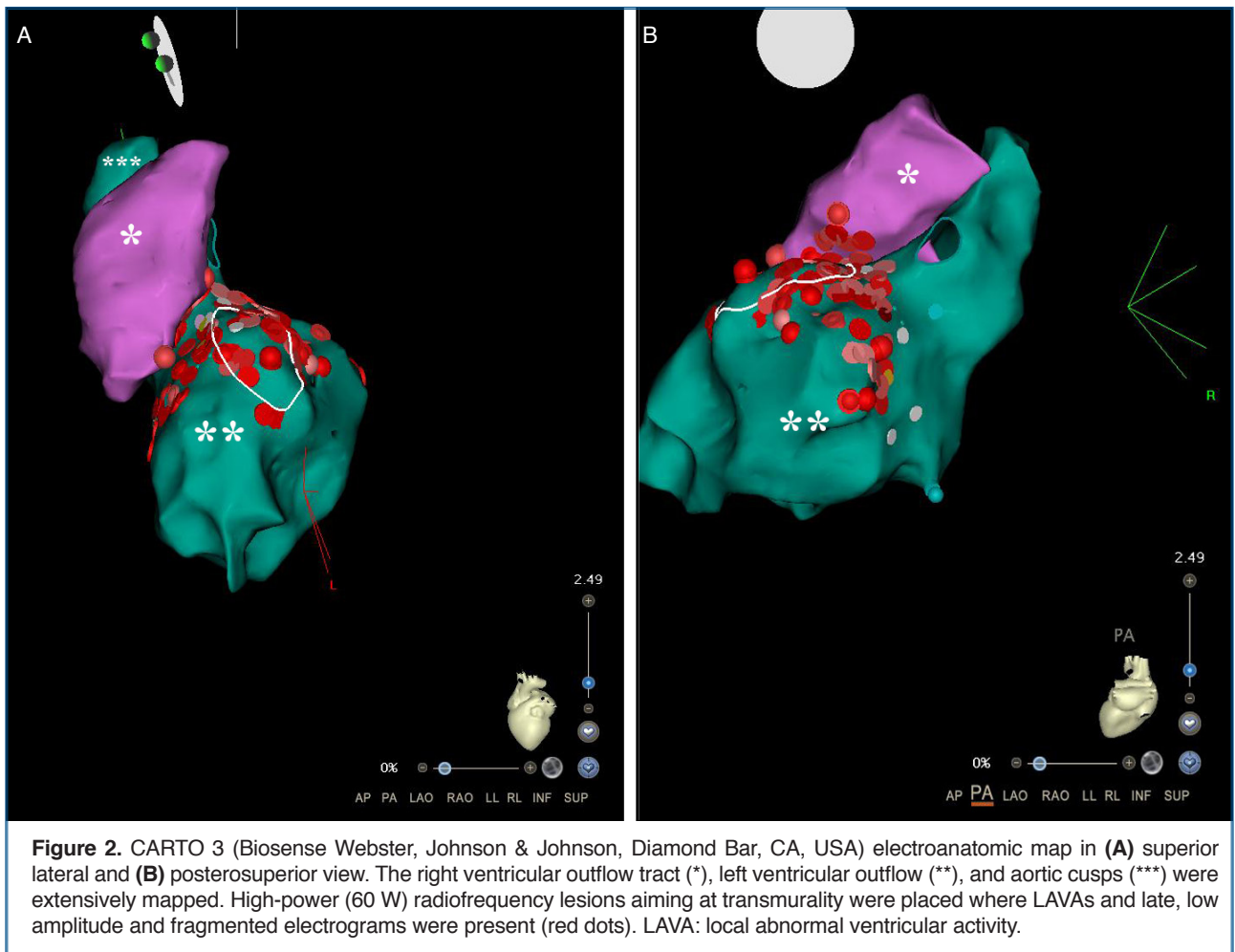
Immediately after the procedure, pacemaker interrogation revealed an acute rise in RV pacing lead impedance to $>3,000 \Omega$ (608Ω previously). LV pacing impedance was 513Ω , which was compatible with previous measurements, and both the LV and RV pacing thresholds were within normal limits (Fig. 3). Pacing mode was reprogrammed as BIV VVI 80 bpm, and interrogation was repeated 24 hours after the procedure, which showed a normalization of the RV lead impedance at 458Ω , consistent with the values obtained during preprocedure measurements. We recommended a BIV intracardiac cardioverter/defibrillator upgrade with an RV defibrillator lead to the patient; however, owing to the fear of another device-related infection, she declined. The patient was followed-up for 6 days and then discharged. On the follow-up visit at 3 weeks later, there was no VT recorded on the pacemaker memory, pacing parameters and impedance levels were completely normal, and she was asymptomatic.

Abbreviations:

AV	Atrioventricular
BIV	Biventricular
LAVA	Local abnormal ventricular activity
LV	Left ventricular
MLI	Myocardial-lead interface
RF	Radiofrequency
RV	Right ventricular
VT	Ventricular tachycardia

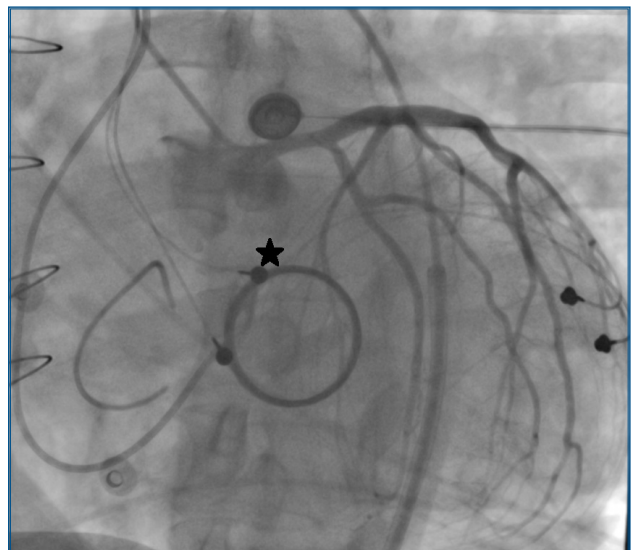

Figure 1. Fluoroscopic LAO 28° image obtained during the procedure depicting epicardial right and left ventricular pacing leads and a mechanical mitral valve. Also depicted is left coronary angiography. The approximate site of ablation is tagged by an asterisk (*). LAO: Left anterior oblique.



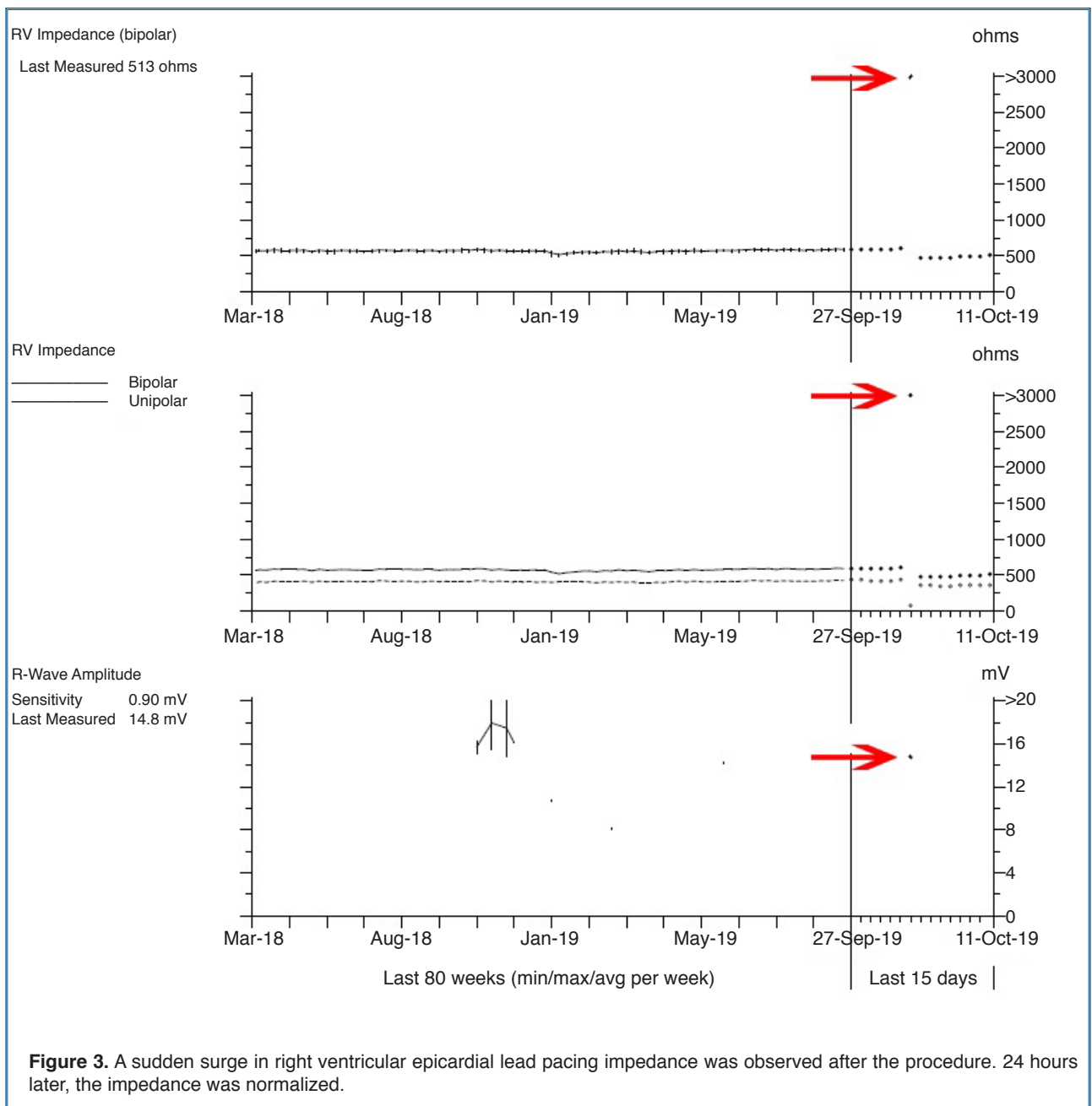
DISCUSSION

Pacing impedance remains one of the most important diagnostic tools in pacemaker troubleshooting; therefore, performing these basic tests before and after ablation procedures is of utmost importance. The etiology of pacing impedance change can be systematically classified into a change due to connector error, lead malfunction, and myocardial-lead interface (MLI) issues.^[4] An acute rise in impedance is usually due to lead fracture or connector pin malfunction, whereas an acute decrease in impedance is caused by insulation breach.^[4] A slow rise in pacing impedance has been reported to occur owing to the maturation of MLI.^[5]

When considering endocardial RF catheter ablation, the mechanism of pacemaker malfunction can be classified as pulse generator disturbance (owing to electromagnetic interference during the procedure), lead dislodgement, lead insulation damage, and fi-

nally disturbance in MLI if ablation is performed in proximity.^[6] In our case, electromagnetic interference was not the issue, nor was lead dislodgement or insulation damage, which were obviously not possible owing to the fact that the leads were epicardial.

MLI disturbance during catheter ablation procedure has been described in an experimental study by Chin et al.^[7] performed in vivo on 12 dogs. It was observed that when RF ablation was performed <1 cm from the lead tip, false inhibition of pacing and pacemaker runaway occurred. When ablation was performed >4 cm from the lead tip, no malfunction was observed. Importantly, in neither group did pacing threshold, sensing, or impedance change after the procedure, bearing in mind that applied RF energy was limited to 15 W and for a maximum of 30 seconds. Although leads were endocardial and therefore direct injury to the insertion region is more likely, the applied energy was much lower



when compared with that used in our case where the desired lesion depth was required to be high. Critical lesion depth and acute tissue injury could have been reached because very high-power, long-duration irrigated RF ablation (60 W at 30 mL/min) was utilized in our case.

The histopathology of lesions caused by RF energy was elegantly described by Barkagan et al.^[8] Thermal damage in the microvasculature surrounding necrotic core is characterized by interstitial edema.

In a study where magnetic resonance imaging was used to characterize tissue injury, a temporal decline in delayed enhancement was observed.^[9] This phenomenon, which represents reversible tissue injury, was more pronounced in patients with recurrent atrial fibrillation. In our opinion, acute interstitial edema and reversible tissue injury might be responsible for the acute increase in impedance, whereas resolving of edema may explain the normalization of impedance on the subsequent measurement. In vitro or in vivo systematic studies are necessary to definitely

characterize the safety zone for catheter ablation in patients with epicardial leads.

Conclusion

We recommend routine device interrogation and diagnostics both before the procedure and after the ablation procedure. Catheter RF ablation of myocardial regions that are in anatomical proximity to epicardial pacemaker leads can lead to a reversible increase in lead impedance. Although this was not associated with (transient or permanent) lead dysfunction in our case, the operator should not exclude this possibility, especially when high-power RF ablation with the goal of transmural lesion-forming is targeted. Finally, careful observation might be indicated instead of lead replacement in case of a sudden surge in epicardial lead impedance after endocardial ablation owing that the impedance surge might be reversible.

Informed Consent: Informed consent was obtained from the patient for the publication of the case report and the accompanying images.

Peer-review: Externally peer-reviewed.

Authorship contributions: Concept - E.B., B.C.; Supervision - B.C.; Data - M.A., K.E.; Literature search - K.E.; Writing - E.B., M.A.; Critical revision - B.C.

Conflict-of-interest: None.

REFERENCES

1. Kusumoto FM, Schoenfeld MH, Barrett C, Edgerton JR, Ellenbogen KA, Gold MR, et al. 2018 ACC/AHA/HRS Guideline on the evaluation and management of patients with bradycardia and cardiac conduction delay: a report of the American College of Cardiology/American Heart Association Task Force on clinical practice guidelines and the Heart Rhythm Society. *J Am Coll Cardiol* 2019;74:e51-156. [\[Crossref\]](#)
2. Mulpuru SK, Madhavan M, McLeod CJ, Cha Y-M, Friedman PA. Cardiac pacemakers: function, troubleshooting, and management. *J Am Coll Cardiol* 2017;69:189-210. [\[Crossref\]](#)
3. Mourad AR, Kim MH, Kirk MM. A case series of anomalous high pacing lead impedances in normally functioning leads. *HeartRhythm Case Rep* 2015;1:449-52. [\[Crossref\]](#)
4. Calvin JW. Intraoperative pacemaker electrical testing. *Ann Thorac Surg* 1978;26:165-76. [\[Crossref\]](#)
5. Swerdlow CD, Sachanandani H, Gunderson BD, Ousdigian KT, Hjelle M, Ellenbogen KA. Preventing overdiagnosis of implantable cardioverter-defibrillator lead fractures using device diagnostics. *J Am Coll Cardiol* 2011;57:2330-9. [\[Crossref\]](#)
6. Darrat Y, Morales G, Elayi C. The effects of catheter ablation on permanent pacemakers and implantable cardiac defibrillators. *J Innov Card Rhythm Manag* 2017;8:2630-5. [\[Crossref\]](#)
7. Chin MC, Rosenqvist M, Lee MA, Griffin JC, Langberg JJ. The effect of radiofrequency catheter ablation on permanent pacemakers: an experimental study. *Pacing Clin Electrophysiol* 1990;13:23-9. [\[Crossref\]](#)
8. Barkagan M, Leshem E, Shapira-Daniels A, Sroubek J, Buxton AE, Saffitz JE, et al. Histopathological characterization of radiofrequency ablation in ventricular scar tissue. *JACC Clin Electrophysiol* 2019;5:920-31. [\[Crossref\]](#)
9. Arujuna A, Karim R, Caulfield D, Knowles B, Rhode K, Schaeffter T, et al. Acute pulmonary vein isolation is achieved by a combination of reversible and irreversible atrial injury after catheter ablation: evidence from magnetic resonance imaging. *Circ Arrhythm Electrophysiol* 2012;5:691-700. [\[Crossref\]](#)

Keywords: Impedance; ventricular tachycardia; catheter ablation; artificial cardiac pacemaker

Anahtar Kelimeler: Empedans, ventriküler takikardi, kateter ablasyon, kalıcı kalp pili