

A totally extruded pacemaker

Tamamen vücut dışına çıkmış kalp pili

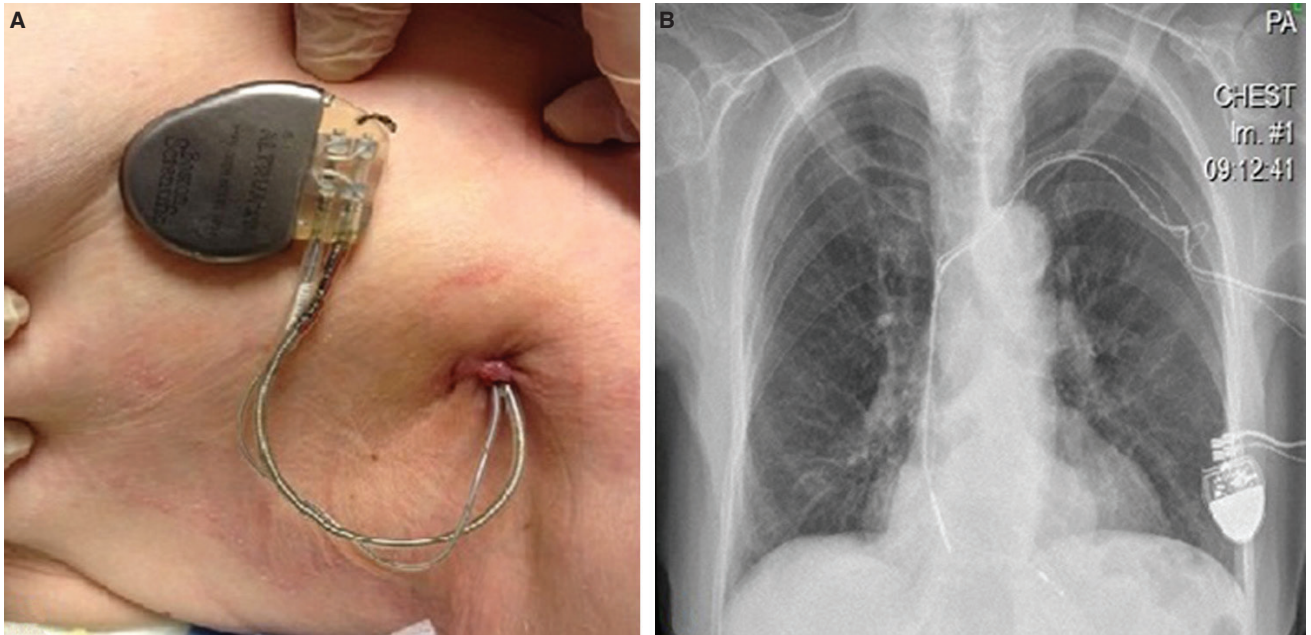
Mehmet Onur Omaygenç
İbrahim Oğuz Karaca
Beytullah Çakal
Fethi Kılıçaslan

Department of Cardiology,
Istanbul Medipol University
Hospital, Istanbul

Total extrusion of a pacemaker generator is an extremely rare and potentially fatal complication of pacemaker implantation. An 82-year-old female patient was brought to our out-patient clinic by relatives who had noticed that the device was outside of

her body. The pulse generator and proximal portions of both leads had been expelled from the anterior axillary region. There was no sign of active purulent inflammation, and granulomatous tissue surrounded the exit site (Fig. A). Examination of the device revealed

acceptable sensing, pacing and impedance measurements in VVI mode. A chest x-ray demonstrated the dislocated atrial and right ventricular leads (Fig. B). Acute phase reactants were within normal limits. After initiation of a prophylactic antibiotic regimen, immediate explantation of the system was planned. Following the explantation procedure, the patient was paced with a temporary pacemaker for four days, until the entire set of cultures, including lead tips, had produced negative results. A DDD-R pacemaker was then implanted in the contralateral side. What was exceptional about this case was the persistence of pacing function and absence of bacterial colonization on the device. Management was achieved by following the widely acknowledged strategy.



Figures– (A) Extrusion of the system from the anterior axillary region. Please note the granulomatous tissue surrounding the exit site. **(B)** Chest X-ray displaying the position of leads in the cardiac chambers.