

How to?

Nasıl Yapalım?

How to manage aspirin hypersensitivity in a patient with ST-segment elevation myocardial infarction and a drug-eluting stent

ST-segment elevasyonlu miyokart enfarktüsü sonrası ilaç salınımlı stent takılan hastada aspirin hipersensitivitesini nasıl yönetelim?

Ezgi Çamlı, M.D.¹ , Hedi Verdiyev, M.D.¹ , Erdi Babayiğit, M.D.² , Emel Kurt, M.D.³ , Taner Ulus, M.D.¹ 

¹Department of Cardiology, Eskişehir Osmangazi University School of Medicine, Eskişehir, Turkey

²Department of Cardiology, Kulu State Hospital, Konya, Turkey

³Division of Immunology and Allergy, Department of Chest Diseases, Eskişehir Osmangazi University School of Medicine, Eskişehir, Turkey

A 65-year-old-man was admitted for primary percutaneous coronary intervention (PCI) because of an anterior ST-segment elevation myocardial infarction (STEMI), and a 3.0 x 16 mm everolimus-eluting stent was implanted in the left anterior descending artery. The patient was discharged without any adverse event on the 5th day of hospitalization with dual antiplatelet therapy consisting of 81 mg of aspirin and 10 mg of prasugrel once daily. On the day of discharge, the patient noticed widespread urticarial rashes on his body and face, and he ceased acetylsalicylic acid (ASA, aspirin) therapy (Fig. 1). The patient stated that he noticed the lesions on his skin 2 hours after the last aspirin dose on the day of discharge, and the lesions spontaneously disappeared the next day after stopping aspirin. When he presented to our outpatient clinic 2 days after discharge, he was only taking prasugrel as an antiplatelet agent. The patient stated that he had used aspirin 4 years ago and discontinued it when his urticarial lesions developed. Therefore, the question arises how to manage this and enable the patient to continue receiving dual antiplatelet therapy.

Aspirin desensitization protocols

Dual antiplatelet therapy, including ASA and a P2Y12 inhibitor, is recommended in patients with STEMI who

are undergoing primary PCI for up to 12 months.^[1] However, about 2% of patients with cardiovascular disease are unable to receive ASA therapy owing to true hypersensitivity reactions.^[2] From a mild cough or itching to worsening of asthma, angioedema, or anaphylaxis, ASA hypersensitivity can occur with various respiratory or cutaneous reactions.^[3] Discontinuation of aspirin because of hypersensitivity may increase the risk of recurrent coronary events in patients with high-risk cardiovascular disease who need dual antiplatelet therapy. Aspirin desensitization could be a solution in such patients. However, there is no standard desensitization protocol for aspirin hypersensitivity, and the previously described protocols have many difficulties in daily practice.^[2-4]

In patients with ACS and aspirin hypersensitivity, a cardiologist should immediately decide on aspirin desensitization or antithrombotic treatment options that do not contain aspirin. Treatment options other than aspirin include the use of clopidogrel alone (normal or double dose), prasugrel alone, or ticagrelor alone.^[5] However, the safety of such single antithrombotic therapies has not been demonstrated, especially in patients with ACS, and they may be associated with stent thrombosis or recurrent ischemic

Geliş tarihi: July 14, 2020 Kabul tarihi: October 16, 2020

Yazışma adresi: Taner Ulus, M.D. Department of Cardiology, Eskişehir Osmangazi University School of Medicine, Eskişehir, Turkey

Tel: +90 222 239 29 79 e-posta: tanerulusbuca@gmail.com

© 2021 Turkish Society of Cardiology



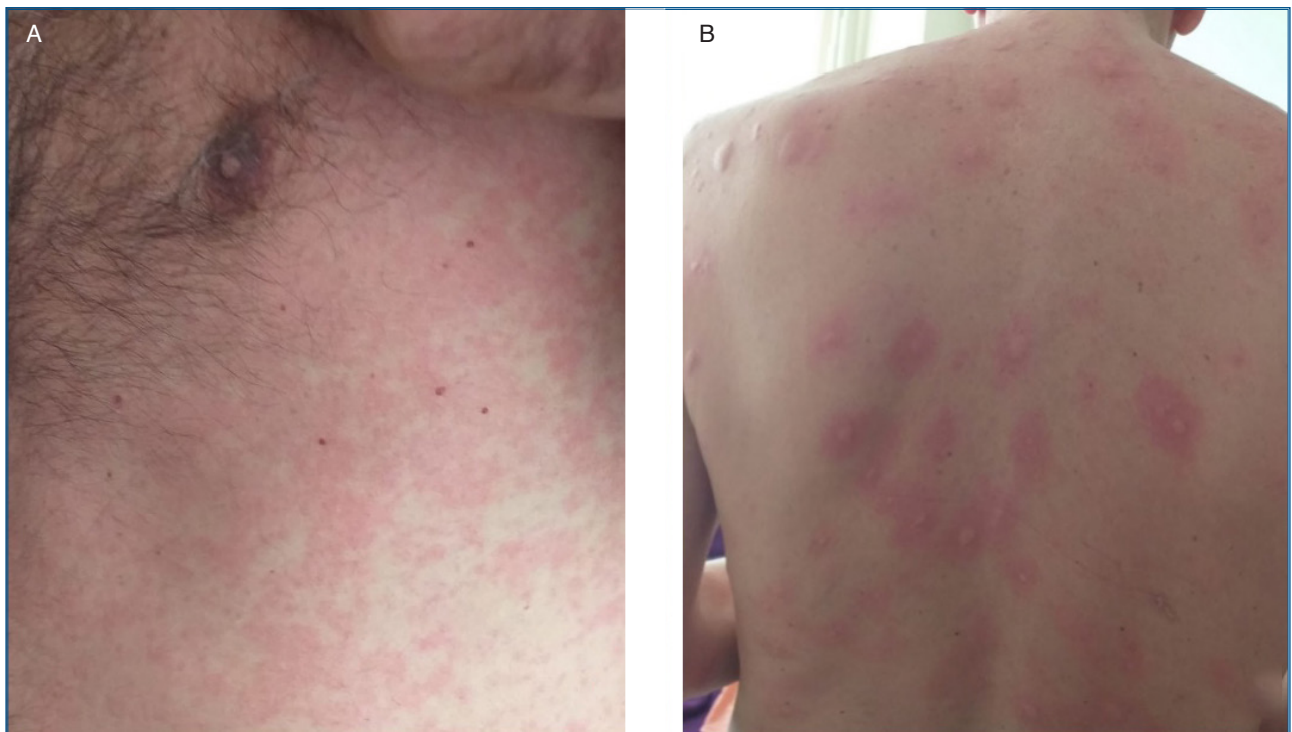


Figure 1. (A) Urticarial rash on the patient's front and **(B)** back of the trunk. A written consent was obtained from the patient.

events in this patient group.^[5,6] Another option is the combined use of indobufen (100 mg/twice a day) and clopidogrel (75 mg a day). A small study has shown that this combination is better in inhibiting platelet aggregation than clopidogrel monotherapy.^[6]

We decided to administer aspirin desensitization on the same day the patient was hospitalized. What are the previously described desensitization protocols in patients with cardiovascular disease?

1) In the aspirin desensitization in patients with coronary artery disease (ADAPTED) registry, Rossini et al.^[2] have described a desensitization method consisting 6 sequential doses of aspirin (1, 5, 10, 20, 40, and 100 mg) administered orally for 5.5 hours. This protocol was described in patients with known/suspected stable coronary artery disease or acute coronary syndrome.

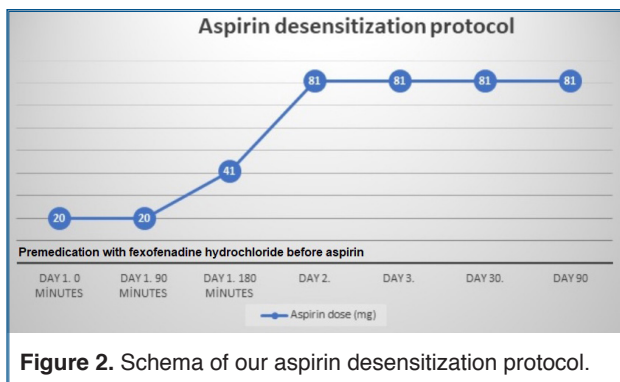
2) Jackson et al.^[4] have described a very rapid desensitization protocol that was completed in a 2-hour period (5 mg at the beginning, 10 mg at 30 minutes, 20 mg at 60 minutes, 40 mg at 90 minutes, and 75 mg at 120 minutes). The protocol was administered to patients who underwent coronary angiography with the intention of PCI. However, this protocol includes a retrospective single center experience and may be

more suitable for patients with mild allergic reactions, such as urticaria. This protocol could be risky in patients with severe allergic reactions.

3) White et al.^[7] proposed a desensitization scheme consisting 2 doses of 40.5 mg aspirin at 90 min intervals. If a patient reacts to these doses, an additional 40.5 mg of aspirin is recommended, and if not, starting with 81 mg of aspirin per day from the next day is recommended in this scheme.

Our protocol

We applied a practical desensitization method with an allergy specialist, containing 3 consecutive aspirin doses of 20 mg, 20 mg, and 41 mg, and reached a total dose of 81 mg aspirin in 3 hours (Fig. 2). Strict medical observation was performed during and after the protocol. Before ASA challenge, the patient was given 120 mg of fexofenadine hydrochloride orally. In the following days, dual antiplatelet therapy, consisting 81 mg aspirin and 10 mg prasugrel daily was given. On the morning of the second day of desensitization therapy, the patient was given 81 mg of aspirin, and the patient was discharged 6 hours after taking the dose of 81 mg aspirin. He had no hypersensitivity reaction or cardiovascular event at the 3-month fol-



low-up and was using the dual antiplatelet therapy. Oral antihistamine was given for one month after desensitization and then discontinued.

Advantages of our aspirin desensitization protocol

Our protocol was not rapid, and there was enough time to observe allergic reactions between the aspirin doses. The interval between doses was 30 minutes in the method described by Jackson et al.,^[4] it was 90 minutes in our protocol. A very rapid protocol can increase the risk of hypersensitivity and may not allow close monitoring of possible systemic allergic reactions between doses. However, our protocol was completed in 3 hours, and there was no delay in restarting the dual antiplatelet therapy. This time period was 5.5 hours in the protocol of Rossini et al.^[2] Our protocol is similar to the protocol of White et al.,^[7] in which 2 doses of 40.5 mg aspirin were administered at 90-minute intervals.

Our protocol comprised aspirin doses that were easy to administer in clinical practice. The initial and maintenance doses were 1 and 5 mg, respectively, in the protocol of Rossini et al.^[2] and 5 and 10 mg, respectively, in the protocol of Jackson et al.^[4] It may not be very practical to implement a protocol with such low ASA doses in the clinic.

Our protocol comprised a 3-dose escalation. Rossini et al.^[2] described 6-dose and Jackson et al.^[4] 5-dose escalation protocols. The multiple consecutive doses of aspirin can make it difficult to administer.

Before desensitization, the patient was given a long-acting antihistamine. Although routine pretreatment was not performed in some protocols,^[2,4] in others, antihistamine or corticosteroid were administered before the aspirin doses.^[8] In some studies, pretreatment was applied only in patients with aspi-

rin-exacerbated respiratory disease.^[7,9] In the protocol proposed by White et al.,^[7] premedication with antihistamines and oral montelukast is recommended if patient has a history consistent with aspirin-exacerbated respiratory disease. Otherwise, premedication is not recommended.

Timing of desensitization

Aspirin should be started immediately in patients with STEMI.^[1] Studies have shown that early ASA desensitization is safe in patients with STEMI. Rossini et al.^[2] performed aspirin desensitization after primary PCI in patients with STEMI and with aspirin hypersensitivity and did not report any adverse events. Córdoba-Soriano et al.^[10] performed ASA desensitization within 12 hours after primary PCI in patients with STEMI, and they reported that it was safe in such patients.

Conclusion

ASA hypersensitivity can be a major problem, especially in patients with ACS and have a drug-eluting stent. The patients should also be questioned about aspirin hypersensitivity before dual antiplatelet therapy is initiated as they may not express this themselves, especially in emergencies such as STEMI. Our aspirin desensitization protocol is practical and reliable. This case report demonstrated that many patients with ACS and ASA hypersensitivity can continue to use ASA after desensitization therapy. However, it is unclear whether this protocol will be reliable in all patients with aspirin hypersensitivity. Therefore, this protocol needs to be tested with further studies in patients with cardiovascular disease. This is a risky procedure and should only be performed if there is no other safer alternative and only in experienced centers.

Peer-review: Externally peer-reviewed.

Authorship contributions: Concept - E.Ç., T.U.; Design - E.Ç., H.V., T.U.; Supervision - E.Ç., T.U.; Materials - E.Ç., H.V.; Data - E.Ç., H.V.; Analysis - E.Ç., T.U.; Literature search - E.Ç., E.B., T.U.; Writing - E.Ç., H.V., T.U.; Critical revision - E.B., E.K. T.U.

Conflict-of-interest: None.

REFERENCES

- Ibanez B, James S, Agewall S, Antunes MJ, Bucciarelli-Ducci C, Bueno H, et al. 2017 ESC Guidelines for the management of acute myocardial infarction in patients presenting with

- ST-segment elevation: The Task Force for the management of acute myocardial infarction in patients presenting with ST-segment elevation of the European Society of Cardiology (ESC). *Eur Heart J* 2018;39:119-77. [\[Crossref\]](#)
- Rossini R, Iorio A, Pozzi R, Bianco M, Musumeci G, Leonardi S, et al. Aspirin desensitization in patients with coronary artery disease: results of the multicenter ADAPTED Registry (aspirin desensitization in patients with coronary artery disease). *Circ Cardiovasc Interv* 2017;10:e004368. [\[Crossref\]](#)
 - Chopra AM, Díez-Villanueva P, Córdoba-Soriano JG, Lee JKT, Al-Ahmad M, Ferrais VA, et al. Meta-analysis of acetylsalicylic acid desensitization in patients with acute coronary syndrome. *Am J Cardiol* 2019;124:14-9. [\[Crossref\]](#)
 - Jackson M, Callaghan S, Stapleton J, Bolton S, Austin D, Muir DF, et al. Rapid aspirin desensitization is safe and feasible in patients with stable and unstable coronary artery disease: a single-center experience. *J Cardiovasc Pharmacol Ther* 2019;24:359-64. [\[Crossref\]](#)
 - Bianco M, Bernardi A, D'Ascenzo F, Cerrato E, Omedè P, Montefusco A, et al. Efficacy and safety of available protocols for aspirin hypersensitivity for patients undergoing percutaneous coronary intervention: a survey and systematic review. *Circ Cardiovasc Interv* 2016;9:e002896. [\[Crossref\]](#)
 - Barillà F, Pulcinelli FM, Mangieri E, Torromeo C, Tanzilli G, Dominici T, et al. Clopidogrel plus indobufenin acute coronary syndrome patients with hypersensitivity to aspirin undergoing percutaneous coronary intervention. *Platelets* 2013;24:183-8. [\[Crossref\]](#)
 - White AA, Stevenson DD, Woessner KM, Simon RA. Approach to patients with aspirin hypersensitivity and acute cardiovascular emergencies. *Allergy Asthma Proc* 2013;34:138-42. [\[Crossref\]](#)
 - Waldrum J, Walters K, Simon R, Woessner K, Waalen J, White A. Safety and outcomes of aspirin desensitization for aspirin-exacerbated respiratory disease: a single-center study. *J Allergy Clin Immunol* 2018;141:250-6. [\[Crossref\]](#)
 - Woessner KM. Aspirin desensitization for cardiovascular disease. *Curr Opin Allergy Clin Immunol* 2015;15:314-22. [\[Crossref\]](#)
 - Córdoba-Soriano JG, Corbí-Pascual M, López-Neyra I, Navarro-Cuartero J, Hidalgo-Olivares V, Barrionuevo-Sánchez MI, et al. Early aspirin desensitization in unstable patients with acute coronary syndrome: short and long-term efficacy and safety. *Eur Heart J Acute Cardiovasc Care* 2016;5:41-50. [\[Crossref\]](#)