

## Unexpected cause of lead fracture: A stylet left inside the right ventricular pacemaker lead

*Elektrod kırığının beklenmedik bir nedeni: Sağ ventrikül elektrodu içinde bırakılan stile*

Ahmet Hakan Ateş

Uğur Arslan

Huriye Yücel

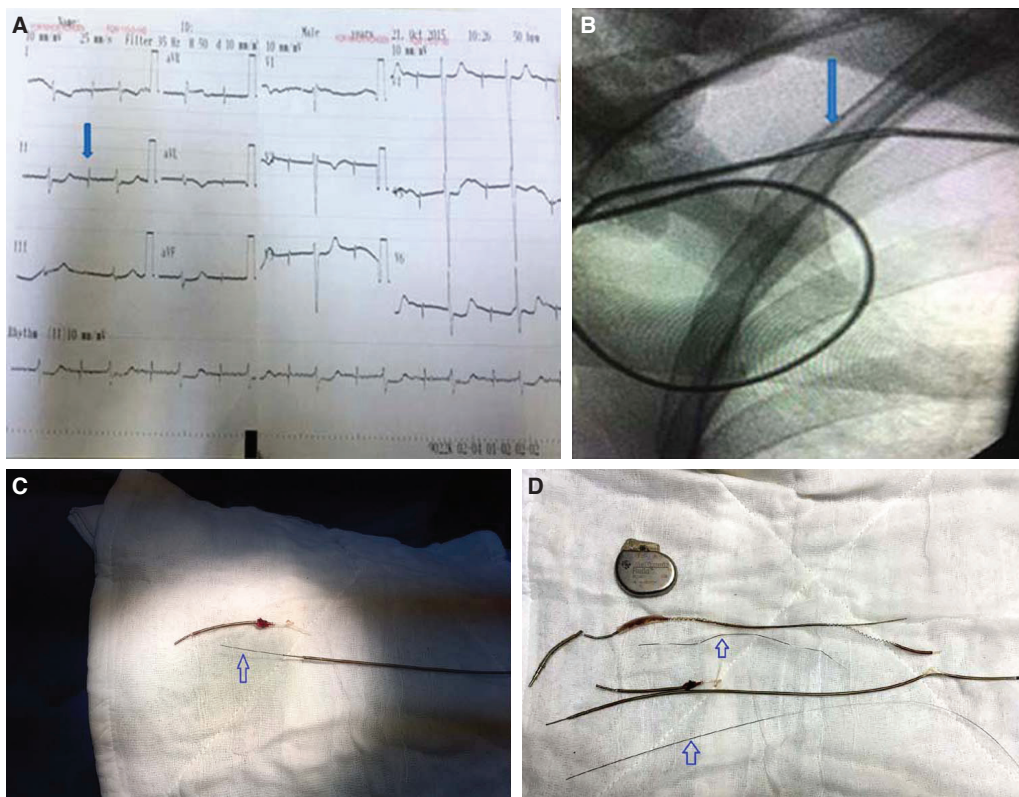
İlksen Atasoy Günaydın

Mustafa Yenerçağ

Department of Cardiology,  
Health Sciences University  
Samsun Training and Research  
Hospital, Samsun, Turkey

A 55-year-old female patient with earlier diagnosis of cardiac cirrhosis and mitral valve implantation was admitted with complaints of weakness and dizziness. She had undergone VVIR pacemaker implantation 9 years earlier due to low ventricular rate atrial fibrillation and had generator replacement procedure 3 months previously. Electrocardiogram indicated pacemaker dysfunction due to failure to capture (Figure A). Evaluation of pacemaker revealed high impedance and threshold data after implantation. Chest X-ray and fluoroscopic image showed lead fracture (Figure B). Large right heart chambers

with left ventricular ejection fraction of 32% were detected in transthoracic echocardiography. Following these evaluations, extraction of fractured lead and pacemaker and implantation of VVIR implantable cardioverter-defibrillator (ICD) was planned. Transvenous lead extraction system (Spectranetics Inc., Colorado Springs, CO, USA) was used for procedure. Pacemaker generator and lead were carefully dissected and completely freed from scar tissue, and pacemaker generator was removed from lead and pacemaker pocket. During the extraction procedure, we cut the proximal part of the lead and attempted but were unable to advance locking stylet through the lead. We discovered that inner lumen of electrode contained unexpected stylet previously left behind (Figure C). Passive manual traction was applied and the lead was extracted successfully. Stylet left inside the electrode was removed (Figure D). In the same session, VVIR-ICD was implanted from the same side.



**Figures– (A)** Electrocardiogram showing pacemaker dysfunction due to loss of capture. **(B)** Fluoroscopic image of lead fracture. Stylet left inside the electrode (arrows). **(C)** Stylet from inside the electrode after manual traction. **(D)** Two pieces of the stylet removed from the electrode.