

Volume measurement of a cardiac myxomatous lesion with three-dimensional echocardiography

Üçboyutlu ekokardiyografi ile kardiyak miksomatöz bir lezyonun hacminin ölçümü

Sait Demirkol

Zekeriya Arslan[#]

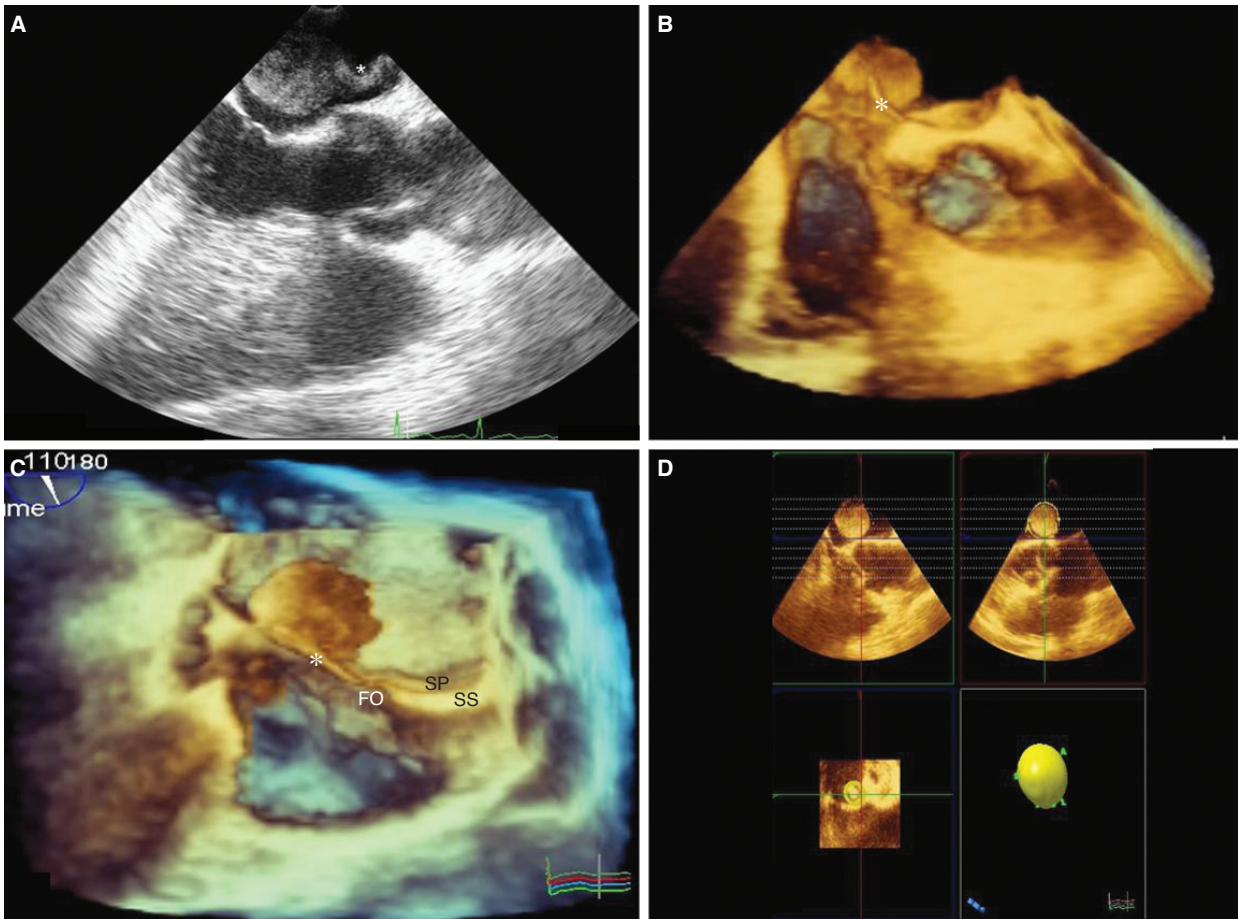
Şevket Balta

Uğur Küçük

Department of Cardiology,
GATA Medical Faculty, Ankara;

[#]Department of Cardiology,
Gelibolu Military Hospital,
Çanakkale, Turkey

A 48-year-old man was referred to our outpatient clinic with complaints of shortness of breath and palpitation. On physical examination, he had tachycardia and his blood pressure was 110/70 mmHg. Electrocardiography showed sinus tachycardia, and his blood biochemistry was normal. Two-dimensional echocardiography detected a mass in the left atrium that was suggestive of a myxomatous lesion. Two and three-dimensional transesophageal echocardiography revealed a mass with a stalk (Fig. A, B) attached to the junction point of the septum primum (SP) and the septum secundum (SS) around the foramen ovale (FO) (Fig. C, Video). The volume of the mass lesion was measured as 10.6 ml using three-dimensional quantification advanced modality (Philips IE 33 QLAB software) (Fig. D). The mass was surgically removed and histopathological examination of the specimen confirmed the diagnosis of myxoma. The post-surgical tumor volume was calculated as 11.4 ml. Three-dimensional transesophageal echocardiography may be useful in revealing the volume, shape, and the site of attachment of cardiac tumors in detail.



Figures– (A) Two-dimensional and (B) three-dimensional transesophageal echocardiography revealed a mass with a stalk. (C) This stalk attached to the junction point of the septum primum and the septum secundum around the foramen ovale. (D) The volume measurement of the mass using three-dimensional quantification advanced modality. *Supplementary video file associated with this case can be found in the online version of the journal.